



ELSEVIER

Contents lists available at ScienceDirect

## The Ocular Surface

journal homepage: [www.elsevier.com/locate/jtos](http://www.elsevier.com/locate/jtos)

## Review Article

## Intense pulsed light treatment in meibomian gland dysfunction: A concise review

Behzod Tashbayev<sup>a,b,\*</sup>, Mazyar Yazdani<sup>b,c</sup>, Reiko Arita<sup>d</sup>, Fredrik Fineide<sup>b,c</sup>,  
Tor Paaske Utheim<sup>b,c,e,f,g,h</sup><sup>a</sup> Department of Oral Surgery and Oral Medicine, University of Oslo, Oslo, Norway<sup>b</sup> The Norwegian Dry Eye Clinic, Oslo, Norway<sup>c</sup> Department of Medical Biochemistry, Oslo University Hospital, Oslo, Norway<sup>d</sup> Department of Ophthalmology, Itoh Clinic, Saitama-City, Saitama, Japan<sup>e</sup> Department of Ophthalmology, Oslo University Hospital, Oslo, Norway<sup>f</sup> Department of Ophthalmology, Sørlandet Hospital Arendal, Arendal, Norway<sup>g</sup> Department of Ophthalmology, Stavanger University Hospital, Stavanger, Norway<sup>h</sup> Department of Computer Science, Oslo Metropolitan University, Oslo, Norway

## ARTICLE INFO

## Keywords:

Meibomian gland dysfunction  
Intense pulsed light  
Treatment  
Manual expression  
Dry eye disease

## ABSTRACT

**Purpose:** To review the published literature related to application of intense pulsed light (IPL) for treating meibomian gland dysfunction (MGD).**Methods:** The literature search included the PubMed database and used the keywords “Intense Pulsed Light and Meibomian Gland Dysfunction”.**Results:** IPL is a new instrumental treatment modality for MGD. This treatment modality was originally developed for use in dermatology and was later adopted in ophthalmology for treating MGD. IPL therapy for MGD can improve tear film stability, meibomian gland functionality, as well as subjective feeling of ocular dryness. However, in the reviewed literature, there was great variability in patient selection, evaluation criteria, and treatment protocols and durations.**Conclusion:** Numerous studies report that IPL is effective for treating MGD and a safe procedure. There is great potential for further improvements to the procedure, as large comparative studies employing different treatment modalities are lacking.

## 1. Introduction

Dry eye disease (DED), also known as dry eye syndrome, dysfunctional tear syndrome, and keratoconjunctivitis sicca, is one of the most common ocular conditions prompting patients to seek eye care. It is prevalent in 5–50% of the population, depending on the diagnostic criteria and regions of the world; this multifactorial disease can occur at any age, but the elderly and women are more susceptible. The symptoms can vary, but in general manifest as ocular fatigue, dryness, discomfort, foreign body sensation, stinging, and blurred vision that interfere with daily function and quality of life. Therefore, DED imposes a substantial economic burden on patients and society owing to the considerable loss of work productivity and the use of medical resources [1–3].

Meibomian gland dysfunction (MGD) is considered to be the major cause of DED [4–6]. This chronic and diffuse abnormality is generally

characterized by terminal duct obstruction and/or qualitative/quantitative changes in the glandular secretions [7]. The traditional treatment options for MGD, such as warm compresses, enhanced eyelid hygiene by removing blocked meibum, anti-inflammatory agents, antibiotics, and supplements with omega-3 fatty acids, do not achieve long-term satisfactory results. Therefore, the exploration of new potential therapeutic interventions has become a necessity [8–11].

Intense pulsed light (IPL), originally developed for use in dermatology, was introduced for treating MGD in 2015 [12]. Since then, attempts have been made to refine this new approach. The IPL device, also referred to as flashlamp therapy, is a light-emitting system that irradiates filtered polychromatic broad-bandwidth wavelengths with varying pulse durations for selective thermal damage of the target [13]. Several studies have reported the safe application of this procedure without any adverse effects, provided proper eye protection is employed [14–19]. Although the exact mechanisms underlying its

\* Corresponding author. Department of Oral Surgery and Oral Medicine, University of Oslo, Oslo, Norway.

E-mail address: [behzod.tashbayev@odont.uio.no](mailto:behzod.tashbayev@odont.uio.no) (B. Tashbayev).<https://doi.org/10.1016/j.jtos.2020.06.002>

Received 20 January 2020; Received in revised form 18 May 2020; Accepted 4 June 2020

Available online 03 July 2020

1542-0124/ © 2020 The Authors. Published by Elsevier Inc. This is an open access article under the CC BY license

<http://creativecommons.org/licenses/by/4.0/>.

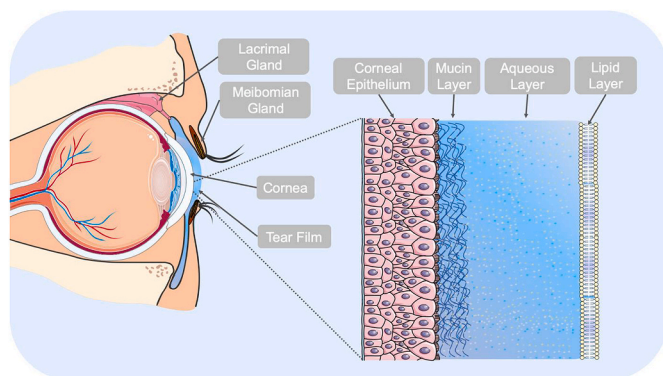


Fig. 1. The three-layered structure of the tear film.

beneficial effects are complex and still not well understood, it has been suggested that it reduces telangiectasia, eradicates *Demodex* mites, results in thermal softening and liquefaction of meibum, modulates the secretion of pro- and anti-inflammatory molecules, and suppresses matrix metalloproteinases [11,20–24].

This paper aims to review the status of IPL application in the treatment of MGD. The main question addressed is whether IPL as a stand-alone instrumental treatment or—concomitant with manual expression of the meibomian glands—can improve any of the ocular surface parameters.

## 2. Dry eye disease

DED can be caused by qualitative or quantitative alteration in the tear film. The tear film is structurally composed of three layers: (a) An outer lipid layer at the air surface produced by the meibomian glands that reduces evaporation of the aqueous layer; (b) an intermediate aqueous layer produced by lacrimal glands that provides nutrients, suitable osmolarity, and antimicrobial proteins; (c) an inner mucus layer on the epithelial surface produced by goblet cells for ocular surface coating and lowering epithelial cell hydrophobicity [25–35] (Fig. 1).

The Tear Film & Ocular Surface Society Dry Eye Workshop II report categorized DED into two major groups: aqueous-deficient dry eye (ADDE) and evaporative dry eye (EDE). The former refers to failure of lacrimal secretion and is mostly caused by Sjögren and non-Sjögren lacrimal disease. The latter refers to excessive tear loss from the ocular surface and results mostly from MGD. However, many cases present with mixed forms of DED [3,36,37]. The contribution of ADDE to DED incidence is approximately 10%, whereas more than 80% of cases are caused by MGD as well as the combination of ADDE and EDE [4].

The risk factors of DED have been linked to: (a) personal aspects, e.g., increasing age, sex (i.e., greater risk in female subjects), Asian ethnicity, and contact lens use; (b) environmental factors, e.g., exposure to low humidity and windy weather, air-conditioned places, prolonged eye opening (reading, screen use), and environmental pollution; (c), diseases, such as rheumatoid arthritis and Sjögren syndrome, diabetes, thyroid abnormalities, rosacea, hepatitis C, and seasonal and perennial allergies, (d) iatrogenic, e.g., medications, such as postmenopausal estrogen; (e) ocular factors, e.g., lacrimal atrophy, MGD, ocular surgery/injury, and pathological changes in the eyelids, conjunctiva or cornea; (f) dietary deficiencies, e.g., vitamin A and omega-3 fatty acids [38–56].

### 2.1. Meibomian gland dysfunction

The meibomian glands, located in the tarsal plates of the upper and lower eyelids, are responsible for producing lipids and proteins (Fig. 2). Following muscular contraction of the lids, meibum is released onto the

tear film, as these sebaceous glands terminal excretory ducts open at the posterior lid margin. Normal meibum reduces evaporation, affects tear film stability, and protects the ocular surface against microorganisms [26,57,58].

The two main subcategories for pathophysiology-based classification of MGD are low-delivery (hyposecretory MGD) and high-delivery (hypersecretory MGD). The occurrence of the former is linked to the hyposecretion or obstruction of the glands, which is believed to be the main reason for the development of MGD [7]. The latter has mostly been linked to seborrheic dermatitis. MGD can be caused mainly by obstruction of the terminal duct due to thickened opaque meibum or hyperkeratinization of the ductal system.

## 3. Intense pulsed light

### 3.1. Biophysical principles

The emission wavelength of IPL discharged from flashlamps, usually ranging 500–1200 nm, is within the visible light and infrared radiation wavelength of the electromagnetic spectrum (Fig. 3). The produced broad wavelength is considered advantageous, as it can be absorbed by a variety of chromophores in human skin, for example, melanin (400–750 nm) and hemoglobin (578 nm), to develop heat. Both the absorption behavior and penetration depth of the light are functions of wavelength, and the latter is related positively to it (Fig. 4). Depending on the type and condition of the patient's skin, the application of a specific cut-off filter would help to selectively emit the optimal wavelength spectrum to target the structure at a particular depth [59–62]. For example, the intensity of light therapy is determined by the Fitzpatrick scale for scoring patients' skin types to minimize the risk of melanin damage and subsequent hypopigmentation [11,20]. In addition to the selection of the correct wavelengths, the efficacy of the treatment relies on the duration, intervals, and fluence of pulses applied to the target surface. The pulse delivery can be repeated singly, doubly, or triply for a duration commonly between 0.5 and > 20 ms [23,60,63].

### 3.2. Historical background

In 1976, Mühlbauer et al. [64] were the first to apply polychromatic infrared light as thermocoagulation for treating capillary hemangiomas and port-wine stains, leaving intact the non-affected overlying skin layers. In 1983, Anderson and Parrish [65] described the principle of selective photothermolysis through the application of pulsed radiation to damage pigmented structures, cells, and organelles. They demonstrated target selectivity via hemodynamic, histological, and ultrastructural responses in damaged as well as intact structures after in vivo irradiation. Despite such development, far too little attention was paid to the use of polychromatic light therapy before the 1990s [59,66–68]. In 1990, Goldman and Eckhouse introduced a new high-intensity flashlamp for treating vascular irregularities of the skin. As a result, the first commercially available medical device with IPL technology, PhotoDerm VL (Lumenis Ltd., Yokneam, Israel), was released to the market in 1994 [62,69]. In 2002, Rolando Toyos presented a case report of a patient treated with IPL for facial rosacea. The beneficial effects from the energy pulse were not limited to decreased facial erythema with dry eye, but were also accompanied by improvement in the clinical signs and symptoms of MGD. His collaboration with DermaMed Solutions led to the development of an IPL system that has opened new avenues for managing patients with DED [23,70]. As of yet, DermaMed has FDA labelling for treatment of rosacea patients, but not DED or MGD.

### 3.3. Device development

Since the 1990s, attempts have been made to modify Goldman and Eckhouse's original design for ease of operation, promoting safety and broadening the spectrum of potential indications. Early versions of the

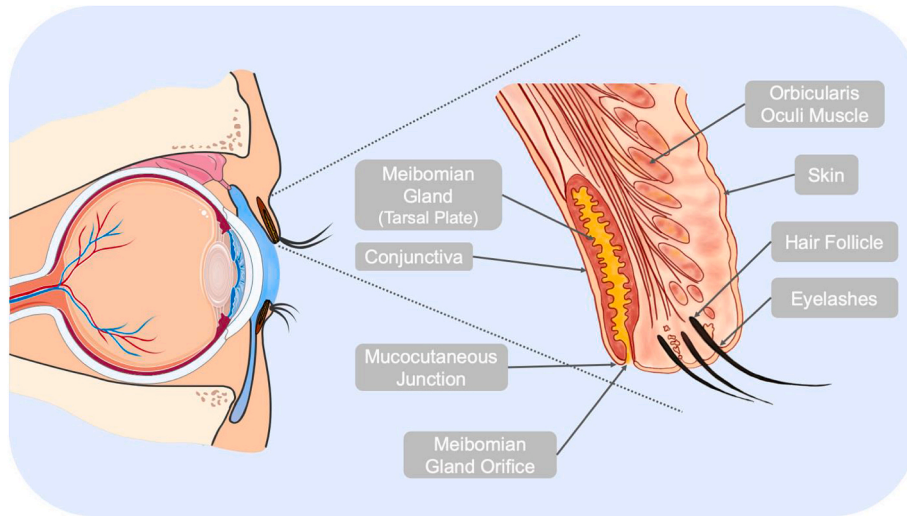


Fig. 2. The anatomy of the human eyelid. The meibomian glands are located in the tarsal plates of the upper and lower eyelid.

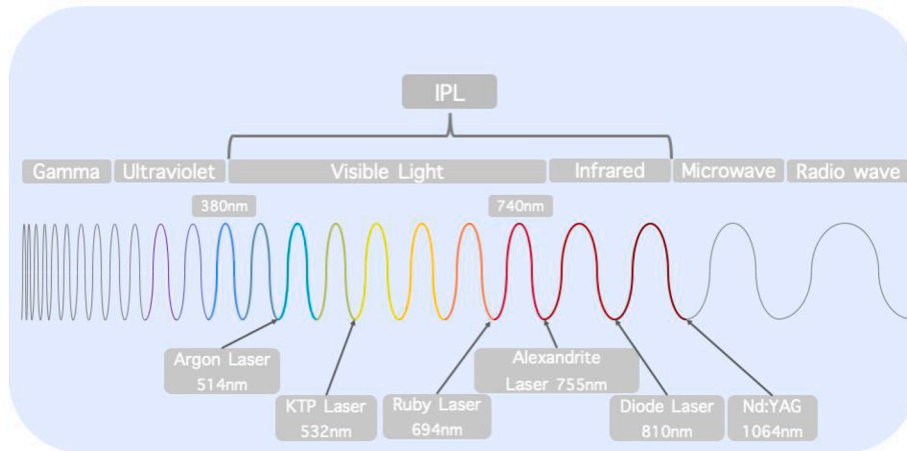


Fig. 3. The wavelengths of IPL (in the visible light and infrared radiation wavelengths; usually 500–1200 nm) and selected lasers within electromagnetic spectrum.

IPL device discharged the infrared portion of the wavelength spectrum, causing widespread epithelial damage, whereas in the later-generation IPL devices, the risk of adverse effects was minimized effectively using water as a filter. The modern generations of this device are equipped

with computer-controlled capacitor banks and high-output flashlamps to emit polychromatic, noncoherent, and noncollimated light. In practice, the conversion of electrical to optical energy occurs when stored electrical current in the capacitor bank passes through a xenon gas-

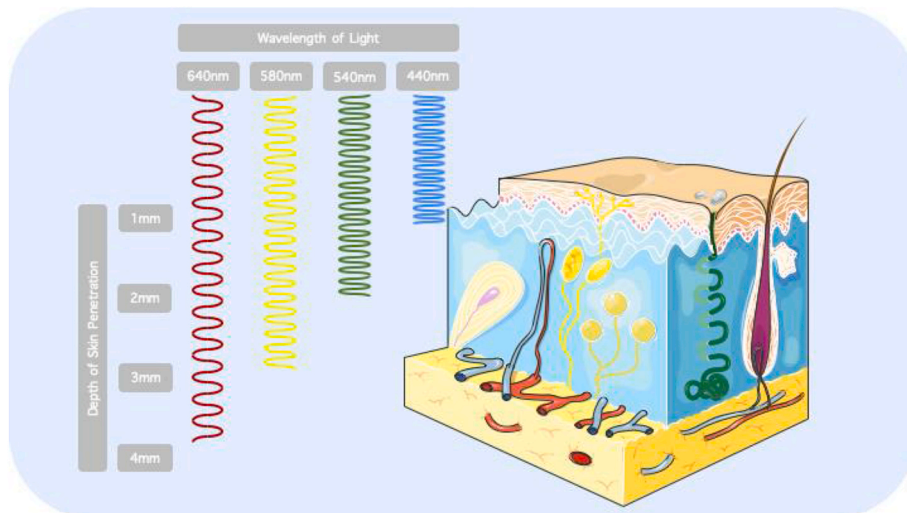


Fig. 4. The penetration depth of light at different wavelengths in skin tissue.

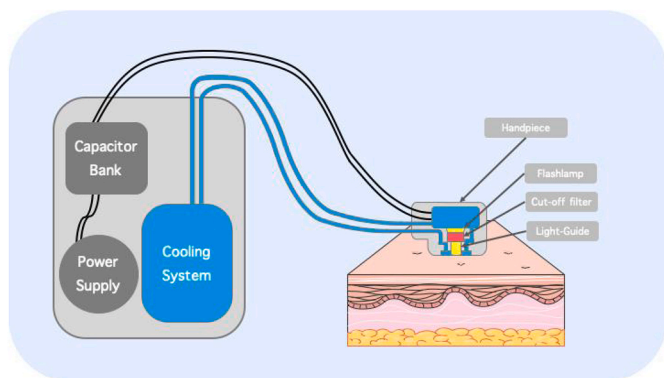


Fig. 5. A schematic representation of a typical IPL system.

filled chamber to produce bright light. Then, it is transferred through the distal end of the handpiece to be delivered to the skin surface using a sapphire or quartz block (Fig. 5).

An ideal IPL device should have a large capacitor bank for supplying a constant current and emit wavelengths above 950 nm using water as an energy absorbent for excluding epidermal heating consequences [63,69]. Most of the available devices utilize low-intensity energies (8.5–20 J/cm<sup>2</sup>) and may be accompanied with computerized software programs to provide users with default parameters for the treatment session. When managing patients with MGD, the proprietary “dry eye mode” setup must be used [11,71]. Before applying IPL (Fig. 6), the area being treated must be cleaned of makeup/facial care products. The eyes should be covered with protective eye shields to avoid intraocular damage. Moreover, to prevent the risk of epidermal burns due to close contact with the conduction crystal of the handpiece, an appropriate approach must be implemented depending on the system in use, such as integrated cooling of the IPL crystal (contact cooling, cryogen spray, or forced refrigerated air) and/or applying a thick layer of cold/ultrasound gel [11,20,60,63].

### 3.4. Pros and cons

The basic principle of IPL treatment is selective photothermolysis. It is often concomitant with adverse effects such as stinging pain, swelling, erythema, blistering, crusting, and scattered lesions. The possibility of nonspecific thermal damage to the surrounding tissue is prevented by reducing the pulse duration to lower than that of the thermal relaxation times. In addition, the improved models of IPL devices with the newest progressive set of parameters have significantly reduced the occurrence of acute adverse effects [60]. Handling and operation

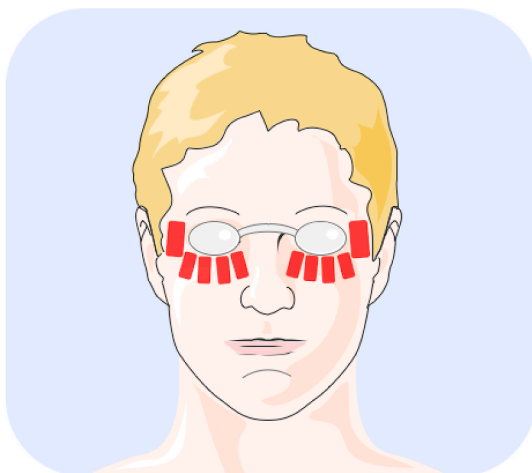


Fig. 6. The sample treatment area in IPL therapy of MGD.

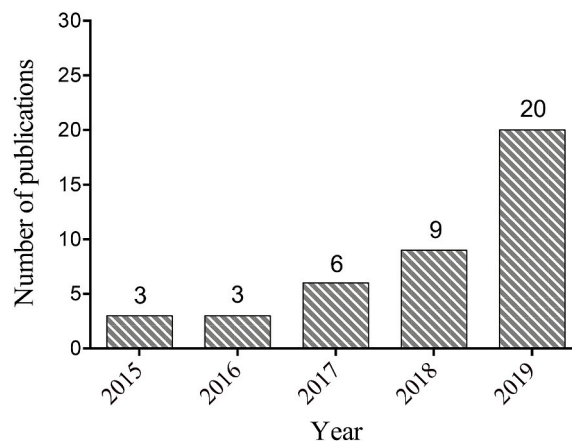


Fig. 7. The number of publications in the PubMed database on the application of IPL for treating MGD since 2015.

require a high level of training and experience, which casts doubt on the idea of home-use IPL devices as over-exposure and operator errors may cause ocular damage.

The price of a flashlamp device is lower than that of other light therapies such as laser, but the application is more often aimed at gaining and maintaining satisfactory results. Besides, IPL can cover a large treatment area and the technology is robust. However, the size and weight of the handpiece, which is in close contact with the skin, are inconvenient, and its flat surface hampers the treatment of irregular surfaces. The inability to focus the light as well as inconsistency in output (spectrum and fluence) are also important concerns [13,69].

### 3.5. Selection method

IPL is a widely used technology in dermatology. As IPL is a relatively new treatment modality for MGD, there are limited reports in the literature. For this review, we searched the PubMed database with the following search terms: “Intense pulsed light, meibomian gland dysfunction”. The search was performed in December 2019 and returned 41 results. We noted a significant increase in the number of publications on IPL over the last 4 years (Fig. 7). The exclusion criteria for this review were: a) abstracts (1), b) letters to the editor (3), c) articles in other languages than English (3), d) review articles (8) and e) full text not available (2). Following these exclusions, 25 articles remained, whereof 17 were prospective and six were retrospective studies (Table 1).

## 4. Outcomes of clinical studies

### 4.1. Efficacy

Based on the studies included in this review, the IPL therapy procedures were performed either as a stand-alone instrumental treatment or in combination with manual expression of the meibomian glands (MGX). Thus, this review is divided into two parts. First, it summarizes the findings of 14 out of 25 reports on IPL therapy alone, followed by that of combination therapy (IPL with MGX). Prospective randomized studies are first reported, followed by prospective non-randomized and retrospective studies.

### 4.2. IPL as a stand-alone instrumental treatment modality

Fourteen [14,17,19,72–77,81,86–89] out of 25 stand-alone instrumental treatment modality studies, five were randomized [17,19,72–74], four prospective and four retrospective studies. One article [84] did not mention the study type.

**Table 1**  
Summary of studies using IPL therapy for treating DED.

Study (First Author/Year) Country of origin	Study Objective	Study Type	Number of Patients	Treatment Sessions (Intervals)	Additional Treatment to IPL	Adverse Events	Conclusion
1. Craig et al. (2015) [72] New Zealand	To evaluate the effect of IPL applied to the periocular area for treating MGD	Prospective, double-masked, placebo-controlled, paired-eye study	28	3 (D1, D15, D45)	NR	NR	IPL shows therapeutic potential for MGD, improves tear film quality, and reduces symptoms of dry eye
2. Liu et al. (2017) [73] Toyos group. China	To investigate the alteration in inflammatory markers of tears with MGD-associated DED following IPL therapy and MGX compared to sham treatment, and the correlations with ocular surface parameters	Randomized double-masked controlled study	44	3 (4 weeks apart)	Polyethylene glycol eye drops three times a day	NR	IPL can significantly reduce inflammatory markers in tears in patients with MGD
3. Li et al. (2019) [17] China	To evaluate the effect and safety of IPL therapy in Fitzpatrick skin types III–IV	Prospective randomized study	40	3 sessions	Hyaluronic acid sodium eye drops during treatment sessions	No	IPL is safe and effective in patients with MGD with skin types III–IV
4. Piyaomn et al. (2019) [19] Thailand	To study the efficacy and safety of IPL therapy in patients with MGD	Randomized, double-masked, sham-controlled clinical trial	114	3 (D1, D15, D45)	Artificial tears four times a day, lid scrubs and warm compress	No	IPL is effective and safe for MGD treatment at all stages, regardless of compliance Significant changes in IL-1 Ra levels in both groups, no changes in IL-6 levels
5. Gao et al. (2019) [74] China	To compare the anti-inflammatory effect of IPL therapy with tobramycin/dexamethasone plus warm compress	Prospective randomized study	82	3 (4-week intervals)	Cold compress with cold washcloth for 10 min and sodium hyaluronate eye drops four times a day	NR	IPL can improve TBUT and MGX. IL-17A and IL-1β levels in the IPL group showed a transient decrease at 1 week follow up when compared to tobramycin/dexamethasone plus warm compress cohort IPL combined with MGX treated MGD safely and effectively
6. Rong et al. (2018) [15] Toyos group. China	To determine the efficacy and safety of IPL applied directly on the eyelids and MGX for treating MGD	Prospective, randomized, double-masked controlled study	44	3 (every 4 weeks)	MGX after IPL therapy	Mild pain, burning, mild redness of the eyelids	IPL combined with MGX improves MG secretion function and TBUT in 6 months after treatment
7. Rong et al. (2018) [75] China	To evaluate the long-term effect of IPL combined with MGX for treating MGD	Prospective, randomized, double-masked controlled study	28	3 (every 4 weeks)	MGX	No	IPL combined with MGX improves homeostasis of the tear film and ameliorates ocular symptoms in patients with refractory MGD
8. Arita et al. (2019) [16] Japan	To evaluate the efficacy and safety of IPL combined with MGX for treating refractory MGD	Prospective, controlled, randomized study	45	8 sessions (3 weeks apart)	MGX after IPL therapy for treatment group; only MGX for control group	No	IPL is a safe and efficient treatment in relieving symptoms and signs of MGD eyes
9. Jiang et al. (2016) [14] China	To explore the safety and efficacy of IPL in eyes with MGD	Prospective open-label study	40	4 (D1, D15, D45, D75)	NR	No	IPL improves the symptom score of patients, associated ocular surface indexes, MG function, and MG macrostructure as well as eyelid hygiene; particularly improves MG microstructure and decreases MG inflammation
10. Yin et al. (2018) [76] China	To study MG changes and underlying mechanism after exposure to IPL	Cohort controlled study	35	3 (every 30 days)	Artificial tears three times a day	NR	

(continued on next page)

**Table 1** (continued)

Study (First Author/Year) Country of origin	Study Objective	Study Type	Number of Patients	Treatment Sessions (Intervals)	Additional Treatment to IPL	Adverse Events	Conclusion
11. Ahmed et al. (2019) [77] Egypt	To assess the effect of a novel IPL therapy on tear proteins and lipids in eyes with MGD	Prospective study	12	NR	NR	NR	IPL is effective in eyes with MGD by improving tear protein and lipid content and composition. The anionic phospholipids were more responsive to IPL than other zwitterionic phospholipids
12. Vigo et al. (2019) [78] Italy	To evaluate changes of signs and symptoms in patients with MGD treated with IPL and to investigate predictors of positive outcomes	Prospective study	28	3 (D1, D15, D45)	Preservative-free tear substitute and eyelid hygiene; instillation of 0.3% cortisol phosphate in hyaluronic acid vehicle eye drops twice a day for 10 days after the first session of IPL	No	IPL improves signs and symptoms in patients with MGD, while lower baseline NIBUT values were predictive of better response to IPL
13. Deil et al. (2017) [79] USA	To estimate the efficacy of combined IPL therapy and MGX for reducing the number and severity of signs and symptoms of DED secondary to MGD	Prospective, multisite, interventional, single-arm, exploratory before–after study	40	4 (3 weeks apart)	MGX after IPL therapy, continuation of standard MGD treatment	NR	Combination of IPL and MGX is efficient in relieving both signs and symptoms of DED secondary to MGD
14. Albietz et al. (2018) [80] Australia	To evaluate the efficacy of periocular IPL therapy combined with MGX for chronic dry eye due to moderate to advanced MGD	Prospective open-label study	26	3 (D1, W2, W6)	MGX after IPL therapy, continuation of standard MGD treatment	No	IPL combined with MGX improves dry eye symptoms and clinical signs
15. Arita et al. (2018) [81] Japan	To evaluate the efficacy of IPL therapy combined with MGX for refractory MGD at three sites in Japan	Prospective multicenter study	31	4–8 sessions depending on the meibum grade (3-week intervals) 4 (every 3 weeks)	Continuation of current ocular medications MGX after IPL therapy	NR	IPL combined with MGX ameliorated symptoms and improved the condition of the tear film in patients with refractory MGD
16. Seo et al. (2018) [82] South Korea	To determine the long-term effect of IPL treatment in rosacea-associated MGD	Prospective case series	17	4 (every 3 weeks)	MGX after IPL therapy	No	In rosacea-associated MGD, four IPL treatments at 3-week intervals can improve long-term lid parameters and ocular symptoms without adverse effects
17. Choi et al. (2019) [83] South Korea	To investigate the effect of signs and symptoms following IPL therapy; the course of change in inflammatory tear cytokines, and the correlation between cytokines and ocular surface parameters	Prospective study		3 sessions (3-week intervals)	MGX after IPL therapy	No	Meibum expressibility improvement might be a good therapeutic target of IPL treatment in patients with MGD and DED, and could be an indicator of ocular surface inflammation during IPL treatment. Treatment induced a significant reduction of measured inflammatory cytokines
18. Toyos et al. (2019) [18] USA	To investigate the safety and change from baseline of TBUT and visual analog pain scales in DED subjects with upper lid MGD after IPL therapy, assessing global ocular pain severity, ocular pain frequency, and ocular pain over the past 24 h	Prospective single-site study			MGX	No	The new specialized 6-mm cylindrical handpiece for the M22 Lumenis IPL machine is safe and effective
19. Vigo et al. (2019) [84] Italy	To evaluate the effect of IPL therapy for treating MGD	NR	19	3 (D1, D15, D45)	Steroid eye drops twice a day, 10 days with warm compresses and lubricants twice a day	NR	IPL in patients with MGD-associated dry eye improves noninvasive TBUT, lipid layer thickness, and subjective symptoms
20. Toyos et al. (2015) [12] USA	To determine the clinical benefits of IPL therapy for treating DED caused by MGD	Retrospective noncomparative interventional case series	91	Every 30 days (during 30 months)	Lid expression with finger/cotton tip, steroid or NSAID eye drops	Blistering, cheek swelling, conjunctival cyst, hair loss, light sensitivity, redness	IPL is promising for treating MGD symptoms
21. Vegunta et al. (2016) [85] USA	To assess the effect of combination therapy of IPL and MGX in patients with refractory DED	Retrospective case series	35	1–4 (4–6 weeks apart)	MGX	NR	IPL plus MGX can significantly improve dry eye symptoms and MG function

(continued on next page)

Table 1 (continued)

Study (First Author/Year) Country of origin	Study Objective	Study Type	Number of Patients	Treatment Sessions (Intervals)	Additional Treatment to IPL	Adverse Events	Conclusion
22. Gupta et al. (2016) [86] Canada	To determine the clinical outcomes of IPL therapy for treating EDE	Retrospective multicenter cohort study	100	3–6 (3–6 weeks apart)	Steroid drops, continuation of current ocular medications (artificial tears, cyclosporine, antibiotics, omega-3, EPA, DHA)	No	IPL therapy for EDE is a safe procedure
23. Karaca et al. (2018) [87] Turkey	To assess the effect of intense regulated pulse light (E > Eye; E-Swin, France) on MGD	Retrospective controlled study	26	3 (D1, D15, D45)	NR	No	IPL is a safe treatment procedure for MGD that which improves tear film quality and reduces symptoms of dry eye
24. Stonecipher et al. (2019) [88] USA	To evaluate the effect of combined IPL and LLLT on clinical measures of dry eye related to severe MGD in subjects unresponsive to previous medical management	Retrospective study	230		Topical gatifloxacin and prednisolone antibiotic/steroid combination three times a day for 2 weeks, and oral doxycycline (100 mg × 1) twice a day	No	IPL combined with LLLT for treating severe MGD appears to be beneficial in patients who have failed topical and/or systemic therapy
25. Cheng et al. (2019) [89] China	To observe the clinical changes of MGD and ocular Demodex infestation after IPL therapy to explore underlying mechanisms	Retrospective study	25	4 sessions (D1, D7, D21, D45)	NR	NR	IPL shows great therapeutic potential for patients with MGD and ocular Demodex infestation
26. Caballero et al. (2017) [90] Spain	To determine the clinical benefits of IPL in ADDE and EDE	Case series	36	4 (D1, D15, D30, D45)	Continuation of current ocular medications (artificial tears, food supplements)	Redness, light sensitivity	Potentially beneficial treatment for DED due to MGD. Probably not helpful for patients with aqueous or mucinous deficiency
27. Mejia et al. (2019) [91] Colombia	To evaluate the effect of IPL as a supplementary treatment in DED	Retrospective cross sectional	25	3 (D1, D15, D30)	Continuation of previous pharmacological treatment and warm compresses	NR	Improved subjective and objective measurements after treatment

Abbreviations: IPL, Intense pulsed light; DED, dry eye disease; EDE, evaporative dry eye disease; MG, meibomian gland; MGD, meibomian gland dysfunction; MGX, meibomian gland expression; TBUT, tear film break-up time; D, day; W, week; EPA, eicosapentaenoic acid; DHA, docosahexaenoic acid; LLLT, low-level light therapy; NIBUT, noninvasive break-up time; NSAID, nonsteroidal anti-inflammatory drugs; IL-6, interleukin 6; IL-1Ra, interleukin 1 receptor agonist; IL-17A, interleukin 17A; IL-1β, interleukin 1β; NR: not reported.

#### 4.2.1. Randomized studies

In 2015, Craig et al. conducted a prospective, double-masked, placebo-controlled, paired-eye trial aiming to evaluate the effect of IPL for treating MGD. The study lasted 45 days and involved 28 patients with mild to moderate clinical signs of MGD [72]. The treatment included three sessions on day 1, 15, and 45. IPL-treated eyes showed statistically significant improvements in lipid layer grade, noninvasive tear film break-up time (NIBUT), and subjective self-reported rating of dry eye symptoms. The tear evaporation rate and tear osmolarity did not differ between pre- and post-treatment sessions. The authors applied IPL treatment with a white-blocking filter in the placebo eye. Therefore, the placebo effect may have been compromised by light escaping the filter. The amount of light escaping the filter was not possible to quantify, thus, this may have contributed to control eyes receiving IPL to some degree. Another limitation in this study was the short follow-up time (45 days). Lasting effect of the treatment was not measured.

In another study with a larger sample size by Piyacomn et al., 114 patients with MGD were recruited and underwent the IPL treatment. They reported early improvement of OSDI score and meibomian gland functionality in the treatment group (day 15 vs. day 45) [19]. The authors reported a significant decrease in interleukin (IL)-1 receptor agonist in the group receiving IPL as well as the control group, but no differences between them. This might be a result of the inclusion of conservative measures such as warm compresses, lid scrubs and artificial tears in both groups. The authors found no differences in IL-6 level in either of the groups. At the 6-month follow-up, the treatment group had better OSDI scores, TBUT and meibomian gland functionality.

A study by Liu et al. [73] investigated change in inflammatory markers of the tear film of 44 patients with MGD following three IPL therapy sessions (4 weeks apart). The results showed a decline in IL-17A, IL-6, and prostaglandin (PGE)2 levels. In another study by Gao et al., the anti-inflammatory effect of IPL was compared with tobramycin/dexamethasone plus warm compress in 82 patients with MGD [74]. The authors concluded that IPL therapy led to improved TBUT and meibomian gland expressibility. The inflammatory cytokines IL-17A and IL-1 $\beta$  showed a transient downregulation at the 1-week follow-up of the IPL group, which became insignificant at 1-month follow-up. It is noteworthy that the clinical effects of IPL peaked at the 1-month follow-up. None of the studies reported adverse events related to the IPL therapy.

#### 4.2.2. Prospective, non-randomized studies

In 2016, Jiang and co-workers carried out a prospective open-label study on the safety and effectiveness of IPL including 40 patients with MGD [14]. The study period was 75 days, with patients receiving four separate IPL sessions on day 1, 15, 45, and 75. The study demonstrated improvements in the subjective feeling of ocular dryness, tear film break-up time (TBUT), corneal staining, conjunctival injection, tear meniscus height, and meibomian gland functionality over the 75-day period.

Two years later, Yin et al. analyzed changes in meibomian gland morphology along with other clinical tests in a controlled cohort study of 18 patients with MGD [76]. The patients underwent three sessions with 30-day intervals, whereas the control group (n = 17) received eyelid hygiene. While OSDI score, TBUT, and meibomian gland functionality improved in both groups, only the IPL-treated group showed significant improvements in meibomian gland morphology.

Ahmed et al. assessed the effect of a single session of IPL therapy on both tear proteins and lipids in 24 patients with MGD [77]. The treatment resulted in elevated levels of tear lysozyme, lactoferrin, and albumin as well as total lipids, triglycerides, cholesterol, and phospholipids.

Similarly, a prospective study by Vigo and co-authors reported improved subjective symptoms, NIBUT, and lipid layer thickness in most patients following three sessions of IPL therapy over 45 days [78].

#### 4.2.3. Retrospective studies

A multi-center cohort study by Gupta et al. involved 100 patients with MGD who underwent an average of four IPL treatments at 3–6 weeks intervals [86]. The authors reported decreased lid margin edema, facial telangiectasia, lid margin vascularity, and Ocular Surface Disease Index (OSDI) questionnaire score. There were also improvements in TBUT and meibomian gland functionality.

A retrospective case series by Karaca et al. involved 26 patients with mild to moderate MGD who underwent three IPL therapy sessions on day 1, 15, and 45 [87]. The patients showed improvements in Schirmer test, TBUT, OSDI and SPEED (Standard Patient Evaluation of Eye Dryness questionnaire) scores by day 45 without any adverse ocular effects. Another study published in 2019, with 19 patients using the same device and treatment protocol (three sessions on day 1, 15, and 45) reported improvements in NIBUT, lipid layer thickness, and subjective symptoms [82]. In contrast, OSDI score, tear osmolarity and meibomian gland loss remained unchanged.

Cheng and colleagues performed a retrospective study of 25 patients who underwent four IPL therapy sessions over the course of 42 days [89]. They reported a *Demodex* eradication rate of 20%, along with improvements in meibomian gland functionality and morphology, using meibography and in vivo confocal microscopy. These findings were corroborated in a single-blinded, randomized, controlled clinical trial performed by Zhang et al. [92]. This study compared the effect of IPL to a control group receiving tea tree oil (TTO), which is an established therapy for treatment of demodex mites. Both study groups showed a significant reduction of demodex infestation as well as improved clinical parameters. The cohort receiving IPL showed significantly improved OSDI, meibum quality and TBUT as compared to the TTO controls. Both treatments were similarly effective in *Demodex* eradication. However, TTO is reported to have eye irritation and redness as adverse effects [93]. Thus, the potential of IPL emerging as an alternative treatment of demodex should be a major avenue for future research. It is reported that *Demodex* causes inflammation [94]. *Demodex* infestations appear to affect over 80% of the population above the age of 60 [95]. As IPL can induce coagulation and necrosis of *Demodex*, it provides the rationale for using IPL to treat these infestations [92].

#### 4.3. IPL therapy combined with manual expression of the meibomian glands

Eleven out of 25 articles reported results from the IPL therapy combined with manual expression of meibomian glands (MGX). Three studies had a prospective, randomized design, whereof six studies were non-randomized prospective and two were retrospective.

##### 4.3.1. Randomized studies

Rong et al. carried out a prospective, randomized, double-masked controlled study with 44 patients [15]. The treatment group received three IPL therapy sessions at 4-week intervals. Besides, both eyes were treated with MGX and artificial tears. The group receiving IPL therapy demonstrated improved meibomian gland yielding secretion score (MGYSS), TBUT, SPEED, and corneal fluorescein staining (CFS). The control group, however, presented improvements only in the SPEED and corneal fluorescein staining scores. A few months later the same research group reported that IPL lacks long-term therapeutic effects (> 6 months) with regard to improved TBUT and meibomian gland functionality [75]. In their prospective, randomized, double-masked controlled study, 28 patients with MGD underwent three IPL therapy (real or sham) plus MGX sessions at 4-week intervals. The treatment group presented greater improvements in TBUT and MGYSS, which lasted until the 6-month follow-up, but there was no difference after 9 months. There was no difference in SPEED and CFS scores between the two groups.

In 2019, Arita et al. published a randomized prospective study comparing the effect of IPL plus MGX vs. only MGX in 90 eyes of 45



patients with refractory MGD [16]. The subjects received eight IPL therapy sessions with MGX. The IPL plus MGX group had significantly improved lipid layer thickness, NIBUT, TBUT, lid margin abnormalities, meibum grade, and SPEED score after 32 weeks. The control group did not receive sham IPL treatment and the study was not masked. It is therefore difficult to assess potential pre- and post-treatment evaluation bias.

#### 4.3.2. Prospective, non-randomized studies

A prospective study by Dell et al. involving 40 patients (moderate to severe MGD) at two different sites showed improved TBUT, meibomian gland score, corneal staining, and SPEED score without changes in lipid layer thickness [79]. The treatment protocol was four IPL therapy sessions (3 weeks apart), followed by MGX of the upper and lower lids.

The following year, Albietsz et al. used the same treatment protocol, except for a 2-week interval between session 1 and session 2 and a 4-week interval between session 2 and 3 [80]. In that prospective study, the authors evaluated the effect of IPL with MGX in 26 patients with MGD. After 8 weeks' follow-up, they reported improved meibomian gland functionality, TBUT, corneal staining, lid margin, and limbal redness. The OSDI score was improved at the 12-week follow-up.

At the same time, Arita et al. carried out a prospective multicenter study assessing the effect of IPL plus MGX [81]. Thirty-one patients underwent 4–8 IPL plus MGX sessions with 3-week intervals. They reported improved SPEED, NIBUT, TBUT, meibum grade, lid margin abnormality scores, and conjunctival staining. Schirmer test values and meiboscore remained unchanged. In MGD, meibum in the meibomian glands becomes viscous. One of the mechanisms of action of IPL is to render meibum less viscous through liquification. This might be due to the thermal energy delivered to the skin surrounding the eyelids.

It is also believed that IPL therapy dilates the meibomian glands [12]. Therefore, the combination of IPL and manual expression of meibomian glands (MGX) is believed to yield better clinical results. Several studies have reported the outcomes of combination treatment involving IPL therapy and MGX.

Toyos and colleagues recently investigated changes in TBUT and the visual analog pain scale in patients with upper lid MGD after IPL therapy [18]. Their findings showed improved TBUT, global dryness scale, eye dryness (in the past 24 h), and frequency of ocular pain episodes. Using the same protocol, Seo and co-authors conducted a prospective case series study in 17 patients with rosacea-associated MGD [82]. Even though the patients had improved ocular surface [TBUT, noninvasive keratograph TBUT (NIKBUT), and staining score] and meibomian gland parameters (lid margin vascularity, meibum expressibility and quality), the results obtained for TBUT, staining score and NIKBUT did not last more than 6–12 months after IPL treatment sessions.

Choi et al. studied the anti-inflammatory effect of IPL plus MGX on tear inflammatory markers along with subjective feeling of ocular dryness using the OSDI questionnaire, meibomian gland functionality, lid margin abnormality, TBUT, and ocular surface staining [83]. Thirty subjects who underwent three IPL plus MGX sessions at 3-week intervals were included in that prospective study. The treatment resulted in improved OSDI score, meibomian gland functionality, lid margin abnormality, TBUT, and ocular surface staining. Additionally, tear levels of IL-4, IL-6, IL-10, IL-17A, and tumor necrosis factor (TNF)- $\alpha$  were decreased after the treatment.

#### 4.3.3. Retrospective studies

In a retrospective case series published in 2015 by Toyos et al. [12], patients with MGD ( $n = 91$ ) received IPL therapy followed by MGX for 30 s with a cotton tip and the eye care practitioner's finger. The treatment protocol employed for improving DED included four sessions, with repeated IPL therapy every 30 days. Most of the patients (87%) had improved TBUT and self-reported dry eye symptoms (93%). Fourteen percent of the patients experienced adverse events such as

blistering, cheek swelling, conjunctival cyst, floaters, hair loss at the brow and forehead, light sensitivity, and face redness. The authors concluded that the method was promising, warranting larger studies. A similar retrospective study by Vegunta et al., in 2015 included 35 retrospective cases who received 1–4 IPL therapy sessions with MGX every 4–6 weeks [85]. The authors concluded that 89% of the patients had reduced SPEED questionnaire scores and that 77% of the patients had improved meibomian gland function.

#### 4.4. Safety outcomes

In 13 of the 25 studies considered in this review, no participant experienced adverse events. Ten studies did not report whether adverse events occurred during or after the IPL therapy sessions. Only two studies reported mild transient adverse events. Toyos et al. reported that two of 13 patients experienced adverse events [12]. The adverse effects included blistering, cheek swelling, conjunctival cyst, floaters, hair loss at the brow and forehead, light sensitivity, and face redness. Most of the adverse events resolved within 1 week. Rong et al. reported mild pain and burning during IPL therapy in five patients, while one patient had partial eyelash loss [15]. In contrast, six of the 25 studies concluded that IPL therapy is safe and without adverse events [14–19].

### 5. Discussion

The treatment of MGD is a challenging task for ophthalmologists. Even though several medical as well as instrumental treatment options are available, achieving long-lasting improvement is difficult. Among ophthalmic practitioners, the acceptance rate of IPL therapy for treating MGD has increased over the years. Different theories have attempted to explain the positive effects of IPL for treating MGD. One theory postulates that IPL liquifies meibum, leading to better secretion, thus improving meibomian gland functionality and TBUT [24]. The vast majority of the included studies reported improved meibomian gland functionality [14,16,19,74,76,80–83,85,86,88,89] and TBUT [12,14–19,74,75,80–83,86–88]. It has also been suggested that IPL can induce coagulation of the superficial blood vessels and reduce inflammatory cytokines [12,96,97]. A few independent studies have reported reduced inflammatory cytokines after IPL treatment. However, the mechanisms of action of IPL therapy in MGD treatment are not fully understood [73,83,97].

In the reviewed literature, the study outcomes share interesting similarities, such as consistent improvements in OSDI, TBUT, and meibomian gland functionality, and no changes in tear production (Schirmer test) and tear osmolarity (Tables 2 and 3). In contrast, post-IPL treatment changes in ocular surface staining are variable. Importantly, a large number of studies have shown that IPL is a safe treatment modality without any serious adverse effects. However, there is limited number of randomized clinical trials investigating the effects of the IPL therapy. Only eight of 25 articles in this review included randomized studies and only five of those studies were double-masked. Of note, the randomized studies were performed mainly in Asian countries (China, Japan and Thailand) and New Zealand. Research groups such as Toyos and Arita have pioneered in this field and published several articles, whereof three of eight randomized studies belong to those groups. IPL therapy is approved by the Food and Drug Administration (FDA) for treatment of rosacea and has been used as an off-label treatment for MGD, which may explain the lack of randomized studies in USA. However, in Europe, IPL therapy is used for this purpose by ophthalmic care personnel. Nevertheless, no randomized clinical trials have been reported by European specialists.

The comparisons of studies are limited by several factors. Data collection and inclusion/exclusion criteria were not identical between the studies. In addition, there was heterogeneity with regard to the study designs (retrospective/prospective). The questionnaires and clinical tests included in the IPL studies varied substantially. Several

**Table 2**  
Overview of changes in DED parameters after IPL treatment.

Study (First Author/Year)	OSDI	SPEED	TFBUT	NIBUT	LLT	BR/LR	CS	CjS	ST	MGM	TO	TER	MGS	LMA	LME	LMV	ME	MQ	MGYSS
1. Craig et al. (2015) [72]	na	+	na	+	+	na	na	na	na	na	0	0	na	na	na	na	na	na	na
2. Toyos et al. (2015) [12]	na	na	+	na	na	na	na	na	na	na	na	na	na	na	na	na	na	na	na
3. Vegunta et al. (2016) [85]	na	+	na	na	na	na	na	na	na	na	na	na	na	na	na	na	+	na	na
4. Jiang et al. (2016) [14]	na	na	+	na	na	na	0	+	na	na	na	na	na	na	na	na	+	+	na
5. Gupta et al. (2016) [86]	+	na	+	na	na	na	na	na	na	na	na	na	na	na	+	+	+	+	na
6. Liu et al. (2017) [73]	na	na	na	na	na	na	na	na	na	na	na	na	na	na	na	na	na	na	na
7. Dell et al. (2017) [79]	na	+	na	na	0	na	+	na	na	na	+	na	+	na	na	na	na	na	na
8. Albietz et al. (2018) [80]	+	na	+	na	na	+	+	+	0	na	0	na	na	na	na	+	+	+	na
9. Arita et al. (2018) [81]	na	+	+	+	+	na	na	+	0	+	na	na	na	+	+	+	+	na	
10. Rong et al. (2018) [15]	na	+	+	na	na	na	+	na	na	na	na	na	na	na	na	na	na	na	+
11. Karaca et al. (2018) [87]	+	+	+	na	na	na	0	0	+	na	na	na	na	0	na	na	0	0	na
12. Yin et al. (2018) [76]	+	+	na	na	na	na	0	+	0	+	na	na	na	na	na	na	+	+	na
13. Seo et al. (2018) [82]	+	na	+	+	na	na	+	+	+	na	na	na	na	na	na	+	+	na	
14. Rong et al. (2018) [75]	na	+	+	na	na	na	+	na	na	na	na	na	na	na	na	na	na	na	+
15. Arita et al. (2019) [16]	na	na	+	+	+	na	+	na	0	na	na	na	na	+	na	na	+	na	na
16. Li et al. (2019) [17]	+	na	+	na	na	na	na	na	na	na	na	na	na	na	na	na	na	na	na
17. Vigo et al. (2019) [84]	0	na	na	+	+	na	na	na	na	0	0	na	na	na	na	na	na	na	na
18. Ahmed et al. (2019) [77]	na	na	na	na	na	na	na	na	na	na	na	na	na	na	na	na	na	na	na
19. Choi et al. (2019) [83]	na	na	+	na	na	na	+	+	na	na	na	na	na	na	+	na	+	+	na
20. Stonecipher et al. (2019) [88]	+	na	+	na	na	na	na	na	na	na	na	na	na	na	na	na	+	+	na
21. Toyos et al. (2019) [18]	na	na	+	na	na	na	na	na	na	na	na	na	na	na	na	na	na	na	na
22. Cheng et al. (2019) [89]	+	na	na	+	+	na	+	na	0	+	na	na	na	+	+	+	+	+	na
23. Piyacomn et al. (2019) [19]	+	na	+	na	0	na	0	0	0	0	0	na	na	na	na	na	+	+	na
24. Vigo et al. (2019) [78]	+	na	na	+	+	na	na	na	na	0	+	na	na	na	na	na	na	na	na
25. Gao et al. (2019) [74]	+	na	+	na	na	na	+	na	na	0	na	na	na	na	na	na	+	0	na

+ improved, - - worsened, 0 – did not change, na – not applicable/not included, SRI – self-reported improvement, BR/LR – bulbar redness/limbal redness, CS – corneal staining, CjS – conjunctival staining, CI – conjunctival injection, TMH – tear meniscus height, ST – Schirmer’s test, MGM – meibomian gland morphology, TO – tear osmolarity, TER – tear evaporation rate, MGE –number of lower eyelid meibomian glands observed yielding liquid secretion, MGS – meibomian gland score, LMA – lid margin abnormality, LME – lid margin edema, LMV – lid margin vascularity, ME – meibum expressibility, MQ – meibum quality, MGYSS – Meibomian glands yielding secretion score.

<sup>a</sup> Was not maintained at 6- and 12-months follow-up.

studies did not use common dry eye examinations. The most consistently reported analysis was TBUT. Moreover, there was great variability in the number of sessions, IPL therapy duration, as well as additional treatments, such as MGX, lid hygiene, warm compress, and lubricating drops (Table 1) This could be explained by the lack of evidence-based treatment guidelines for the use of IPL in MGD treatment. There is no consensus either with regard to the number of IPL treatment sessions or the session intervals. Further studies are warranted to reveal the optimal settings. The lack of standardized treatment protocol makes it challenging to directly compare results from IPL studies due to many unknown factors that potentially could contribute to either positive or negative clinical outcome. This obviously hampers the progress of future development of the technology. By standardizing the treatment protocol, it will be easier to determine if certain patients are more likely to respond positively to the treatment (sex, age, comorbidities, etc.). Moreover, it will ease the evaluation of the potential of combining IPL with other therapies to treat MGD. In-depth biochemical analyses of the tear film of patients with different subtypes of MGD using various omics technologies are likely to substantially advance our understanding of the mechanisms involved. This represents a second path to improved future therapy of MGD.

**Table 3**  
Percentage of studies reporting changes in clinical tests before and after IPL treatment.

	OSDI	SPEED	TFBUT	NIBUT	LLT	BR/LR	CS	CjS	ST	MGM	TO	TER	MGS	LMA	LME	LMV	ME	MQ	MGYSS
Improved	44%	32%	64%	28%	24%	4%	36%	24%	4%	12%	8%	0%	4%	12%	16%	20%	52%	40%	8%
No difference	4%	0%	0%	0%	8%	0%	16%	8%	24%	16%	16%	4%	0%	4%	0%	0%	4%	8%	0%
Not reported	52%	68%	36%	72%	68%	96%	52%	68%	72%	72%	76%	96%	96%	84%	84%	80%	44%	52%	92%

+ improved, - - worsened, 0 – did not change, NA – not applicable/not included, SRI – self-reported improvement, BR/LR – bulbar redness/limbal redness, CS – corneal staining, CjS – Conjunctival staining, CI – Conjunctival injection, TMH – Tear meniscus height, ST – Schirmer’s test, MGM – Meibomian gland morphology, TO – tear osmolarity, TER – Tear evaporation rate, MGE –number of lower eyelid meibomian glands observed yielding liquid secretion, MGS – Meibomian gland score, LMA – Lid margin abnormality, LME – Lid margin edema, LMV – Lid margin vascularity, ME – Meibum expressibility, MQ – Meibum quality, MGYSS – Meibomian glands yielding secretion score.

their inclusion criteria beyond MGD as IPL has proven to be effective for treating Demodex infestations, which is a highly prevalent condition in elderly patients. Finally, considering the safety profile of IPL, the potential should be investigated for its use on other, hitherto unexplored ocular surface conditions.

## Funding

This research did not receive any specific grant from funding agencies in the public, commercial, or not-for-profit sectors.

## Declaration of competing interest

The authors except RA have no financial/non-financial competing interests. RA is a consultant of Lumenis, Japan.

## Acknowledgments

The authors thank Morten S. Magnø for excellent help in drawing the illustrations, which were produced using Servier Medical Art.

## References

- Nelson JD, Helms H, Fiscella R, Southwell Y, Hirsch JD. A new look at dry eye disease and its treatment. *Adv Ther* 2000;17:84–93.
- Pinho Tavares FD, Fernandes RS, Bernardes TF, Bonfioli AA, Carneiro Soares EJ. Dry eye disease. *Seminars in Ophthalmology*: Taylor & Francis. 2010. p. 84–93.
- Nelson JD, Craig JP, Akpek EK, Azar DT, Belmonte C, Bron AJ, et al. TFOS DEWS II introduction. *Ocul Surf* 2017;15:269–75.
- Messmer EM. The pathophysiology, diagnosis, and treatment of dry eye disease. *Dtsch Arztebl Int* 2015;112:71.
- Lemp MA, Crews LA, Bron AJ, Foulks GN, Sullivan BD. Distribution of aqueous-deficient and evaporative dry eye in a clinic-based patient cohort: a retrospective study. *Cornea* 2012;31:472–8.
- Schaumberg DA, Nichols JJ, Papas EB, Tong L, Uchino M, Nichols KK. The international workshop on meibomian gland dysfunction: report of the subcommittee on the epidemiology of, and associated risk factors for, MGD. *Investig Ophthalmol Vis Sci* 2011;52:1994–2005.
- Nelson JD, Shimazaki J, Benitez-del-Castillo JM, Craig JP, McCulley JP, Den S, et al. The international workshop on meibomian gland dysfunction: report of the definition and classification subcommittee. *Investig Ophthalmol Vis Sci* 2011;52:1930–7.
- Qiao J, Yan X. Emerging treatment options for meibomian gland dysfunction. *Clin Ophthalmol* 2013;7:1797.
- Giannaccare G, Pellegrini M, Sebastiani S, Bernabei F, Roda M, Taroni L, et al. Efficacy of omega-3 fatty acid supplementation for treatment of dry eye disease: a meta-analysis of randomized clinical trials. *Cornea* 2019;38:565–73.
- Thode AR, Lasky RA. Current and emerging therapeutic strategies for the treatment of meibomian gland dysfunction (MGD). *Drugs* 2015;75:1177–85.
- Giannaccare G, Taroni L, Senni C, Scorcio V. Intense pulsed light therapy in the treatment of meibomian gland dysfunction: current perspectives. *Clin Optom* 2019;11:113–26.
- Toyos R, McGill W, Briscoe D. Intense pulsed light treatment for dry eye disease due to meibomian gland dysfunction; a 3-year retrospective study. *Photomed Laser Surg* 2015;33:41–6.
- Husain Z, Alster TS. The role of lasers and intense pulsed light technology in dermatology. *Clin Cosmet Invest Dermatol* 2016;9:29.
- Jiang X, Lv H, Song H, Zhang M, Liu Y, Hu X, et al. Evaluation of the safety and effectiveness of intense pulsed light in the treatment of meibomian gland dysfunction. *J Ophthalmol* 2016;2016:1910694.
- Rong B, Tang Y, Tu P, Liu R, Qiao J, Song W, et al. Intense pulsed light applied directly on eyelids combined with meibomian gland expression to treat meibomian gland dysfunction. *Photomed Laser Surg* 2018;36:326–32.
- Arita R, Fukuoka S, Morishige N. Therapeutic efficacy of intense pulsed light in patients with refractory meibomian gland dysfunction. *Ocul Surf* 2019;17:104–10.
- Li D, Lin SB, Cheng B. Intense pulsed light treatment for meibomian gland dysfunction in skin types III/IV. *Photobiomodul Photomed Laser Surg* 2019;37:70–6.
- Toyos R, Toyos M, Willcox J, Mulliniks H, Hoover J. Evaluation of the safety and efficacy of intense pulsed light treatment with meibomian gland expression of the upper eyelids for dry eye disease. *Photobiomodul Photomed Laser Surg* 2019;37:527–31.
- Piyacorn Y, Kasetsuwan N, Reinprayoon U, Satitpitakul V, Tesapirat L. Efficacy and Safety of Intense Pulsed Light in Patients With Meibomian Gland Dysfunction-A Randomized, Double-Masked, Sham-Controlled Clinical Trial [published correction appears in *Cornea*. 2020 Jul;39(7):e18]. *Cornea* 2020;39(3):325–32. <https://doi.org/10.1097/ICO.0000000000002204>.
- Mandal P, Khan MI, Shah S. Drugs—Do we need them? Applications of non-pharmaceutical therapy in anterior eye disease: a review. *Contact Lens Anterior Eye* 2017;40:360–6.
- Papageorgiou P, Clayton W, Norwood S, Chopra S, Rustin M. Treatment of rosacea with intense pulsed light: significant improvement and long-lasting results. *Br J Dermatol* 2008;159:628–32.
- Prieto VG, Sadick NS, Lloreta J, Nicholson J, Shea CR. Effects of intense pulsed light on sun-damaged human skin, routine, and ultrastructural analysis. *Laser Surg Med* 2002;30:82–5. The Official Journal of the American Society for Laser Medicine and Surgery.
- Vora GK, Gupta PK. Intense pulsed light therapy for the treatment of evaporative dry eye disease. *Curr Opin Ophthalmol* 2015;26:314–8.
- Dell SJ. Intense pulsed light for evaporative dry eye disease. *Clin Ophthalmol* 2017;11:1167.
- Green-Church KB, Butovich I, Willcox M, Borchman D, Paulsen F, Barabino S, et al. The international workshop on meibomian gland dysfunction: report of the subcommittee on tear film lipids and lipid-protein interactions in health and disease. *Investig Ophthalmol Vis Sci* 2011;52:1979–93.
- Kim T, Donnenfeld ED, Holland EJ, Kanellopoulos AJ, Mah FS, Randleman JB, et al. Meibomian gland dysfunction. 2011. p. 1–8.
- Willcox MD, Argüeso P, Georgiev GA, Holopainen JM, Laurie GW, Millar TJ, et al. TFOS DEWS II tear film report. *Ocul Surf* 2017;15:366–403.
- Tamhane M, Cabrera-Ghayouri S, Abelian G, Viswanath V. Review of biomarkers in ocular matrices: challenges and opportunities. *Pharmaceut Res* 2019;36:40.
- Butovich IA. Tear film lipids. *Exp Eye Res* 2013;117:4–27.
- Georgiev GA, Eftimov P, Yokoi N. Structure-function relationship of tear film lipid layer: a contemporary perspective. *Exp Eye Res* 2017;163:17–28.
- Conrady CD, Joos ZP, Patel BC. The lacrimal gland and its role in dry eye. *J Ophthalmol* 2016;2016:1–11.
- Chhadva P, Goldhardt R, Galor A. Meibomian gland disease: the role of gland dysfunction in dry eye disease. *Ophthalmology* 2017;124:S20–6.
- Cwiklik L. Tear film lipid layer: a molecular level view. *Biochim Biophys Acta Biomembr* 2016;1858:2421–30.
- Millar TJ, Schuett BS. The real reason for having a meibomian lipid layer covering the outer surface of the tear film—A review. *Exp Eye Res* 2015;137:125–38.
- Gipson IK. Goblet cells of the conjunctiva: a review of recent findings. *Prog Retin Eye Res* 2016;54:49–63.
- Benitez-del-Castillo JM, Lemp MA. Ocular surface disorders. *JP medical Ltd*; 2013.
- Ding C, Tóth-Molnár E, Wang N, Zhou L. Lacrimal gland, ocular surface, and dry eye. *J Ophthalmol* 2016;2016.
- Bron A, Benjamin L, Snibson G. Meibomian gland disease: classification and grading of lid changes. *Eye* 1991;5:395–411.
- Stern ME, Beuerman RW, Fox RI, Gao J, Mircheff AK, Pflugfelder SC. The pathology of dry eye: the interaction between the ocular surface and lacrimal glands. *Cornea* 1998;17:584–9.
- Brewitt H, Sistani F. Dry eye disease: the scale of the problem. *Surv Ophthalmol* 2001;45(Supplement 2):S199–202.
- Schaumberg DA, Buring JE, Sullivan DA, Dana MR. Hormone replacement therapy and dry eye syndrome. *J Am Med Assoc* 2001;286:2114–9.
- Zegans ME, Anninger W, Chapman C, Gordon SR. Ocular manifestations of hepatitis C virus infection. *Curr Opin Ophthalmol* 2002;13:423–7.
- Colev M, Engel H, Mayers M, Markowitz M, Cahill L. Vegan diet and vitamin A deficiency. *Clin Pediatr* 2004;43:107–9.
- Miljanović B, Trivedi KA, Dana MR, Gilbard JP, Buring JE, Schaumberg DA. Relation between dietary n-3 and n-6 fatty acids and clinically diagnosed dry eye syndrome in women. *Am J Clin Nutr* 2005;82:887–93.
- Nebbio M, Del Regno P, Gharbiya M, Sacchetti M, Plateroti R, Lambiasi A. Analysis of the pathogenic factors and management of dry eye in ocular surface disorders. *Int J Mol Sci* 2017;18:1764.
- Sripasert I, Warren DW, Mircheff AK, Stanczyk FZ. Dry eye in postmenopausal women: a hormonal disorder. *Menopause* 2016;23:343–51.
- Matossian C, McDonald M, Donaldson KE, Nichols KK, MacIver S, Gupta PK. Dry eye disease: consideration for women's health. *J Wom Health* 2019;28:502–14.
- de Paiva CS. Effects of aging in dry eye. *Int Ophthalmol Clin* 2017;57:47.
- Lin JB, Tsubota K, Apte RS. A glimpse at the aging eye. *npj Aging Mech Dis* 2016;2:1–7.
- McCusker MM, Durrani K, Payette MJ, Suchecki J. An eye on nutrition: the role of vitamins, essential fatty acids, and antioxidants in age-related macular degeneration, dry eye syndrome, and cataract. *Clin Dermatol* 2016;34:276–85.
- Rapaport Y, Singer JM, Ling JD, Gregory A, Kohanim S. A comprehensive review of sex disparities in symptoms, pathophysiology, and epidemiology of dry eye syndrome. *Seminars in ophthalmology*: Taylor & Francis. 2016. p. 325–36.
- Al-Saeedi Z, Zimmerman A, Devi Bachu R, Dey S, Shah Z, Baugh R, et al. Dry eye disease: present challenges in the management and future trends. *Curr Pharmaceut Des* 2016;22:4470–90.
- Gomes JAP, Azar DT, Baudouin C, Efron N, Hirayama M, Horwath-Winter J, et al. TFOS DEWS II iatrogenic report. *Ocul Surf* 2017;15:511–38.
- Milner MS, Beckman KA, Luchs JI, Allen QB, Awdeh RM, Berdahl J, et al. Dysfunctional tear syndrome: dry eye disease and associated tear film disorders—new strategies for diagnosis and treatment. *Curr Opin Ophthalmol* 2017;28:3.
- Stapleton F, Alves M, Bunya VY, Jalbert I, Lekhanont K, Malet F, et al. Tfos dews ii epidemiology report. *Ocul Surf* 2017;15:334–65.
- Arita R, Mizoguchi T, Kawashima M, Fukuoka S, Koh S, Shirakawa R, et al. Meibomian gland dysfunction and dry eye are similar but different based on a population-based study: the Hirado-Takushima study in Japan. *Am J Ophthalmol* 2019;207:410–8.
- Mudgil P. Antimicrobial role of human meibomian lipids at the ocular surface.

- Investig Ophthalmol Vis Sci 2014;55:7272–7.
- [58] Knop E, Knop N, Millar T, Obata H, Sullivan DA. The international workshop on meibomian gland dysfunction: report of the subcommittee on anatomy, physiology, and pathophysiology of the meibomian gland. *Invest Ophthalmol Vis Sci* 2011;52:1938–78.
- [59] Raulin C, Greve B, Grema H. IPL technology: a review. *Laser Surg Med* 2003;32:78–87. *The Official Journal of the American Society for Laser Medicine and Surgery*.
- [60] Weijie G, Hongmei L, Wei L. Intense pulsed light therapy. *Photomedicine: Adv Clin Pract* 2017:177.
- [61] Sadick NS, Weiss R. Intense pulsed-light photorejuvenation. *Seminars in cutaneous medicine and surgery*. 2002. p. 280–7.
- [62] Goldman MP. Treatment of benign vascular lesions with the Photoderm VL high-intensity pulsed light source. *Adv Dermatol* 1997;13:503–21.
- [63] Goldberg DJ. Current trends in intense pulsed light. *J Clin Aesthetic Dermatol* 2012;5:45.
- [64] Mühlbauer W, Nath G, Kreitmair A. Treatment of capillary hemangiomas and nevi flammei with light. *Langenbecks Arch* 1976:91–4.
- [65] Anderson RR, Parrish JA. Selective photothermolysis: precise microsurgery by selective absorption of pulsed radiation. *Science* 1983;220:524–7.
- [66] Schmoll M. Treatment of capillary hemangiomas by infrared contact coagulation. *Hautarzt* 1981;32:588–91. *Zeitschrift für Dermatologie, Venerologie, und verwandte Gebiete*.
- [67] Colver GB. The infrared coagulator in dermatology. *Dermatol Clin* 1989;7:155–68.
- [68] Krumrey K. Treatment of naevus flammeus lateralis by infrared contact coagulation. *Z Hautkr* 1984;59:1070–2.
- [69] Babilas P, Schreml S, Szeimies RM, Landthaler M. Intense pulsed light (IPL): a review. *Laser Surg Med* 2010;42:93–104. *The Official Journal of the American Society for Laser Medicine and Surgery*.
- [70] Kent C. Intense pulsed light: for treating dry eye. *Rev Ophthalmol* 2010(November) <https://www.reviewofophthalmology.com/article/intense-pulsed-light-for-treating-dry-eye>.
- [71] Gold MH. Lasers and light sources for the removal of unwanted hair. *Clin Dermatol* 2007;25:443–53.
- [72] Craig JP, Chen YH, Turnbull PR. Prospective trial of intense pulsed light for the treatment of meibomian gland dysfunction. *Invest Ophthalmol Vis Sci* 2015;56:1965–70.
- [73] Liu R, Rong B, Tu P, Tang Y, Song W, Toyos R, et al. Analysis of cytokine levels in tears and clinical correlations after intense pulsed light treating meibomian gland dysfunction. *Am J Ophthalmol* 2017;183:81–90.
- [74] Gao YF, Liu RJ, Li YX, Huang C, Liu YY, Hu CX, et al. Comparison of anti-inflammatory effects of intense pulsed light with tobramycin/dexamethasone plus warm compress on dry eye associated meibomian gland dysfunction. *Int J Ophthalmol* 2019;12:1708–13.
- [75] Rong B, Tang Y, Liu R, Tu P, Qiao J, Song W, et al. Long-term effects of intense pulsed light combined with meibomian gland expression in the treatment of meibomian gland dysfunction. *Photomed Laser Surg* 2018;36:562–7.
- [76] Yin Y, Liu N, Gong L, Song N. Changes in the meibomian gland after exposure to intense pulsed light in meibomian gland dysfunction (MGD) patients. *Curr Eye Res* 2018;43:308–13.
- [77] Ahmed SA, Taher IME, Ghoneim DF, Safwat AEM. Effect of intense pulsed light therapy on tear proteins and lipids in meibomian gland dysfunction. *J Ophthalmic Vis Res* 2019;14:3–10.
- [78] Vigo L, Taroni L, Bernabei F, Pellegrini M, Sebastiani S, Mercanti A, et al. Ocular surface workup in patients with meibomian gland dysfunction treated with intense regulated pulsed light. *Diagnostics* 2019;9.
- [79] Dell SJ, Gaster RN, Barbarino SC, Cunningham DN. Prospective evaluation of intense pulsed light and meibomian gland expression efficacy on relieving signs and symptoms of dry eye disease due to meibomian gland dysfunction. *Clin Ophthalmol* 2017;11:817–27.
- [80] Albietsz JM, Schmid KL. Intense pulsed light treatment and meibomian gland expression for moderate to advanced meibomian gland dysfunction. *Clin Exp Optom* 2018;101:23–33.
- [81] Arita R, Mizoguchi T, Fukuoka S, Morishige N. Multicenter study of intense pulsed light therapy for patients with refractory meibomian gland dysfunction. *Cornea* 2018;37:1566–71.
- [82] Seo KY, Kang SM, Ha DY, Chin HS, Jung JW. Long-term effects of intense pulsed light treatment on the ocular surface in patients with rosacea-associated meibomian gland dysfunction. *Contact Lens Anterior Eye* 2018;41:430–5.
- [83] Choi M, Han SJ, Ji YW, Choi YJ, Jun I, Alotaibi MH, et al. Meibum expressibility improvement as a therapeutic target of intense pulsed light treatment in meibomian gland dysfunction and its association with tear inflammatory cytokines. *Sci Rep* 2019;9:7648.
- [84] Vigo L, Giannaccare G, Sebastiani S, Pellegrini M, Carones F. Intense pulsed light for the treatment of dry eye owing to meibomian gland dysfunction. *JoVE* 2019;Apr 1(146). <https://doi.org/10.3791/57811>.
- [85] Vegunta S, Patel D, Shen JF. Combination therapy of intense pulsed light therapy and meibomian gland expression (IPL/MGX) can improve dry eye symptoms and meibomian gland function in patients with refractory dry eye: a retrospective analysis. *Cornea* 2016;35:318–22.
- [86] Gupta PK, Vora GK, Matossian C, Kim M, Stinnett S. Outcomes of intense pulsed light therapy for treatment of evaporative dry eye disease. *Can J Ophthalmol* 2016;51:249–53.
- [87] Karaca EE, Evren Kemer O, Ozek D. Intense regulated pulse light for the meibomian gland dysfunction. *Eur J Ophthalmol* 2018;30(2):289–92. <https://doi.org/10.1177/1120672118817687>.
- [88] Stonecipher K, Abell TG, Chotiner B, Chotiner E, Potvin R. Combined low level light therapy and intense pulsed light therapy for the treatment of meibomian gland dysfunction. *Clin Ophthalmol* 2019;13:993–9.
- [89] Cheng SN, Jiang FG, Chen H, Gao H, Huang YK. Intense pulsed light therapy for patients with meibomian gland dysfunction and ocular demodex infestation. *Curr Med Sci* 2019;39:800–9.
- [90] Guilloto Caballero S, Garcia Madrona JL, Colmenero Reina E. Effect of pulsed laser light in patients with dry eye syndrome. *Arch Soc Esp Oftalmol* 2017;92:509–15.
- [91] Mejia LF, Gil JC, Jaramillo M. Intense pulsed light therapy: a promising complementary treatment for dry eye disease. *Arch Soc Esp Oftalmol* 2019;94:331–6.
- [92] Zhang X, Song N, Gong L. Therapeutic effect of intense pulsed light on ocular demodicosis. *Curr Eye Res* 2019;44:250–6.
- [93] Hammer KA, Carson CF, Riley TV, Nielsen JB. A review of the toxicity of *Melaleuca alternifolia* (tea tree) oil. *Food Chem Toxicol* 2006;44:616–25.
- [94] Luo X, Li J, Chen C, Tseng S, Liang L. Ocular demodicosis as a potential cause of ocular surface inflammation. *Cornea* 2017;36(Suppl 1):S9–14.
- [95] Post CF, Juhlin E. Demodex folliculorum and blepharitis. *Arch Dermatol* 1963;88:298–302.
- [96] Byun JY, Choi HY, Myung KB, Choi YW. Expression of IL-10, TGF-beta(1) and TNF-alpha in cultured keratinocytes (HaCaT cells) after IPL treatment or ALA-IPL photodynamic treatment. *Ann Dermatol* 2009;21:12–7.
- [97] Taylor M, Porter R, Gonzalez M. Intense pulsed light may improve inflammatory acne through TNF-alpha down-regulation. *J Cosmet Laser Ther* 2014;16:96–103.