

Herpes simplex virus 2 encephalitis in a patient heterozygous for a TLR3 mutation

Timo Hautala, MD, PhD, Jie Chen, PhD, Laura Tervonen, MD, Terhi Partanen, MD, Satu Winqvist, PhD, Johanna Lehtonen, PhD, Janna Saarela, MD, PhD, Minna Kraatari, MD, Outi Kuismin, MD, PhD, Tytti Vuorinen, MD, PhD, Virpi Glumoff, PhD, Pirjo Åström, PhD, Usko Huuskonen, MD, Lazaro Lorenzo, PhD, Jean-Laurent Casanova, MD, PhD, Shen-Ying Zhang, MD, PhD, and Mikko R.J. Seppänen, MD, PhD

Correspondence

Dr. Hautala
timo.hautala@oulu.fi

Neurol Genet 2020;6:e532. doi:10.1212/NXG.0000000000000532

Susceptibility to herpes simplex virus type 1 (HSV-1) encephalitis (HSE-1) in otherwise healthy individuals, in the course of primary infection, can be caused by single-gene inborn errors of Toll-like receptor 3 (TLR3) dependent, interferon (IFN)- α/β -mediated immunity,^{1,2} or by single-gene inborn errors of snoRNA31.³ These variations underlie infections of the forebrain, whereas mutations of *DBRI* underlie infections of the brainstem.³ HSV-2 encephalitis (HSE-2) is typically observed in neonates, albeit also rarely in older children and adults.⁴ Its manifestations include altered level of consciousness, cranial neuropathies or more extensive brainstem encephalitis, hemiparesis, hemisensory loss, and permanent neurologic deficit.⁴ MRI in HSE-2 may show normal findings, nonspecific white matter, orbitofrontal, mesial temporal lobe, or brainstem lesions. Inborn errors of immunity underlying HSE-2 have not been described.

A 40-year-old previously healthy woman had suffered from headache and fever of up to 38°C for 6 days when she suddenly developed aphasia. At hospital admission, her body temperature was 37.1°C, blood pressure was 138/90 mm Hg, and vital signs were normal. She was fully conscious and co-operative but aphasic. Her blood hemoglobin level was low (107 g/L, normal range 117–155 g/L), with normal C-reactive protein level, blood white cell and thrombocyte counts, and negative blood and urine cultures. Acute phase brain CT, CT angiography and contrast enhanced MRI were unremarkable. CSF showed elevated mononuclear (98%) white cell count ($166 \times 10^6/L$; normal $<3 \times 10^6/L$) and high protein concentration (1,192 mg/L; normal range 150–500 mg/L). CSF was positive for HSV-2 and negative for HSV-1 nucleic acid by automated and accredited real-time PCR (artus HSV-1/2 PCR Kits; QIA-symphony SP, Rotor-Gene Q, Qiagen, Hilden, Germany). EEG showed left focal frontotemporal 2 Hz slow wave activity consistent with viral encephalitis (figure). She received IV acyclovir for 21 days with improvement in aphasia. Neuropsychological assessment 1 month later revealed poor word fluency, problems with memory interference, and delayed word list memory. The patient continued to suffer from lassitude and mild depression at least for over 12 months after the acute episode. Her presentation was consistent with International the Encephalitis Consortium diagnostic criteria for encephalitis.⁵ After the acute episode, she developed frequently recurrent *eczema herpeticum* of lower back tested positive for HSV-2 nucleic acid, suggesting recent primary HSV-2 infection. She did not suffer from genital herpes. This was controlled with peroral prophylactic valacyclovir 500 mg twice daily.

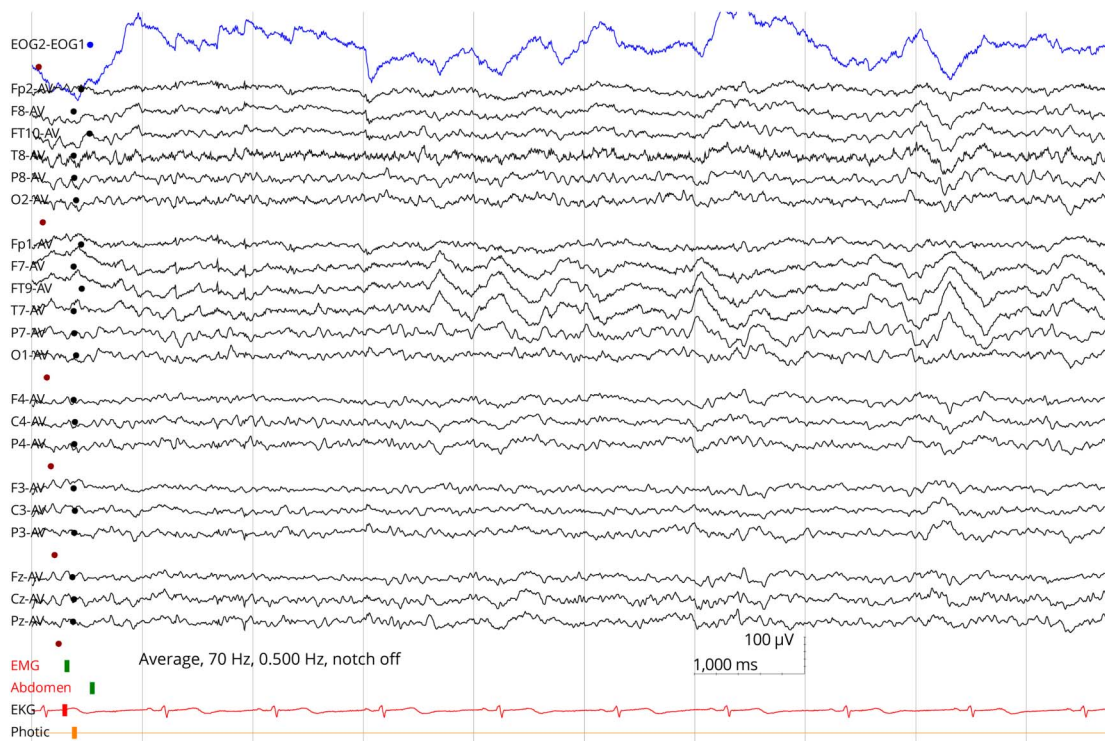
From the Department of Internal Medicine (T.H., T.P.), Oulu University Hospital, Finland; Research Unit of Biomedicine (T.H., V.G., P.Å.), University of Oulu, Finland; St. Giles Laboratory of Human Genetics of Infectious Diseases (J.C., J.-L.C., S.-Y.Z.), Rockefeller Branch, The Rockefeller University, New York, NY; Department of Neurology (L.T., S.W.), Oulu University Hospital; Institute for Molecular Medicine Finland (J.L., J.S.), HiLIFE, and The Folkhälsan Research Center and Medicum (J.L.), University of Helsinki, Finland; Centre for Molecular Medicine Norway (J.S.), University of Oslo, Norway; Department of Clinical Genetics (M.K., O.K.), Oulu University Hospital, Finland; Department of Medical Microbiology (T.V.), Turku University Hospital and Institute of Biomedicine, University of Turku, Finland; Department of Clinical Neurophysiology (U.H.), Oulu University Hospital, Finland; Paris Descartes University (L.L., J.-L.C., S.-Y.Z.), Imagine Institute, Paris; Laboratory of Human Genetics of Infectious Diseases (J.-L.C., S.-Y.Z.), Necker Branch, INSERM UMR 1163, Necker Hospital for Sick Children, Paris; Pediatric Hematology-Immunology Unit (J.-L.C.), Necker Hospital for Sick Children, Paris, France; Howard Hughes Medical Institute (J.-L.C.), New York, NY; Adult Immunodeficiency Unit (M.R.J.S.), Infectious Diseases, Inflammation Center, University of Helsinki and HUS Helsinki University Hospital, Finland; and Rare Disease Center and Pediatric Research Center (M.R.J.S.), Children and Adolescents, University of Helsinki and HUS Helsinki University Hospital, Finland.

Go to [Neurology.org/NG](https://www.neurology.org/NG) for full disclosures. Funding information is provided at the end of the article.

The Article Processing Charge was funded by the authors.

This is an open access article distributed under the terms of the Creative Commons Attribution-NonCommercial-NoDerivatives License 4.0 (CC BY-NC-ND), which permits downloading and sharing the work provided it is properly cited. The work cannot be changed in any way or used commercially without permission from the journal.

Figure EEG shows focal left frontotemporobasal 2 Hz slow wave activity consistent with encephalitis diagnosis



Normal background activity and the patient is awake.

The patient was remitted for immunologic evaluation. Family history was unremarkable; she had no history of general infection susceptibility, autoimmunity, or secondary immunodeficiency. Blood white cell and lymphocyte (CD19⁺ B, CD4⁺ and CD8⁺ T, CD16⁺CD56⁺ NK) counts and percentages of T and B lymphocyte subclasses were normal, suggesting normal maturation. She was positive for anti-HSV2 immunoglobulin G (IgG) and negative for anti-HSV1 IgG. Whole exome sequencing showed a heterozygous rs147431766 *TLR3* (chr4:187005064C>T, ENSG00000164342:ENST00000296795: exon4:c.C2224T:p.L742F) variant, enriched over 23-fold in the Finnish compared with non-Finnish Europeans (allele frequency 0.01621 vs 0.0006819, Genome Aggregation Database; gnomad.broadinstitute.org/). *TLR3* p.L742F variant is in vitro severely hypomorphic based on experiments on *TLR3*-deficient P2.1 fibrosarcoma cell line, and the production of IFN- λ and interleukin-6 in response to *TLR3* activation by poly(I:C) stimulation was impaired in previously tested SV40 immortalized human skin fibroblasts heterozygous for this variation.⁶ She was also found to be positive for TRF1-interacting nuclear factor 2 (*TINF2*) variant p.Y312* (rs201677741) previously associated with Ewing sarcoma. Pathogenic *TINF* variants are associated with autosomal dominant dyskeratosis congenita and pathologic telomere lengths (OMIM 604319). However, her telomere length was within the normal interval compared with healthy controls of similar age. Patient's father had died of

aggressive cholangiocarcinoma, and her mother has had one episode of varicella zoster skin infection. *TLR3* p.L742F and *TINF2* p.Y312* variants were inherited from the mother. Patient's sister had suffered from recurrent laboratory confirmed cutaneous HSV2 infections. Her targeted testing did not reveal *TLR3* p.L742F or *TINF2* p.Y312* variants.

Previous evidence shows that inborn errors in *TLR3*-mediated immune response may explain HSE-1 in a subset of patients.¹⁻³ Our patient suffered an HSE-2 episode associated with impaired *TLR3*-mediated antiviral response. To our knowledge, this is the first report of a genetic mechanism potentially explaining HSE-2 in immunocompetent patients. The *TLR3* p.L742F variant found in our patient is enriched in Finnish population; we can only speculate that this property may associate with HSV-2 CNS infections in Finland.⁷ We emphasize that our report does not prove causality between *TLR3* deficiency and HSE-2 but suggests that *TLR3* signaling defects may need to be contemplated in otherwise healthy HSE-2 patients.

Study funding

No targeted funding reported.

Disclosure

The authors report no disclosures. Go to Neurology.org/NG for full disclosures.

Publication history

Received by *Neurology: Genetics* August 13, 2020. Accepted in final form September 22, 2020.

Appendix Authors

Name	Location	Contribution
Timo Hautala, MD, PhD	University of Oulu, Finland	Patient care and study design
Jie Chen, PhD	Rockefeller University, New York, NY	Laboratory analysis
Laura Tervonen, MD	Oulu University Hospital, Finland	Patient care and diagnostics
Terhi Partanen, MD	Oulu University Hospital, Finland	Study design and analysis
Satu Winqvist, PhD	Oulu University Hospital, Finland	Neuropsychological evaluation
Johanna Lehtonen, PhD	University of Helsinki, Finland	Laboratory analysis
Janna Saarela, MD, PhD	University of Helsinki, Finland	Major role in data analysis
Minna Kraatari, MD	Oulu University Hospital, Finland	Genetic evaluation
Outi Kuismin, MD, PhD	Oulu University Hospital, Finland	Genetic evaluation
Tytti Vuorinen, MD, PhD	University of Turku, Finland	Virologic evaluation
Virpi Glumoff, PhD	University of Oulu, Finland	Immunologic evaluation

Appendix (continued)

Name	Location	Contribution
Pirjo Äström, PhD	University of Oulu, Finland	Laboratory analysis
Usko Huuskonen, MD	Oulu University Hospital, Finland	EEG analysis
Lazaro Lorenzo, PhD	Paris Descartes University, France	Immunologic analysis
Jean-Laurent Casanova, MD, PhD	Rockefeller University, New York, NY	Study design and manuscript preparation
Shen-Ying Zhang, MD, PhD	Rockefeller University, New York, NY	Study design and manuscript preparation
Mikko R.J. Seppänen, MD, PhD	Helsinki University Hospital, Finland	Study design and manuscript preparation

References

1. Zhang SY, Jouanguy E, Ugolini S, et al. TLR3 deficiency in patients with herpes simplex encephalitis. *Science* 2007;317:1522–1527.
2. Lim HK, Seppänen M, Hautala T, et al. TLR3 deficiency in herpes simplex encephalitis: high allelic heterogeneity and recurrence risk. *Neurology* 2014;83:1888–1897.
3. Zhang SY. Herpes simplex virus encephalitis of childhood: inborn errors of central nervous system cell-intrinsic immunity. *Hum Genet* 2020;139:911–918.
4. Berger JR, Houff S. Neurological complications of herpes simplex virus type 2 infection. *Arch Neurol* 2008;65:596–600.
5. Venkatesan A, Tunkel AR, Bloch KC, et al. Case definitions, diagnostic algorithms, and priorities in encephalitis: consensus statement of the international encephalitis consortium. *Clin Infect Dis* 2013;57:1114–1128.
6. Partanen T, Chen J, Lehtonen J, et al. Heterozygous TLR3 mutation in patients with hantavirus encephalitis. *J Clin Immunol* 2020;40:1156–1162.
7. Kupila L, Vuorinen T, Vainionpää R, Hukkanen V, Marttila RJ, Kotilainen P. Etiology of aseptic meningitis and encephalitis in an adult population. *Neurology* 2006;66:75–80.

Neurology[®] Genetics

Herpes simplex virus 2 encephalitis in a patient heterozygous for a TLR3 mutation

Timo Hautala, Jie Chen, Laura Tervonen, et al.

Neurol Genet 2020;6;

DOI 10.1212/NXG.0000000000000532

This information is current as of November 25, 2020

Updated Information & Services	including high resolution figures, can be found at: http://ng.neurology.org/content/6/6/e532.full.html
References	This article cites 7 articles, 1 of which you can access for free at: http://ng.neurology.org/content/6/6/e532.full.html##ref-list-1
Subspecialty Collections	This article, along with others on similar topics, appears in the following collection(s): All Genetics http://ng.neurology.org/cgi/collection/all_genetics All Immunology http://ng.neurology.org/cgi/collection/all_immunology Encephalitis http://ng.neurology.org/cgi/collection/encephalitis Viral infections http://ng.neurology.org/cgi/collection/viral_infections
Permissions & Licensing	Information about reproducing this article in parts (figures, tables) or in its entirety can be found online at: http://ng.neurology.org/misc/about.xhtml#permissions
Reprints	Information about ordering reprints can be found online: http://ng.neurology.org/misc/addir.xhtml#reprintsus

Neurol Genet is an official journal of the American Academy of Neurology. Published since April 2015, it is an open-access, online-only, continuous publication journal. Copyright © 2020 The Author(s). Published by Wolters Kluwer Health, Inc. on behalf of the American Academy of Neurology. All rights reserved. Online ISSN: 2376-7839.

