

Ms. ID BP-2018-OR-0206 revised

Association of left bundle branch block with new onset abnormal wall motion in treated hypertensive patients with left ventricle hypertrophy: the LIFE Echo Sub-study

Ildri M Stokke¹, Zhi Bin Li², Silvana Cicala³, Peter M Okin², Sverre E Kjeldsen¹, Richard B Devereux² and Kristian Wachtell¹

¹University of Oslo, Institute for Clinical Medicine, and Department of Cardiology, Oslo University Hospital, Oslo, Norway; ²Department of Medicine, Weill Cornell Medicine, New York, NY, USA; ³UOC di Cardiologia d'Emergenza con UTIC, Caserta, Italy

Short title: I.M. Stokke ET AL. LBBB and Wall Motion in Hypertension

CONTACT Kristian Wachtell (kristian@wachtell.net), Department of Cardiology, Oslo University Hospital, Ullevaal, N-0407 Oslo, Norway
Tel: +47 22119100, fax: +47 22119181

Word Count: 2800 plus abstract (250), 31 references, 5 tables and 3 figures

Abstract

Aims We aimed to investigate whether left bundle branch block (LBBB) is related to new-onset left ventricle (LV) wall motion abnormalities during treatment in hypertensive patients with electrocardiogram (ECG) defined left ventricular hypertrophy (LVH).

Methods and results 960 patients with essential hypertension and ECG-LVH participating in the LIFE Echo Sub-study were investigated at baseline and annually with echocardiography, during randomized antihypertensive therapy. After excluding patients with LV wall motion abnormalities at baseline and patients developing new-onset LBBB during study time, we investigated 784 patients. The participants with (n=32) and without (n=752) LBBB were similar regarding most baseline variables. Logistic regression models controlling for LV mass index, Framingham risk score, and randomized treatment assignment were used to assess the odds ratio of developing new-onset abnormal LV wall motion on annual follow-up echocardiograms. The likelihood of developing new global LV wall motion abnormalities in patients with LBBB was not higher compared to those without LBBB except at year 5 (p=0.002). The likelihood of developing new segmental LV wall motion abnormalities in patients with LBBB was however higher compared to patients without LBBB after 1 year (OR=3.1, 95% CI=0.7-14.2, p=0.173); 2 years (OR=6.9, 2.1-22.4, p=0.003); 3 years (OR=5.3, 2.0-14.3, p<0.001), 4 years (OR=4.0, 1.6-10.3, p=0.003 and 5 years (OR=4.1, 1.0-16.2, p=0.394) of treatment.

Conclusion Among patients with ECG-LVH, undergoing antihypertensive treatment, the presence of LBBB independently identifies individuals with approximately 3 to 7-fold greater odds of developing new segmental abnormal LV wall motion. These findings suggest that LBBB may be a marker for progressive myocardial disease.

KEYWORDS Blood pressure; hypertension; cardiac disease; echocardiography

Introduction

The presence of left bundle branch block (LBBB) in hypertensive patients with electrocardiographic (ECG) defined left ventricle (LV) hypertrophy (LVH) is associated with worse global and regional LV systolic function and more abnormal LV filling without more severe LVH by echocardiography [1]. Further, LBBB is related to increased risks of cardiovascular mortality, all-cause mortality and congestive heart failure, without a higher risk of myocardial infarction (MI) [1]. However, it is uncertain whether LBBB is also associated with increased risk of developing new segmental and global abnormal LV wall motion that is consistent with MIs, which may not be detected clinically because ECG signs of MI are masked by the presence of LBBB.

Thus, the present study aimed to investigate the association of LBBB with new onset global and segmental LV wall motion abnormalities detected by echocardiography in hypertensive patients with ECG defined LVH participating among the 960 patients in the LIFE Echocardiographic Sub-study.

Material and methods

Participants and study design

The LIFE study design, inclusion and exclusion criteria, baseline characteristics, and the main results of the LIFE study have been previously published [2-4]. Participants in the LIFE study were men and women between 55 and 80 years of age with previously untreated or treated essential hypertension, and ECG defined LVH. All patients had initial sitting diastolic blood pressure 95 to 115 mm Hg or systolic blood pressure 160 to 200 mm Hg after 1-2 weeks of single-blind placebo run-in treatment. Blood pressure and heart rate were measured with standardized techniques with patients seated for 5 min. All participants were asked about alcohol intake, smoking habits, exercise level and employment history. Weight and height

were measured. Past medical history was taken, and a physical examination was performed to detect concomitant disease. Laboratory tests including hemoglobin, serum sodium, potassium, creatinine, uric acid, total HDL cholesterol, and glucose levels were performed in central laboratories [3].

Participants in LIFE were randomly assigned to losartan- or atenolol-based regimens and they were followed through a mean of 4.8 years for the occurrence of a primary composite endpoint of cardiovascular death, stroke or myocardial infarction, as previously reported in detail [4].

The LIFE study protocol was approved by relevant local ethics committees and performed in accordance with the Declaration of Helsinki. The study was overseen by an independent data and safety monitoring board and steering committee. All participants gave written informed consent [4].

Electrocardiographic diagnosis of left ventricle hypertrophy and left bundle branch block

In LIFE, all screening and in-study ECGs had a paper speed of 50 mm/sec and were read at a central laboratory for LVH criteria and Minnesota coding located at the Sahlgrenska University Hospital/Östra in Göteborg, Sweden. Study ECGs were performed at baseline, 6 months and then yearly until year 5. ECG diagnosis of LVH was defined by Cornell voltage-duration product (+ 6 mm in women) >2440 mm x msec or Sokolow-Lyon voltage >38 mm criteria [4-6]. LBBB was defined by the standard ECG criteria (Minnesota code 7.1) as follows: QRS duration of at least 0.120 sec in the presence of sinus or supraventricular rhythm, QS or rS complex in lead V1, and R-wave peak time of at least 0.06 s in leads I, V5, or V6 associated with the absence of a Q-wave in the same lead. New onset LBBB was diagnosed by these criteria in follow-up ECGs. In the current analysis, patients with new-

onset LBBB, detected on ECG at years 1-5, were excluded because of the complexity of their contribution with cross-over status if maintained in statistical analyses.

ECG readings and the echocardiographic sub-study

The LIFE Echocardiographic Sub-study consisted of 960 patients, 11% of the entire LIFE population. Among participants in the echocardiographic sub-study, a total of 932 patients with LBBB diagnostic information from baseline ECG and LV motion assessment on baseline echocardiographic studies were eligible for the current study. After exclusion of 122 patients with LV wall motion abnormalities at baseline and 26 patients developing LBBB during the study, 784 patients constituted the study population (**Figure 1**).

Echocardiographic methods

Echocardiograms were performed annually for 5 years, at 47 selected sites in 7 countries, and video recordings were read blindly at Weill Cornell Medical Center. LV end-diastolic internal dimension and wall thickness were measured based on American Society of Echocardiography recommendations. LV mass was calculated from end-diastolic LV measurements by an anatomically validated formula ($r=0.90$) with good inter-study reproducibility ($r=0.93$). LV wall motion was evaluated by 2D and M-mode echocardiography images. Standard methods were used to calculate LV systolic fractional shortening, ejection fraction and circumferential end-systolic wall stress (ESS) [7]. The method of Teichholz et al [8] was used to calculate stroke volume from linear LV dimensions, as the difference between LV end-diastolic and end-systolic volume [7].

Wall motion assessment

A visual, semi-quantitative method in parasternal long-axis, short-axis, and apical views was used to assess wall motion [9]. The left ventricle was divided into 5 segments at the base and at papillary muscles (anterior and inferior septum; anterior, lateral and inferior walls) and four apical segments (septum, anterior, lateral and inferior walls), according to the Mayo Clinic criteria [10]. Each segment with normal thickening ($\geq 30\%$) was given a score of 4.5; scores of 3.5, 2.5 and 1.5 were given to mildly (wall thickening, 20%-29%), moderately (wall thickening, 10%-19%), and severe (wall thickening, 10%) hypokinetic segments, respectively, and 0 was given to akinetic, and -1 to dyskinetic segments [11]. Normal wall motion was assigned if the wall thickening was preserved in patients with LBBB [11]. If segmental wall motion abnormalities were present in two contiguous segments in a vascular territory, they were considered significant, while global wall motion abnormalities were identified when all segments were hypokinetic [10]. The presence of segmental and global wall motion abnormalities was examined regularly at 1, 2, 3, 4 and 5 years after study enrollment, and the results were reported as dichotomous variables.

Statistical analysis

Data management and analysis were performed using SPSS 25.0 (SPSS, Chicago, Illinois, USA) software by two of the authors (IMS, KW). Results were presented as mean \pm SD for continuous variables and proportions for categorical variables. Pearson's Chi-square test was used to determine differences in categorical variables. Independent-samples T-tests were used to determine differences in continuous variables. Logistic regression models were adjusted for covariates, including randomized treatment assignment, baseline Framingham risk score, and LV mass index measured relevant to the specific ECG evaluation, in order to determine the independent relation of LBBB with new onset global or segmental abnormal LV wall motion. Two-tailed $p < 0.05$ was considered statistically significant.

Results

Patient's characteristics

The present analysis included 784 hypertensive patients with ECG-LVH and ECG characterization of the presence or absence of LBBB on baseline ECG. **Table 1** shows the clinical characteristics of the 32 patients with LBBB and 752 patients without LBBB.

The participants with and those without LBBB were similar in age, gender distribution, body mass index, number of smokers, systolic and diastolic blood pressures, prevalence of diabetes, history of atrial fibrillation and history of cardiovascular diseases (all $p>0.05$). The patients in the LBBB group had a faster heart rate compared to the patients without LBBB ($p<0.05$) at baseline, but at years 1-5 during follow-up there were no significant differences in heart rate or blood pressure between the groups (Table 2).

Global left ventricular systolic function

Global LV systolic function of the patients with and without LBBB is presented in **Table 3**.

The LBBB group had significantly lower global LV systolic function, measured by LV fractional shortening, midwall shortening and LV stroke volume (all $p<0.05$). Moreover, the LBBB group also had non-significant trends toward lower ejection fraction and stress-corrected midwall shortening (all $p>0.05$).

Relation of LBBB to global wall motion abnormalities

The likelihood of developing new global LV wall motion abnormalities in patients with LBBB was not higher compared to those without LBBB after 1-5 years of antihypertensive treatments, without adjustment (all $p>0.05$, **Table 4**). Yet, after adjusting for LV mass index, Framingham risk score and randomized treatment assignment, the odds ratio of developing new global LV wall motion abnormalities was significant for year 5 ($p=0.002$). The fractions

of patients in percent who had developed new global LV wall motion abnormalities yearly in the study are shown in **Figure 2**.

Relation of LBBB to segmental wall motion abnormalities

The likelihood of developing new segmental LV wall motion abnormalities in the patients with LBBB was higher compared to those without LBBB after 1-5 years of antihypertensive treatment, without adjustment ($p < 0.05$ for year 2-5, **Table 5**). After adjusting for LV mass index, Framingham risk score and randomized treatment assignment, the odds ratio of developing new segmental LV wall motion abnormalities, was significant for year 2-4, but not for year 5 ($p = 0.394$). The fractions of patients in percent who had developed new segmental LV wall motion abnormalities yearly in the study are shown in **Figure 3**.

Discussion

Our study shows that among hypertensive patients with ECG-LVH, the presence of LBBB independently identified individuals with 3 to 7-fold higher odds of developing new onset segmental abnormal LV wall motion during 1-5 years of follow-up.

Although it is already known that LBBB increases the cardiovascular and all-cause mortality among hypertensive patients with ECG-LVH [1], the present analysis provides evidence that LBBB also increases the risk of developing new segmental LV wall motion abnormalities among these patients. Analogous to our results, Li et al. [7] reported that hypertensive patients with ECG-LVH and LBBB had decreased wall motion scores in the anterior septum, inferior septum and inferior wall of the LV in cross-sectional comparison with patients without LBBB.

Thus, our results are consistent with the prior observations that LBBB influences LV function and wall motion. Previous analyses have shown that the LV function and wall

motion are altered in several ways in patients with LBBB; this includes reduced global and regional LV systolic function [7], reduced diastolic filling [12], increased LV end-diastolic diameter [13], abnormal early systolic movement of the interventricular septum [14] and reduced regional ejection fraction [15]. However, the potential reasons for these alterations are not clear. Li et al. [7] reported no significant difference in the extent of anatomic LVH in the patients with and the patients without LBBB in their analysis, and therefore it is important to take into account other factors as contributing elements to the detected LV wall motion abnormalities in our longitudinal study.

A potential interesting finding of our study was that the group of patients with LBBB had significantly increased heart rate at baseline compared to patients without LBBB. The fact that the LBBB group also showed parameters of reduced LV systolic function at baseline (reduced fractional shortening, reduced ejection fraction, reduced midwall shortening, stress-corrected midwall shortening and reduced stroke volume), suggests that the increased heart rate at baseline could be a consequence of established reduced LV systolic function. The increased heart rate would increase cardiac oxygen demand, in turn predisposing to further reduction of LV function [16]. This scenario is consistent with a previous observation [17] that every 10 beats/min higher heart rate among hypertensive patients predicted a 45 % increased risk of developing new onset heart failure. Correspondingly, among hypertensive patients, an increased heart rate could reflect subclinical damage to the LV, as a compensation for reduced LV stroke volume [17]. In addition higher heart rate may be associated with coronary plaque disruption, and thus with the development of MIs [18]. It is also known that an increased heart rate is not only related to increased myocardial oxygen demand, but also to decreased myocardial blood flow to areas with coronary vasoconstriction [17]. Hence, higher heart rate in patients with LBBB could precede MIs. However, at follow-up (years 1-5) heart

rate, as well as blood pressure, did not differ between the two groups, arguing against that differences in these variables could easily explain our main findings.

Based on our analysis, one may consider unrecognized MIs to be a part of the reason for the incident LV wall motion abnormalities in hypertensive patients with ECG-LVH and LBBB. Several studies have demonstrated an association between LBBB and the development of MI [5, 13, 19]. One study revealed that LBBB in patients with coronary artery disease is associated with abnormalities in LV contractility [20]. Also, it is well known that MIs often cause wall motion abnormalities [10, 11]. In another analysis in the LIFE echocardiographic sub-study, it was found that MI was 2- to 3-fold more common among hypertensive patients with LVH that had segmental or global wall motion abnormalities, than among similar patients with normal LV systolic function [11]. This could imply that the wall motion abnormalities, in this case, may be a sign of prior MIs. Further, segmental wall motion abnormalities could be identified in up to one-third of patients with possible coronary artery disease but without verified MI [21]. Thus, clinically silent MIs may be an explanation for incident wall motion abnormalities detected in the present study. Up to one-third of all acute MIs present without evident chest pain and may not exhibit diagnostic Q-waves [22]. Thus, it is possible that the wall motion abnormalities identified in the present investigation may represent damage caused by clinically silent and undetected MIs between baseline and follow-up echocardiograms.

Nevertheless, some studies suggest that abnormal ventricular motion develops in patients with LBBB because of other reasons than previous MIs. Grines et al. [15] described that LBBB causes the LV to be activated from the right, thereby delaying the activation of the LV, so that LV systole is delayed and LV diastole shortened. This leads to abnormal movement of the interventricular septum, and subsequently reduced ejection fraction and global altered LV function [15]. Furthermore, Williams et al. [23] showed that segmental wall

motion abnormalities are common in patients with LBBB, where established coronary artery obstruction has been excluded by coronary angiography. They concluded that the observed abnormal wall motion must be caused by altered ventricular activation, instead of by myocardial fibrosis after prior MIs [23]. Similarly, Li et al. [1] reported that LBBB was not associated with an increased probability of developing clinically diagnosed MIs. However, they also proposed that the reason for this could be masking of standard ECG signs of necrosis of the myocardium, because of concomitant LBBB on the ECG [1].

Various studies have described that it can be challenging to diagnose both acute and prior MIs in the presence of LBBB on the ECG [24-26]. In the acute phase, this occurs because patients with LBBB may display ST-segment alterations, due to repolarization delays in the LV [25]. LBBB can also conceal MIs, due to altered depolarization sequence through the first 0.04 s of the QRS complex, which leads to failure to develop characteristic Q-waves [24]. Thus, LBBB can mimic or mask acute MIs. This is critical in patients with acute chest pain that do not have a previous ECG to compare with.

At the same time, the development of segmental wall motion abnormalities among patients with LBBB in our study may help explain the previously reported association of LBBB with increased risk of subsequent heart failure [19, 27-29]. Grines et al. [15] reported that patients with LBBB display reduced contribution of the septal motion to the ejection fraction. Similarly Dhingra et al. [30] observed that a prolonged QRS-interval is correlated with a reduced LV fractional shortening. In another investigation Dhingra et al. [31] demonstrated that in patients without previous MI or heart failure, LBBB is associated with increased LV-mass, LV diastolic diameter, and reduced fractional shortening. As Li et al. [7] concluded in their study, there is an association between LBBB and LV dysfunction in hypertensive patients with ECG-LVH, and this may lead to the subsequent development of congestive heart failure.

There are certain limitations to our study. First of all, it is a post-hoc analysis and our data are limited to elderly patients, mostly Caucasians, with hypertension and left ventricle hypertrophy; though these may be the typical patients with LBBB. Further, coronary angiography was not performed as a part of the study protocol to detect coronary heart disease including MI except in routine clinical work when hospitalized. Our study included a limited number of participants, and it does not show increased odds of developing new global LV wall motion abnormalities. The reason for this could be that segmental LV wall motion abnormalities develop before global wall motion abnormalities; hence our results may detect the early changes with limited power to detect the global changes. We may speculate whether global LV wall motion abnormalities might develop later in the patients with LBBB included in our study, as indicated by the difference that appeared at year 5.

Conclusions

Among hypertensive patients with ECG-LVH, the presence of LBBB independently identifies individuals with 3 to 7-fold-greater odds of developing new abnormal segmental LV wall motion after 1-5 years of systematic antihypertensive therapy. These findings suggest that LBBB may be a marker for sustained and progressive myocardial disease, ischemic or non-ischemic, in hypertensive patients with LVH despite treatment.

Funding: The study was supported by grant COZ-368 from Merck and Co., Inc, West Point, PA, USA.

Conflicts of Interest Statement: Ildri M. Stokke, Zhi Bin Li, Silvana Cicala and Peter M. Okin have no conflict of interest to disclose. Sverre E. Kjeldsen has received honoraria from Bayer, Merck, Sanofi and Takeda. Richard B. Devereux has received honoraria and grant from Merck. Kristian Wachtell has received honoraria from Merck.

References

1. Li Z, Dahlof B, Okin PM, Kjeldsen SE, Wachtell K, Ibsen H, et al. Left bundle branch block and cardiovascular morbidity and mortality in hypertensive patients with left ventricular hypertrophy: the Losartan Intervention For Endpoint Reduction in Hypertension study. *J Hypertens*. 2008;26(6):1244-9.
2. Dahlof B, Devereux R, de Faire U, Fyhrquist F, Hedner T, Ibsen H, et al. The Losartan Intervention For Endpoint reduction (LIFE) in Hypertension study: rationale, design, and methods. The LIFE Study Group. *Am J Hypertens*. 1997;10(7 Pt 1):705-13.
3. Dahlof B, Devereux RB, Julius S, Kjeldsen SE, Beevers G, de Faire U, et al. Characteristics of 9194 patients with left ventricular hypertrophy: the LIFE study. *Losartan Intervention For Endpoint Reduction in Hypertension*. *Hypertension*. 1998;32(6):989-97.
4. Dahlof B, Devereux RB, Kjeldsen SE, Julius S, Beevers G, de Faire U, et al. Cardiovascular morbidity and mortality in the Losartan Intervention For Endpoint reduction in hypertension study (LIFE): a randomised trial against atenolol. *Lancet*. 2002;359(9311):995-1003.
5. Oikarinen L, Nieminen MS, Viitasalo M, Toivonen L, Jern S, Dahlof B, et al. QRS duration and QT interval predict mortality in hypertensive patients with left ventricular hypertrophy: the Losartan Intervention for Endpoint Reduction in Hypertension Study. *Hypertension*. 2004;43(5):1029-34.
6. Oikarinen L, Nieminen MS, Viitasalo M, Toivonen L, Wachtell K, Papademetriou V, et al. Relation of QT interval and QT dispersion to echocardiographic left ventricular hypertrophy and geometric pattern in hypertensive patients. The LIFE study. The Losartan Intervention For Endpoint Reduction. *J Hypertens*. 2001;19(10):1883-91.
7. Li ZB, Wachtell K, Okin PM, Gerds E, Liu JE, Nieminen MS, et al. Association of left bundle branch block with left ventricular structure and function in hypertensive patients with left ventricular hypertrophy: the LIFE study. *J Hum Hypertens*. 2004;18(6):397-402.
8. Teichholz LE, Kreulen T, Herman MV, Gorlin R. Problems in echocardiographic volume determinations: echocardiographic-angiographic correlations in the presence of absence of asynergy. *Am J Cardiol*. 1976;37(1):7-11.
9. Cicala S, de Simone G, Wachtell K, Gerds E, Boman K, Nieminen MS, et al. Clinical impact of 'in-treatment' wall motion abnormalities in hypertensive patients with left ventricular hypertrophy: the LIFE study. *J Hypertens*. 2008;26(4):806-12.

10. Cicala S, Devereux RB, de Simone G, Wachtell K, Gerds E, Boman K, et al. Electrocardiographic and echocardiographic detection of myocardial infarction in patients with left-ventricular hypertrophy. The LIFE Study. *Am J Hypertens*. 2007;20(7):771-6.
11. Palmieri V, Okin PM, Bella JN, Gerds E, Wachtell K, Gardin J, et al. Echocardiographic wall motion abnormalities in hypertensive patients with electrocardiographic left ventricular hypertrophy: the LIFE Study. *Hypertension*. 2003;41(1):75-82.
12. Ozdemir K, Altunkeser BB, Danis G, Ozdemir A, Uluca Y, Tokac M, et al. Effect of the isolated left bundle branch block on systolic and diastolic functions of left ventricle. *J Am Soc Echocardiogr*. 2001;14(11):1075-9.
13. Sundstrom J, Lind L, Andren B, Lithell H. Left ventricular geometry and function are related to electrocardiographic characteristics and diagnoses. *Clin Physiol*. 1998;18(5):463-70.
14. Dillon JC, Chang S, Feigenbaum H. Echocardiographic manifestations of left bundle branch block. *Circulation*. 1974;49(5):876-80.
15. Grines CL, Bashore TM, Boudoulas H, Olson S, Shafer P, Wooley CF. Functional abnormalities in isolated left bundle branch block. The effect of interventricular asynchrony. *Circulation*. 1989;79(4):845-53.
16. Devereux RB, Bang CN, Roman MJ, Palmieri V, Boman K, Gerds E, et al. Left Ventricular Wall Stress-Mass-Heart Rate Product and Cardiovascular Events in Treated Hypertensive Patients: LIFE Study. *Hypertension*. 2015;66(5):945-53.
17. Okin PM, Kjeldsen SE, Julius S, Hille DA, Dahlof B, Devereux RB. Effect of changing heart rate during treatment of hypertension on incidence of heart failure. *Am J Cardiol*. 2012;109(5):699-704.
18. Heidland UE, Strauer BE. Left Ventricular Muscle Mass and Elevated Heart Rate Are Associated With Coronary Plaque Disruption. *Circulation*. 2001;104(13):1477.
19. Li ZB, Cicala S, Wachtell K, Ibsen H, Nieminen MS, Jern S, et al. Abstract 1881: Association of New-Onset Left Bundle Branch Block with Cardiovascular Morbidity and Mortality in Hypertensive Patients with Left Ventricular Hypertrophy: The LIFE study. *Circulation*. 2006;114(Suppl 18):II_373.
20. Hamby RI, Weissman RH, Prakash MN, Hoffman I. Left bundle branch block: a predictor of poor left ventricular function in coronary artery disease. *Am Heart J*. 1983;106(3):471-7.

21. Lewis SJ, Sawada SG, Ryan T, Segar DS, Armstrong WF, Feigenbaum H. Segmental wall motion abnormalities in the absence of clinically documented myocardial infarction: clinical significance and evidence of hibernating myocardium. *Am Heart J.* 1991;121(4 Pt 1):1088-94.
22. Margolis JR, Kannel WS, Feinleib M, Dawber TR, McNamara PM. Clinical features of unrecognized myocardial infarction--silent and symptomatic. Eighteen year follow-up: the Framingham study. *Am J Cardiol.* 1973;32(1):1-7.
23. Williams RS, Behar VS, Peter RH. Left bundle branch block: angiographic segmental wall motion abnormalities. *Am J Cardiol.* 1979;44(6):1046-9.
24. Hurst JW. Electrocardiographic crotchets or common errors made in the interpretation of the electrocardiogram. *Clin Cardiol.* 1998;21(3):211-6.
25. Sgarbossa EB. Value of the ECG in suspected acute myocardial infarction with left bundle branch block. *J Electrocardiol.* 2000;33 Suppl:87-92.
26. Sgarbossa EB, Pinski SL, Barbagelata A, Underwood DA, Gates KB, Topol EJ, et al. Electrocardiographic diagnosis of evolving acute myocardial infarction in the presence of left bundle-branch block. GUSTO-1 (Global Utilization of Streptokinase and Tissue Plasminogen Activator for Occluded Coronary Arteries) Investigators. *N Engl J Med.* 1996;334(8):481-7.
27. Azadani PN, Soleimanirahbar A, Marcus GM, Haight TJ, Hollenberg M, Olgin JE, et al. Asymptomatic Left Bundle Branch Block Predicts New-Onset Congestive Heart Failure and Death From Cardiovascular Diseases. *Cardiology research.* 2012;3(6):258-63.
28. Baldasseroni S, Opasich C, Gorini M, Lucci D, Marchionni N, Marini M, et al. Left bundle-branch block is associated with increased 1-year sudden and total mortality rate in 5517 outpatients with congestive heart failure: a report from the Italian network on congestive heart failure. *Am Heart J.* 2002;143(3):398-405.
29. Schneider JF, Thomas HE, Jr., Sorlie P, Kreger BE, McNamara PM, Kannel WB. Comparative features of newly acquired left and right bundle branch block in the general population: the Framingham study. *Am J Cardiol.* 1981;47(4):931-40.
30. Dhingra R, Pencina MJ, Wang TJ, Nam B-H, Benjamin EJ, Levy D, et al. Electrocardiographic QRS Duration and the Risk of Congestive Heart Failure. *Hypertension.* 2006;47(5):861.
31. Dhingra R, Ho Nam B, Benjamin EJ, Wang TJ, Larson MG, D'Agostino RB, Sr., et al. Cross-sectional relations of electrocardiographic QRS duration to left ventricular dimensions: the Framingham Heart Study. *J Am Coll Cardiol.* 2005;45(5):685-9.

Table 1. Clinical characteristics of participants in the LIFE Echo Sub-Study with or without left bundle branch block (LBBB) at baseline and throughout

Variables	No LBBB (n=752)	With LBBB (n=32)	<i>P-value</i>
Gender (% , women)	43.2	56.3	0.146
Age (years)	65.5±7.0	67.3±7.0	0.167
Height (cm)	169.3±9.4	166.4±8.8	0.091
Weight (kg)	78.0±13.6	73.7±9.5	0.077
Body mass index (kg/m ²)	27.2±4.3	26.7±3.6	0.501
¹ Obesity (%)	22.1	12.5	0.196
Clinic systolic pressure (mmHg)	173.5±21.0	173.3±18.0	0.945
Clinic diastolic pressure (mmHg)	95.3±11.7	92.9±8.5	0.268
Pulse pressure (mmHg)	75.0±15.4	80.1±12.5	0.066
Heart rate (beats/min)	67.7±11.6	72.3±11.3	0.027
Smokers (%)	20.8	18.8	0.782
History of diabetes (%)	10.5	9.4	1.0
History of cerebral vascular accident (%)	4.7	6.3	0.659
History of cardiovascular disease (%)	21.7	31.3	0.201
History of atrial fibrillation (%)	2.4	3.1	0.551
Framingham risk score	22.4±9.3	20.7±9.1	0.301

¹ Obesity defined as body mass index > 30.0 kg/m²

Table 2. Blood Pressure and heart rate in the study groups through years 1-5

Variables	No LBBB (n=752)	With LBBB (n=32)	<i>P-value</i>
Year 1			
Systolic blood pressure (mmHg)	150.2±19.5	151.4±19.7	0.743
Diastolic blood pressure (mmHg)	84.1±10.6	81.1±7.9	0.141
Heart rate (beats/min)	62.4±11.7	62.3±7.8	0.932
Year 2			
Systolic blood pressure (mmHg)	148.6±19.6	152±16.7	0.365
Diastolic blood pressure (mmHg)	83.5±9.9	81.4±7.0	0.266
Heart rate (beats/min)	62.7±12.5	59.6±8.8	0.205
Year 3			
Systolic blood pressure (mmHg)	147.3±19.6	153.6±19.7	0.095
Diastolic blood pressure (mmHg)	82.7±10.0	80.3±8.9	0.206
Heart rate (beats/min)	62.8±14.7	63±9.8	0.964
Year 4			
Systolic blood pressure (mmHg)	145.9±18.6	142.8±13.0	0.427
Diastolic blood pressure (mmHg)	81.7±9.7	78.1±8.0	0.079
Heart rate (beats/min)	62.7±11.4	65.6±13.1	0.249
Year 5			
Systolic blood pressure (mmHg)	146.4±19.2	146.8±18.6	0.948
Diastolic blood pressure (mmHg)	81.9±9.3	81.5±8.9	0.880
Heart rate (beats/min)	62.9±12.4	67.7±11.5	0.171

Table 3. Global left ventricle systolic function in the LIFE Echo Sub-Study patients with or without left bundle branch block (LBBB) at baseline and throughout

	No LBBB (n=752)	With LBBB (n=32)	<i>P-value</i>
Fractional shortening (%)	34.7±4.7	33.0±4.6	0.045
Ejection fraction by 2D/M-mode from Teichholz (%)	63.2±6.6	60.9±6.7	0.054
Ejection fraction from wall motion score sum (%)	63.0±0	63.0±0	NS
Midwall shortening (%)	15.8±1.9	15.1±2.0	0.035
Stress-corrected midwall shortening (%)	98.2±12.4	93.8±11.9	0.056
Pulse pressure/stroke volume (mmHg/ml)	1.0±0.3	1.2±0.3	0.019
Stroke volume by Doppler (ml)	78.7±17.1	69.8±11.7	0.007
Stroke volume by 2D/M-mode from Teichholz (ml)	82.0±16.1	76.5±15.2	0.057

NS = not significant

Table 4. Number of patients with and without left bundle branch block (LBBB) who yearly presented with new onset global left ventricle (LV) wall motion abnormalities in the LIFE Echo Sub-study

Abnormal Global LV wall motion	No LBBB (n=752)	With LBBB (n=32)	Odds Ratio	95% Confidence Interval	Unadjusted <i>P-value</i>	² Adjusted <i>P-value</i>	³ Adjusted <i>P-value</i>
Year 1	18/686	1/29	1.3	0.2-10.3	0.788	0.754	0.968
Year 2	12/638	1/28	1.9	0.2-15.4	0.534	0.486	0.455
Year 3	23/595	1/24	1.1	0.1-8.4	0.940	0.864	0.827
Year 4	4/577	0/21	0.97	0.95-0.98	0.999	0.999	1.0
Year 5	23/278	3/12	3.7	0.9-14.6	0.062	0.057	0.002

² Adjusted for Framingham risk score and randomized treatment assignment

³ Adjusted for changes in LV mass index, Framingham risk score and randomized treatment assignment

Table 5. Number of patients with and without left bundle branch block (LBBB) who yearly presented with new onset segmental left ventricle (LV) wall motion abnormalities in the LIFE Echo Sub-study

Abnormal Segmental LV wall motion	No LBBB (n=752)	With LBBB (n=32)	Odds Ratio	95% Confidence Interval	Unadjusted <i>P-value</i>	⁴ Adjusted <i>P-value</i>	⁵ Adjusted <i>P-value</i>
Year 1	16/686	2/29	3.1	0.7-14.2	0.144	0.131	0.173
Year 2	15/638	4/28	6.9	2.1-22.4	0.001	0.001	0.003
Year 3	35/595	6/24	5.3	2.0-14.3	0.001	0.001	<0.001
Year 4	64/577	7/21	4.0	1.6-10.3	0.004	0.002	0.003
Year 5	21/278	3/12	4.1	1.0-16.2	0.046	0.029	0.394

⁴ Adjusted for Framingham risk score and randomized treatment assignment

⁵ Adjusted for changes in LV mass index, Framingham risk score and randomized treatment assignment

Figure legends

Figure 1

Flowchart of the present study showing selection of participants to be investigated

LBBB=left bundle branch block

Figure 2

Percent of patients who developed new onset abnormal global left ventricle wall motion in 32 patients with left bundle branch block (LBBB) vs. 752 patients who remained without LBBB yearly through 5 years of participation in the LIFE Study

Figure 3

Percent of patients who developed new onset abnormal segmental left ventricle wall motion in 32 patients with left bundle branch block (LBBB) vs. 752 patients who remained without LBBB yearly through 5 years of participation in the LIFE Study

Figure 1

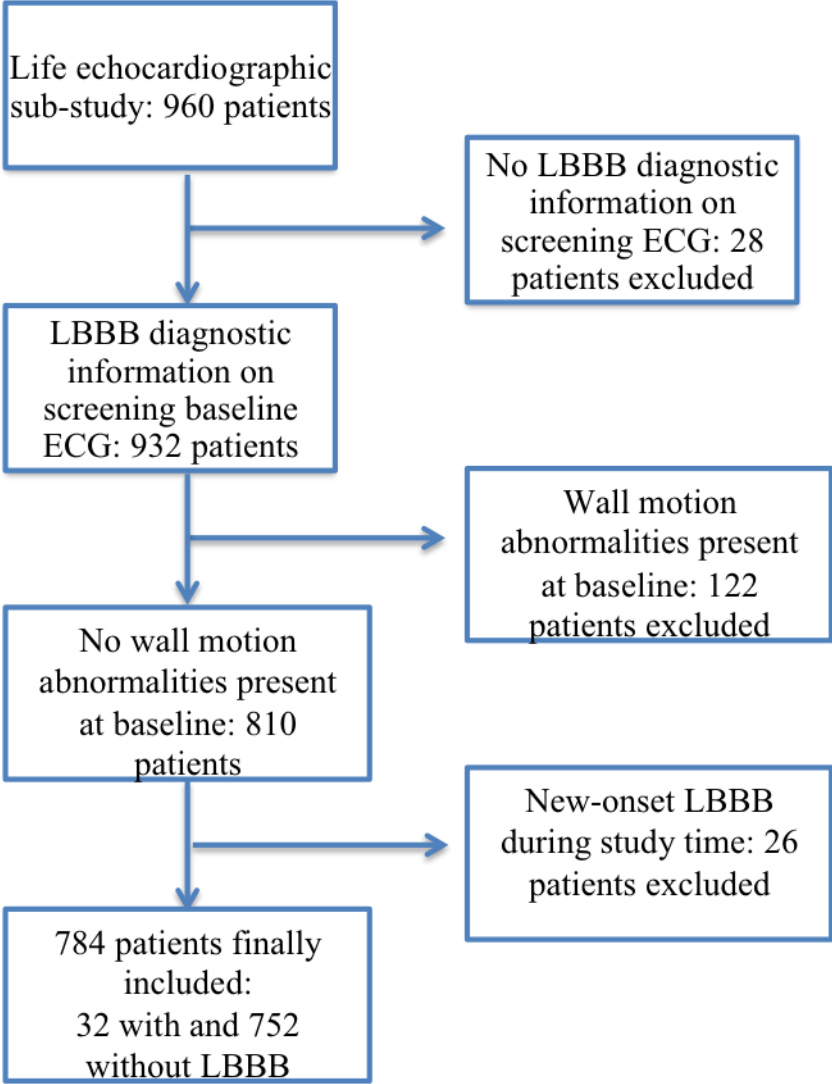
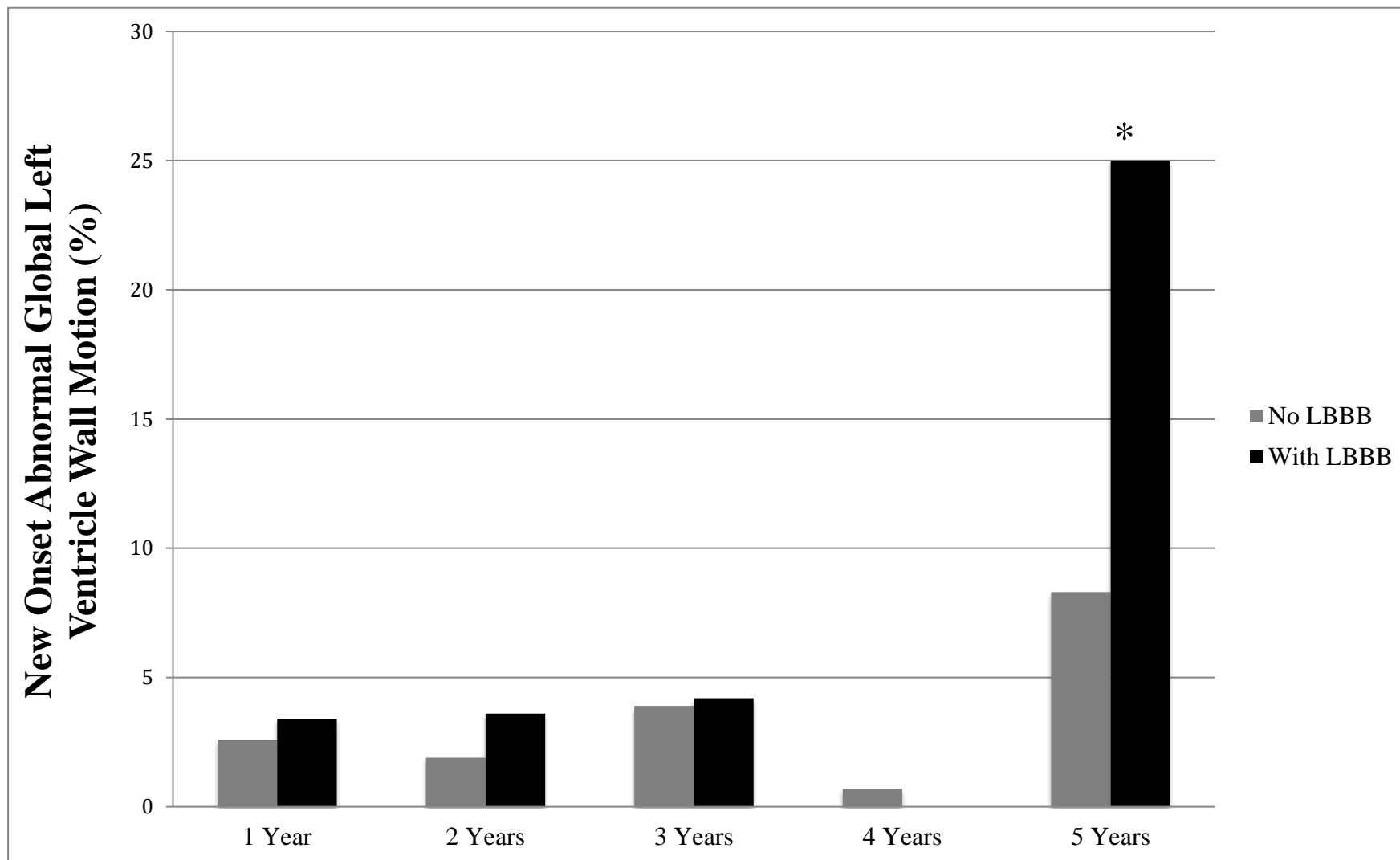
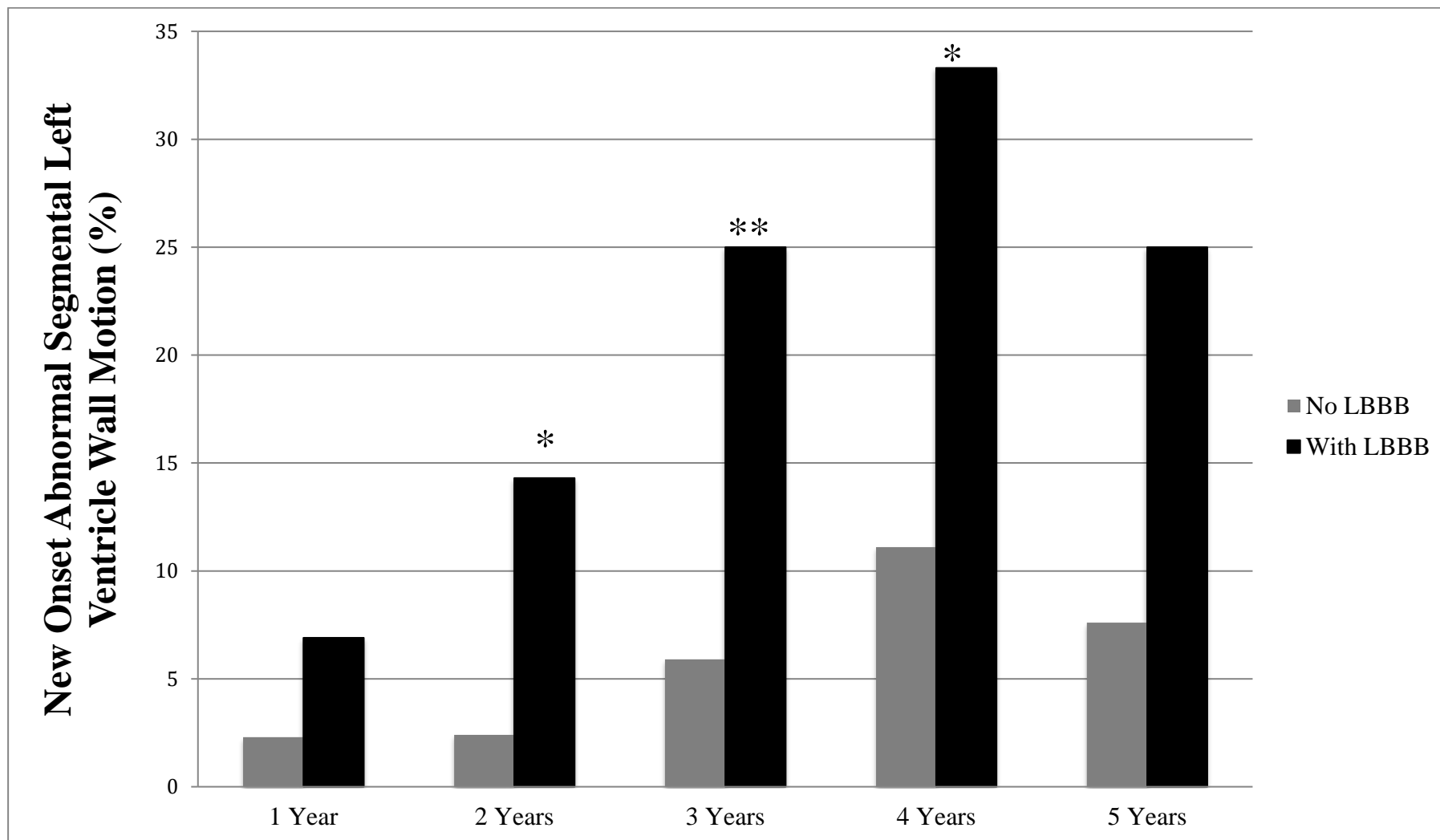


Figure 2



* P-value <0.05.

Figure 3



* P-value <0.05. ** P-value <0.001