


Abnormally Wide Eustachian Tubes Involving the Sphenoid Bone: A Collection

Benedicte Falkenberg-Jensen, MD ; Ketil R. Heimdal, MD, PhD; Hans Erik Høgevoid, MD, PhD;
Greg E. Jablonski, MD, PhD; Bernt J. Due-Tønnessen, MD, PhD; Einar Hopp, MD, PhD

Objectives: To present nine patients with an abnormal widened bony Eustachian tube running anteriorly in the skull base through the sphenoid bone.

Methods: Patients with a particular anomaly in the bony Eustachian tube incidentally found on CT examinations were registered consecutively over a period of four years.

Results: Nine patients had the anomaly, eight unilaterally and one bilaterally. All our patients had additional anomalies involving the outer, middle, and/or inner ear.

Conclusion: The consequences of this anomaly remain unknown, but the presence of the widened, bony ET should increase the awareness for complex temporal bone deformities and vice versa.

Key Words: Eustachian tube, anomaly, skull base, sphenoid bone.

Level of Evidence: 4.

INTRODUCTION

The Eustachian tube (ET) serves as pressure equalizer and mucus drainer for the middle ear. It consists of two portions, one bony and one cartilaginous. Normally, the bony portion is shorter than the cartilaginous and has a funnel shape that narrows towards the isthmus. Developmental anomalies in the cartilaginous ET are described more often than in the bony portion. Since 2011, we have incidentally discovered nine patients with a specific type of developmental anomaly in the bony portion of the ET, where the bony tube is wide and has a more horizontal progression through the skull base before ending in the body of the sphenoid bone (Figs. 1 and 2). As far as we are aware, the condition is previously described in four single-case reports^{1–4} based on computed tomography (CT) findings. It is likely that the

histopathological findings described by Kodama in 1982 were a similar case.⁵ Jovankovicova et al.¹ and Haginomori et al.⁴ both describe the same type of ET anomaly, in a patient with Klippel-Feil syndrome and oculoauriculo-vertebral (OAV) spectrum, respectively.

We have not found any publications on multiple cases or a comparison between cases. In this clinical report, we present 9 individuals with a total of 10 ET anomalies and compare them to each other and those previously described. We also report coinciding anomalies.

MATERIAL AND METHODS

This submission was approved by the institutional review board, and all patients or their guardians gave a written consent. We incidentally discovered nine patients with the same kind of anomaly in the bony portion of the Eustachian tube on CT examinations. The background for referral to a CT scan varied, but none were due to Eustachian tube dysfunction. None of the patients had any comments of tube dysfunction in their medical records. One of the CT scans was a cerebral CT. For the remaining eight, thin slices with bone algorithm were available.

Patients with the combination of a long and wide bony ET that entered the sphenoid bone were included, but no set width was used as inclusion. We recorded gender, age at CT examination, genetic mutations, further temporal bone pathologies including soft tissue structures like the carotid artery, facial nerve and the tensor tympani muscle, as well as craniofacial deformities (Table I).

Patient 1: Male, age 28, who was referred to the ENT (ear, nose and throat) department due to mixed hearing loss bilaterally. He had no known genetic disorder or syndromic appearance.

CT of the temporal bone showed bilateral long, wide bony ET entering the body of the sphenoid bone.

Patient 2: Male, age 10, who was referred to the Norwegian National Unit for Craniofacial Surgery due to medical and dental issues caused by his right-sided hemifacial microsomia. He was diagnosed with OAV spectrum, with unilateral typical

This is an open access article under the terms of the Creative Commons Attribution-NonCommercial-NoDerivs License, which permits use and distribution in any medium, provided the original work is properly cited, the use is non-commercial and no modifications or adaptations are made.

From the Department of Radiology and Nuclear Medicine (B.F.-J., E.H.), the Department of Medical Genetics (K.R.H.), the Faculty of Medicine (B.F.-J., G.E.J.), the Department of Plastic and Reconstructive Surgery (H.E.H.), the Department of Otolaryngology, Head and Neck Surgery (G.E.J.), the Department of Neurosurgery (B.J.D.-T.), and the Department of Radiology and Nuclear Medicine (E.H.), and the Norwegian National Unit for Craniofacial Surgery (B.F.-J., K.R.H., H.E.H., B.J.D.-T.), Oslo University Hospital, Oslo, Norway.

Editor's Note: This Manuscript was accepted for publication 3 March 2018.

This project has not received any funding, and the authors have nothing to disclose.

Our findings were presented as an electronic exhibition at ASHNR 51st Annual Meeting, Las Vegas, Nevada, September 15–20, 2017.

Send correspondence to Benedicte Falkenberg-Jensen, MD, Department of Radiology and Nuclear Medicine, Rikshospitalet, Oslo University Hospital, Sognsvannsveien 20, 0372 Oslo, Norway. Email: bfalke@ous-hf.no

DOI: 10.1002/liv2.158

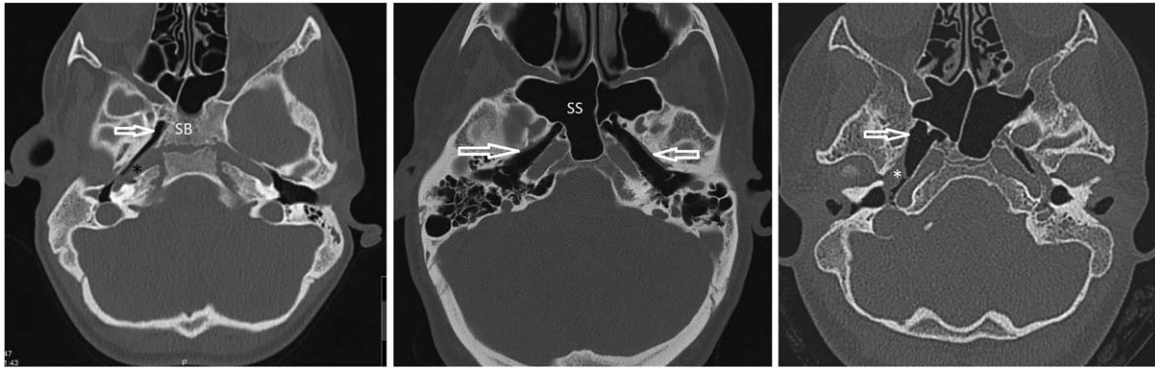


Fig. 1. Left: Axial image of patient no. 2 demonstrates one of the narrower variants in the group (arrow). Note the distance between the ET (Eustachian tube) variant and the sphenoid sinus, indicating that the pneumatization of the ET is independent of the sphenoid sinus. Dehiscence to carotid artery (black asterisk). Middle: Axial image of patient no. 1 with bilateral anomalies (arrows). Right: Axial image of patient no. 4, demonstrating one of the widest ET variants (arrow) in our group. There is a soft tissue mass representing a cholesteatoma (white asterisk). SS = sphenoid sinus; SB = sphenoid bone.

findings. CT of the temporal bone revealed unilateral anomaly with long wide, bony ET entering sphenoid bone on the right side. Ipsilateral external auditory canal (EAC) atresia was present.

Patient 3: Male, age 15, who was referred to the Norwegian National Unit for Craniofacial Surgery due to medical and dental issues caused by his hemifacial microsomia.

CT of the head and face showed unilateral anomaly with long, wide bony ET entering sphenoid bone, left side. Ipsilateral EAC atresia was present. He was later diagnosed with bilateral OAV, with a typical spectrum where the left side was most severely affected.

Patient 4: Female, age 8, who was referred to CT examination of the temporal bone due to cholesteatoma. CT of the temporal bone showed unilateral anomaly with long, very wide (7–12 mm) bony ET entering sphenoid bone on the right side.

In addition, she had unilateral auricular deformities and skin tags, but no facial asymmetry, and was not given a syndrome diagnosis

Patient 5: Female, age 15, who was referred due to EAC atresia. CT temporal bone showed unilateral anomaly with a long, wide bony ET entering sphenoid bone, and a wide pneumatized communication to epipharynx on the left side. She was diagnosed with OAV spectrum, with anomalies on the left side.

Patient 6: Male, age 17, referred to the Norwegian National Unit for Craniofacial Surgery due to facial asymmetry. CT of the face and temporal bone showed unilateral anomaly with long, wide bony ET entering the sphenoid bone on the right side, which communicated with pneumatized cells in the petrous apex. He was later diagnosed with OAV spectrum, with anomalies on the right side.

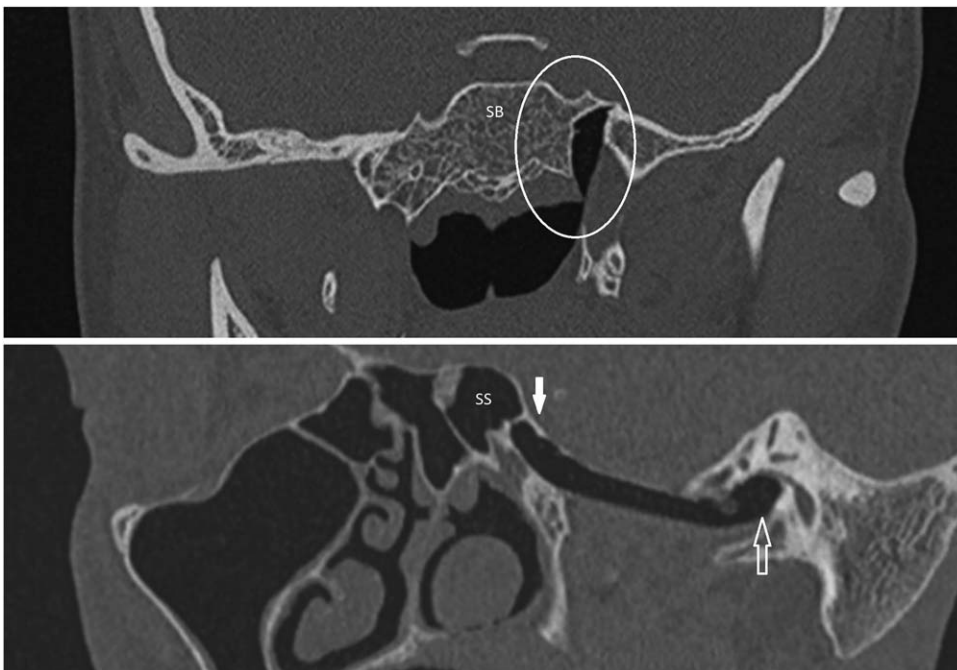


Fig. 2. Top: Coronal image of patient no. 5 demonstrating the ventral end of the abnormal bony ET communicating with a short, vertical soft tissue tube, which opens to the epipharynx (ellipse). Bottom: An oblique sagittal image of patient no. 3 demonstrating the horizontal course of the ET between the middle ear (open arrow) and the sphenoid bone (full arrow). SS = sphenoid sinus; SB = sphenoid bone.

TABLE I.
Wide, Bony Eustachian Tube Anomaly: Patient Characteristics and Coinciding Temporal Bone Findings.

Patient no.	Gender	Age at CT (yrs.)	Outer ear anomaly	EAC atresia	Middle ear anomaly	Inner ear anomaly	Absent t. tympani	Carotid dehiscence	Max. ET width (mm)	Min. ET width (mm)	Syndrome
1	M	28	-	-	+	+	+	+	6	6	-
2	M	10	+	+	+	+	+	+	4	3	OAV
3	M	15	+	+	+	+	+	+	6	2	OAV
4	F	8	-	-		+	+	-	12	7	-
5	F	15	+	+	+	-	+	-	4	1	OAV
6	M	17	+	+	+	+	+	-	5	3	OAV
7	F	0	+	+					3	1	OAV
8	F	31	+	+	+	+	+	-	4	1	OAV
9	M	26	+	-	+	+	+	-	7	3	OAV
Published reports											
Jovankovičová ¹	M	2	+	+	+	+			6		Klippel Feil
Haginomori ⁴	NA	NA	+		+	+		+	7		+
Khan ²	F	61	+	+	-	-			5		Likely OAV
Bosschaert ³	M	17									-

Summary of patient characteristics and coinciding findings in our patient group and the previously published cases. CT = computed tomography; EAC = external acoustic canal; ET = Eustachian tube; OAV = oculo-auriculo-vertebral spectrum.

Patient 7: Female, age 11 months. The clinical background for CT is unknown, but it was performed as a cerebral CT. It shows a unilateral anomaly with a long, wide bony ET entering sphenoid bone on the left side. This was an incidental finding on a CT of the head, hence the ET is not fully captured. The patient had EAC atresia and was later diagnosed with OAV-spectrum with typical anomalies on the left side.

Patient 8: Female, age 31. Referred to CT of the temporal bone due to EAC atresia. CT showed unilateral anomaly with long, bony ET entering sphenoid bone on the right side. She was later diagnosed with unilateral OAV spectrum.

Patient 9: Male, age 26. Referred to the Norwegian National Unit for Craniofacial Surgery due to medical and dental issues caused by his hemifacial microsomia.

CT of the temporal bone demonstrated unilateral anomaly with long, bony ET entering sphenoid bone on the left side, without a visible middle ear cavity. The patient was later diagnosed with unilateral OAV spectrum, with anomalies on the left side.

RESULTS

Detailed findings are summarized in Table I, combined with findings reported in former single case presentations. In short, all nine patients had a long, wide, pneumatized bony portion of the Eustachian tube with a horizontal progression from the hypotympanon to the sphenoid bone.

The ET entered the sphenoid bone dorsal or lateral to the sphenoid sinus, but we found no visible communication between the ET and the sinus.

There was a widening at the sphenoid end, giving the tube a visual resemblance to the native Australian musical instrument Didgeridoo. The narrowest point measured in the axial plane varied from 1 to 7 mm (\bar{x} = 3.0 mm) The widest diameter varied between 3 and 12 mm (\bar{x} = 5.7 mm).

One patient had yet to develop the sphenoid sinus, indicating that the anomaly and its ventilation is independent of the pneumatization of the sphenoid sinus.

DISCUSSION

This series of cases illustrates a scarcely reported skull base anomaly of widened, partly bony ET traversing both the temporal and sphenoid bones. Certain common features are demonstrated. All but one individual are unilaterally affected. Khan reports normal findings in the middle and inner ear and Bosschaert reports normal micro-otoscopy of the middle ear, while all our and the rest of the published cases occur in combination with additional, ipsilateral temporal bone anomalies. However, there is considerable variation between the cases. Presence of EAC atresia is inconstant. Nine of 13 individuals are affected with syndromic deformities.

In all reported cases, the widened, bony ET is aerated, although incomplete opacification occurs. No wall defect between the tube and the sinus was found in our group. Thus, air communication for most cases must be via the pharynx, and for many a slit-like opening between pharynx and the bony ET is visible. We postulate that such an opening is the main rule in this anomaly, although not necessary. Khan published an exception a completely bony and patent left ET that originated from the middle ear and communicated directly with the left sphenoid sinus, excluding the communication to pharynx.

In some of the present and historical cases the ET function must have been sufficient for the tympanic cavity to develop. In the cases with underdeveloped tympanic cavities, one can speculate whether the tympanic hypoplasia has been partly caused by ET malfunction during development.

Table I illustrates the variety of different deformities associated with the widened, bony ET. Both OAV spectrum and Klippel-Feil syndrome represent conditions with a considerable interindividual variation. The ET malformation is also reported in completely non-syndromic individuals.

The widened bony ET coincides with different other anomalies with differing embryological origin, indicating a complex background.

We found seven out of nine cases to be associated with the OAV spectrum of disease, hinting to a possible common etiology. The OAV diagnosis has been set by experienced clinicians in all cases, noting that no diagnostic criteria have been firmly established.⁶ None of the cases from the present series have been genetically tested, demonstrating that the clinicians have perceived all cases as typical. These considerations do not speak for a specific, germline, genetic cause to the ET malformation. Eight out of nine cases, and all cases in OAV patients, were unilateral and located on the side most affected by OAV, consistent with a localized cause, such as for instance a local vascular disturbance in development or a mosaic mutation.

CONCLUSION

In this clinical report, we have demonstrated the features of nine individuals with a widened, bony ET, together with four single case reports. This ET deformity is clearly detected on CT examination, especially because of the characteristic air filling. The clinical consequences

are unknown, both regarding ET function and risk for disease. However, when present, the malformation should be pointed out before any temporal bone or skull base surgery. The malformation usually coincides with other malformations, and when found should increase the awareness for other temporal bone deformities.

BIBLIOGRAPHY

1. Jovankovicova A, Jakubikova J, Durovcikova D. A case of Klippel-Feil syndrome with congenital enlarged Eustachian tube. *Intl J Pediatr Otorhinolaryngol* 2012;76(4):596–600.
2. Khan AS, Pilavakis Y, Batty V, Harries PG, Salib RJ. Eustachian tube communicating with sphenoid sinus: report of a novel anatomical variant. *Surg Radiol Anat* 2016;39(4):461–465.
3. Bosschaert P, Hiel AL, Vilain J. Eustachian tube lumen opening into an abnormally pneumatized sphenoid bone. *JBR-BTR* 2012;95(3):175.
4. Haginomori S, Nonaka R, Hoshijima H, et al. Enlarged bony portion of the eustachian tube in oculoauriculovertebral spectrum. *Otol Neurotol* 2003; 24(6):961–962.
5. Kodama A, Sando I, Myers EN, Hashida Y. Severe middle ear anomaly with underdeveloped facial nerve. A temporal bone histopathologic case report. *Arch Otolaryngol* 1982;108(2):93–98.
6. Heike CL, Luquetti DV, Hing AV. Craniofacial Microsomia Overview. In: Adam MP, Ardinger HH, Pagon RA, et al., eds. *GeneReviews(R)*. Seattle: University of Washington, Seattle; 2014.