

The role of femoral offset and the abductor lever arm in minimally invasive total hip arthroplasty

Filip Bjørdal



Prosjektoppgave ved det medisinske fakultet

UNIVERSITETET I OSLO

04.10.2013

The role of femoral offset and the abductor lever arm in minimally invasive total hip arthroplasty

Abstract

When placing the components during THA the goal is to restore the optimal biomechanics of the hip. Evidence suggests that correct placement of the components plays an important role in order to prevent impingement, provide optimal conditions for the abductor muscles and minimize polyethylene wear. The aim of this study was to clarify the clinical effect of increasing the abductor lever arm in minimally invasive total hip arthroplasty.

We compared the abductor lever arm of the operated hip to the lever arm of the contralateral native hip on radiographs in 148 patients following THA. The patients were divided into two groups based on whether they kept their anatomical lever arm or had an increase in the lever arm. The clinical outcome was assessed using Hip Osteoarthritis Outcome Score (HOOS), Harris Hip Score and UCLA activity score. Evaluations took place at 6 weeks, 4 months and 1 year postoperatively.

Patients who kept their anatomical lever arm did not experience a significantly better clinical outcome than the patients who had an increased abductor lever arm.

The results of this study suggest that an increase in the abductor lever arm does not have detrimental effects on the clinical outcome after THA. To avoid the potential negative effects of a diminished lever arm, the surgeon should aim for an equal or slightly increased lever arm.

Introduction

Total hip arthroplasty is a well-established treatment in patients suffering from arthritic disease of the hip [1]. By replacing the degenerative joint with a prosthetic stem and cup one seeks to restore the normal anatomy of the joint. The goal is to reduce pain and improve function. However, several controversies remain, one of which is the optimal placement of the components [2-4].

When placing the components during THA, the goal is to restore the optimal biomechanical forces of the joint. In order to do so, it has been considered important to medialize the acetabulum, which places the center of rotation closer to the body axis [5]. By doing so the lever arm between the COR and the body weight axis is shortened, providing better mechanical conditions for the abductor muscles of the hip [6]. However, by medializing the cup there is a risk of reducing the global offset. It is therefore considered important to compensate with an equivalent increase in the femoral offset to ensure the biomechanical benefits [6-8]. However, when increasing the femoral offset, there is an inherent risk of exaggerated compensation, which may lead to increased tension on the abductor muscles. We have not been able to find any literature investigating the clinical consequences of an overcorrection of the femoral offset.

The aim of this study was to investigate any correlation between a change in lever arm of the abductor muscles and clinical outcome, including possible consequences of an exaggerated offset. To evaluate this aspect, we investigated if there were any differences in clinical outcome between patients who experienced an increase in lever arm compared to patients who retained an anatomical lever arm.

Materials and methods

Patients and surgery

During 2010 we performed total hip arthroplasty in 166 patients using the direct anterior approach to the hip through the Smith-Petersen interval. 148 of these patients were included in our study group. 15 of the 166 patients were excluded due to previously inserted prosthesis in the contralateral hip, 3 were excluded due to a decrease in the abductor lever arm beyond 5 mm. The study population consisted of 51 men and 97 women with a mean age of 67.7 ± 10.9 years. Mean body mass index was 27.0 ± 4.3 (Table 1). All patients were followed and assessed with Harris hip score, UCLA activity score and Hip Disability and Osteoarthritis Outcome Score (HOOS) with the added dimensions Walking Ability and Recreational Ability. Evaluations took place at 6 weeks, 4 months and 1 year postoperatively.

HOOS is a patient-administered questionnaire where the patient assesses 5 subscales (pain, symptoms, activity of daily living, sport and recreational function and hip related quality of life) regarding their hip and associated problems. The last week is taken into account and a normalized score is calculated for each subscale, where 100 indicate no symptoms and 0 represents extreme symptoms [9].

The UCLA activity score is a scale ranging from 1 to 10 where the patient is supposed to indicate his or her most appropriate activity level. 1 is defined as “Wholly Inactive, dependent on others, and cannot leave residence”, while 10 is defined as “Regularly participates in impact sports”.

The data were studied retrospectively. The patients were divided into two

groups based on the difference in abductor lever arm between the operated hip and the contralateral native hip. Group 1 consisted of patients with a lever arm restored to within 5 mm of the native lever arm, while group 2 comprised patients with a lever arm increased to greater than 5 mm of the native lever arm. The two groups were compared in regards to all parameters of Harris Hip Score and HOOS.

Table 1. Patient demographics

Demographic	Study population	Group 1 (ALA increase/decrease \leq 5 mm)	Group 2 (ALA increase $>$ 5 mm)
Number of patients	148	56	92
Gender (male/female)	51/97	27/29	24/68
Age (years)*	67.7 \pm 10.9	66.2 \pm 13.0	68.6 \pm 9.3
Body mass index (kg/m ²)*	27.0 \pm 4.3	27.2 \pm 4.5	26.8 \pm 4.3

* Values are expressed as mean \pm standard deviation

The THA was performed through the anterior approach on a fracture table. The method has been thoroughly described by several authors [10, 11]. In the supine position on a fracture table, an operative field of 10 x 20 centimeters was prepared. The skin was covered with iodine prepared plastic foil and an incision was made starting two fingerbreadths lateral and distal to the superior anterior iliac spine. The incision extended 9 – 11 centimeters parallel to the iliotibial band. The fascia lata was exposed and incised in line with the skin incision, and the lateral circumferential vessels were cauterized. The hip capsule was then opened using a U-shaped incision based laterally and the flap lifted using a suture. A Charnley retractor was then placed between the capsular flap and the rectus femoris and iliacus muscles, which helped protect the tensor fascia latae. An osteotomy was performed in situ and the femoral head was extracted. The acetabulum was then prepared for an uncemented press-fit cup that was inserted

using straight or curved instruments. The femur was brought into the operative field by external rotation, extension and adduction, and the remains of the posterolateral capsule were removed to facilitate exposure. Multiple broaches were then used to determine the size and position of the femoral component. Trial reduction and fluoroscopy facilitated the correct choice of implant and position of the femoral component, especially in regard to determining leg length. After final implantation of the component, the wound was thoroughly irrigated and closed using resorbable sutures in the fascia lata, the subcutaneous tissue and the intracutaneous tissue.

All patients were mobilized on the day of surgery. We recommended partial weight bearing as needed and did not impose any restrictions on activities. The implants used were an SL+ MIA stem and a Reflection press fit cup. The SL+ MIA stem was available in a high offset version as well as in a normal offset version. In this study, we have exclusively used the high offset stem.

Radiological assessment

A standardized anteroposterior pelvic radiograph was performed in all patients following the THA. The abductor lever arm (ALA) was defined as the distance from the center of the hip joint to the line of action of the abductor muscles (Fig. 1). The lever arm and the line of action should form a 90-degree angle. The lever arm was then measured in the contralateral hip and compared to the operated side.

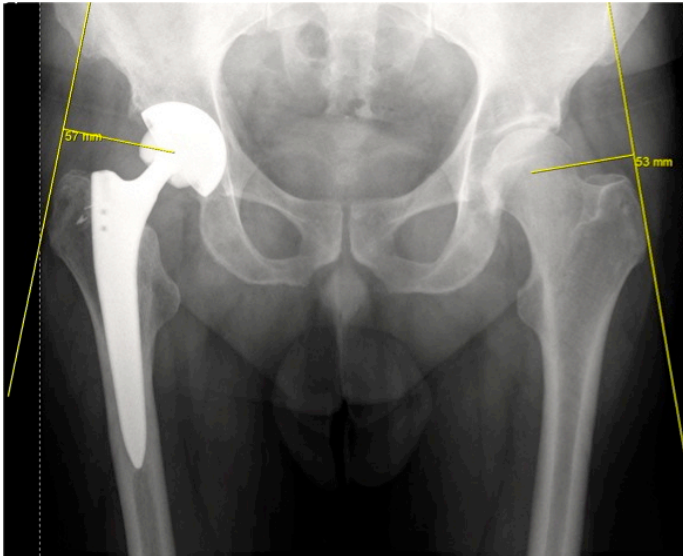


Fig 1. Radiograph demonstrating the abductor lever arm, defined as the distance from the center of rotation to the line of action of the abductor muscles.

Statistical analysis

Statistical analysis was performed using Microsoft Excel. Data were expressed as mean \pm standard deviation (SD). Comparisons were made using the unpaired Student's t-test. A p-value of less than 0.05 was considered to be significant.

All patients received oral and written information about the nature and purpose of the hospital registry and approved the use of anonymous data for research purposes. The study was approved by the hospital research committee and the Norwegian Social Science Data Services (NSD).

Results

Radiological result

In our sample we found a native abductor lever arm of $58.0 \text{ mm} \pm 6.6 \text{ mm}$, whereas the mean lever arm of the operated side was $65.4 \text{ mm} \pm 5.9 \text{ mm}$.

Group 1 consisted of 56 patients with a mean native abductor lever arm of $61.6 \text{ mm} \pm 6.1 \text{ mm}$. The mean lever arm of the operated side was $63.0 \text{ mm} \pm 5.4 \text{ mm}$. 17 of the patients in this group experienced a shortening of the lever arm, whereas 34 had an increase. 5 patients did not experience a difference in lever arm between the two hips (Fig. 2a). The mean difference in lever arm between the contralateral native hip and the operated hip was $1.4 \text{ mm} \pm 3.12 \text{ mm}$.

Group 2 comprised 95 patients with a mean native lever arm of $55.8 \text{ mm} \pm 5.9 \text{ mm}$. The mean lever arm of the operated side was $66.9 \text{ mm} \pm 5.8 \text{ mm}$. These patients had a mean increase in the lever arm of $11.2 \text{ mm} \pm 4.3 \text{ mm}$ (range 6 – 28mm)(Fig. 2b).

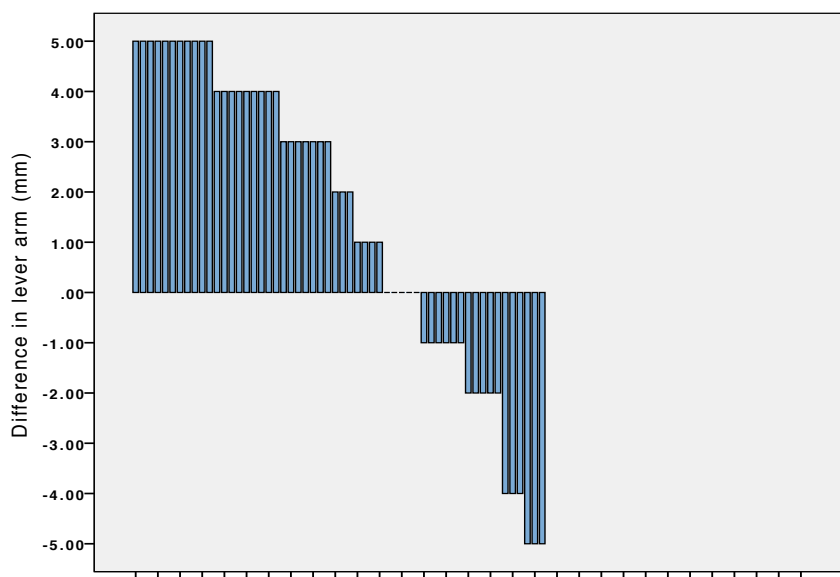


Fig 2a. Difference in abductor lever arm distributed among patients in group 1.

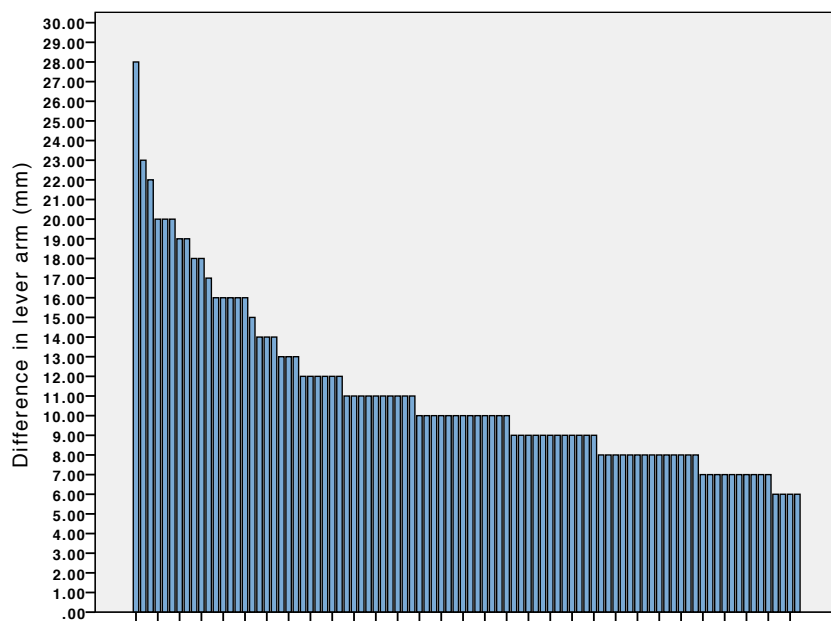


Fig 2b. Difference in abductor lever arm distributed among patients in group 2.

Clinical outcome

Patients whose lever arm was restored to within 5 mm of the contralateral native hip did not experience a significantly better clinical outcome than the patients with a greater postoperative increase in lever arm (Fig. 3). An analysis of Harris Hip Score and HOOS preoperatively did not show any statistically significant differences between the two groups. After one year of follow-up there were still no statistically significant differences in any parameters of HOOS or Harris Hip Score between the two groups (Table 2).

Table 2. Clinical outcome 1 year after THA.

	Group 1 (ALA increase/decrease ≤ 5 mm) Mean ± SD	Group 2 (ALA increase > 5 mm) Mean ± SD	P-value
HOOS - PAIN	86.0 ± 19.0	91.3 ± 12.6	0.16
HOOS - SYMPTOM	86.7 ± 18.9	90.0 ± 13.0	0.37
HOOS - ADL	85.1 ± 20.1	87.8 ± 16.0	0.50
HOOS - SPORT/RECREATION	74.5 ± 27.5	73.4 ± 22.7	0.85
HOOS - QUALITY OF LIFE	78.1 ± 25.0	79.4 ± 21.9	0.81
HOOS - ACTIVITY 1a	3.7 ± 1.8	3.9 ± 1.5	0.69
HOOS - ACTIVITY 1b	4.5 ± 1.5	4.2 ± 1.4	0.48
HOOS - ACTIVITY 2	5.9 ± 2.4	5.8 ± 2.3	0.84
HARRIS HIP SCORE	94.1 ± 9.7	94.4 ± 10.6	0.86

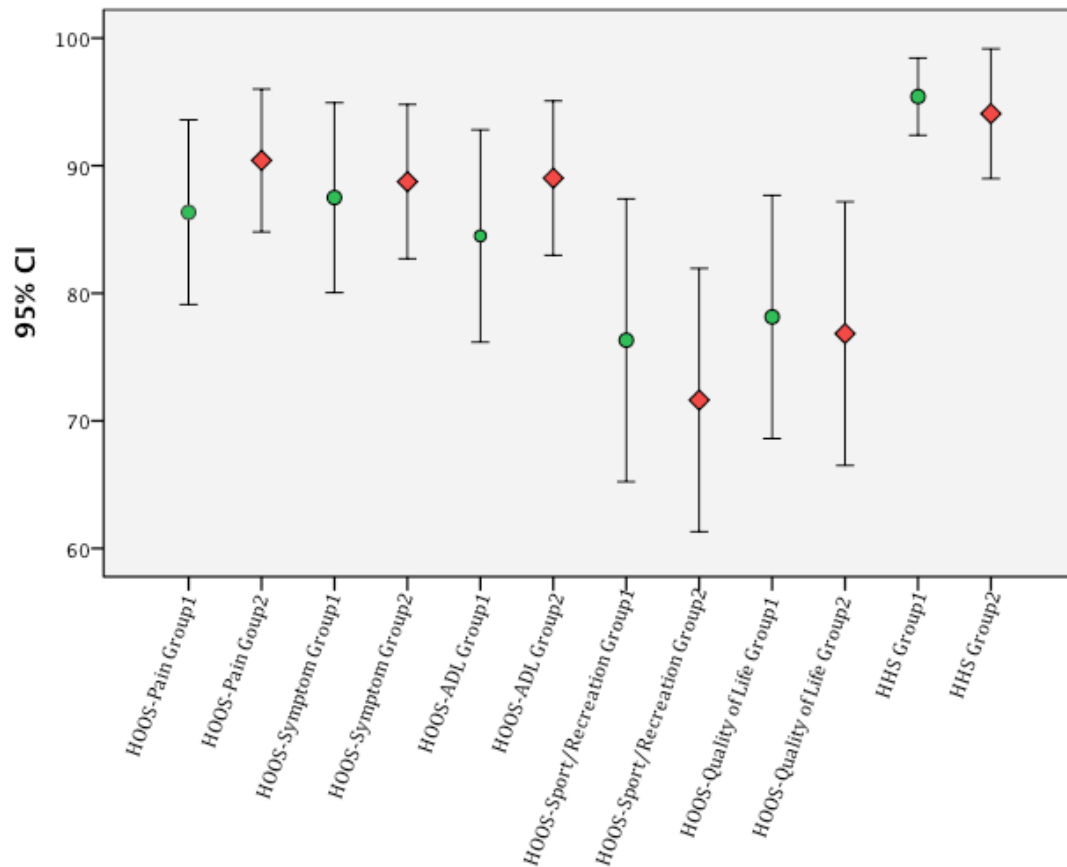


Fig 3. Error bars showing 95% confidence intervals for the mean of HOOS subgroups and Harris Hip Score among group 1 (green, circular) and group 2 (red, diamond). The two groups display overlap in all clinical parameters.

Discussion

Our data showed no significant difference in clinical outcome between the two groups at any of the follow-ups during the first year after operation. This suggests that an increase in abductor lever arm does not have a large impact on the clinical outcome as measured by HOOS or Harris Hip Score during the first year after THA.

There is evidence that offset plays an important role when it comes to the clinical result following THA. Several studies have documented that an increase in offset results in increased range of motion, improved mechanical conditions of the abductors and increased stability due to increased soft tissue tension [6, 12, 13]. Failure to restore offset has been associated with increased joint reactive force and hence an increase in polyethylene wear [14-16]. However, Little et al. suggested that an increase beyond 5 mm of the contralateral hip might also result in increased polyethylene wear [17].

Although the importance of femoral offset in THA has been emphasized in several studies, there is limited research directly investigating the role of the abductor lever arm and its effect on clinical outcome. Studies have reported a correlation between the abductor lever arm and abductor muscle strength. McGrory et al. reported that the length of the abductor lever arm was among the most important factors influencing abductor muscle strength [12]. Using a 3-dimensional biomechanical model, Delp et al. demonstrated that lateral displacement of the hip center adversely affected the function of the abductor muscles by decreasing the lever arm, thereby decreasing the capacity to generate hip abduction moments [8].

Our study provides clinical data that enables us to investigate how a change in lever arm affects the outcome after THA in a clinical setting. The strength of this study includes groups that are comparable in regards of operating technique and choice of implants.

The same two surgeons, using the direct anterior approach through the Smith-Petersen interval in every case, performed all the operations in our study. The same types of implants were used in all patients.

The radiological assessments were made using digital images from our database, enabling the investigator to use measurement tools with high degree of precision.

Furthermore, all measurements were performed by the same investigator (JB), which reduced interobserver variability.

There are some limitations to our study. The patients were only followed for one year postoperatively. It is possible that more time is required to demonstrate a difference in clinical outcome.

It is also possible that the instruments used to score the clinical outcome in our study lack the sufficient sensitivity to demonstrate a significant difference between the groups. Although both HOOS and Harris Hip Score have shown a high degree of validity, it is possible that these instruments are not sensitive enough to demonstrate an underlying difference in clinical outcome between the groups [18, 19].

In our study population, only 17 out of 148 patients experienced a shortening of the abductor lever arm. Several studies have reported that a shortening of the lever arm may result in weakness of the abductor muscles and reduced stability [6, 8, 12, 20]. It is possible that a higher frequency of patients with a decreased lever arm would have had a larger impact on the clinical scores.

The results of this study suggest that patients who retain their anatomical abductor lever arm do not experience a significantly better clinical outcome than patients who have their lever arm increased. When considering the potential disadvantages of

decreasing the lever arm, the surgeon should aim for an equal or slightly increased lever arm during THA.

References

1. Rorabeck, C.H., et al., *A double-blind study of 250 cases comparing cemented with cementless total hip arthroplasty. Cost-effectiveness and its impact on health-related quality of life.* Clin Orthop Relat Res, 1994(298): p. 156-64.
2. Karachalios, T., et al., *A 12- to 18-year radiographic follow-up study of Charnley low-friction arthroplasty. The role of the center of rotation.* Clin Orthop Relat Res, 1993(296): p. 140-7.
3. Kurtz, W.B., et al., *Factors affecting bony impingement in hip arthroplasty.* J Arthroplasty, 2010. **25**(4): p. 624-34 e1-2.
4. Maruyama, M., et al., *The Frank Stinchfield Award: Morphologic features of the acetabulum and femur: anteversion angle and implant positioning.* Clin Orthop Relat Res, 2001(393): p. 52-65.
5. Bonnin, M.P., et al., *Do we medialise the hip centre of rotation in total hip arthroplasty? Influence of acetabular offset and surgical technique.* Hip Int, 2012. **22**(4): p. 371-8.
6. Asayama, I., et al., *Reconstructed hip joint position and abductor muscle strength after total hip arthroplasty.* J Arthroplasty, 2005. **20**(4): p. 414-20.
7. Dastane, M., et al., *Hip offset in total hip arthroplasty: quantitative measurement with navigation.* Clin Orthop Relat Res, 2011. **469**(2): p. 429-36.
8. Delp, S.L., et al., *How superior placement of the joint center in hip arthroplasty affects the abductor muscles.* Clin Orthop Relat Res, 1996(328): p. 137-46.
9. Klassbo, M., E. Larsson, and E. Mannevik, *Hip disability and osteoarthritis outcome score. An extension of the Western Ontario and McMaster Universities Osteoarthritis Index.* Scand J Rheumatol, 2003. **32**(1): p. 46-51.
10. Paillard, P., *Hip replacement by a minimal anterior approach.* Int Orthop, 2007. **31 Suppl 1**: p. S13-5.
11. Matta, J.M. and T.A. Ferguson, *The anterior approach for hip replacement.* Orthopedics, 2005. **28**(9): p. 927-8.
12. McGrory, B.J., et al., *Effect of femoral offset on range of motion and abductor muscle strength after total hip arthroplasty.* J Bone Joint Surg Br, 1995. **77**(6): p. 865-9.
13. Matsushita, A., et al., *Effects of the femoral offset and the head size on the safe range of motion in total hip arthroplasty.* J Arthroplasty, 2009. **24**(4): p. 646-51.
14. Sakalkale, D.P., et al., *Effect of femoral component offset on polyethylene wear in total hip arthroplasty.* Clin Orthop Relat Res, 2001(388): p. 125-34.
15. Barrack, R.L., *Factors influencing polyethylene wear in total joint arthroplasty.* Orthopedics, 1998. **21**(9): p. 937-40.

16. Devane, P.A. and J.G. Horne, *Assessment of polyethylene wear in total hip replacement*. Clin Orthop Relat Res, 1999(369): p. 59-72.
17. Little, N.J., et al., *Acetabular polyethylene wear and acetabular inclination and femoral offset*. Clin Orthop Relat Res, 2009. **467**(11): p. 2895-900.
18. Soderman, P. and H. Malchau, *Is the Harris hip score system useful to study the outcome of total hip replacement?* Clin Orthop Relat Res, 2001(384): p. 189-97.
19. Nilsson, A.K., et al., *Hip disability and osteoarthritis outcome score (HOOS)-validity and responsiveness in total hip replacement*. BMC Musculoskelet Disord, 2003. **4**: p. 10.
20. Bourne, R.B. and C.H. Rorabeck, *Soft tissue balancing: the hip*. J Arthroplasty, 2002. **17**(4 Suppl 1): p. 17-22.