

Accuracy and cost of advanced cardiological diagnostic techniques in evaluation of coronary artery disease in heart transplant patients.

Svend Aakhus



Avdeling for helseledelse og helseøkonomi
Institutt for helse og samfunn
Det medisinske fakultet

UNIVERSITETET I OSLO

Oktober 2013

**Accuracy and cost of advanced cardiological
diagnostic techniques in evaluation of coronary
artery disease in heart transplant patients.**

Svend Aakhus

© Svend Aakhus

2013

Accuracy and cost of advanced cardiological diagnostic techniques in evaluation of coronary artery disease in heart transplant patients.

Svend Aakhus

<http://www.duo.uio.no/>

Trykk: Reprosentralen, Universitetet i Oslo

Abstract:

Medical imaging has rapidly increased in numbers and cost. Evaluation of diagnostic methods has much focused on accuracy, but less on cost and hazard. Advanced tests for coronary artery disease are expensive and carry a risk. In heart transplant (HTx) patients, coronary vasculopathy is prevalent, and annual follow-up comprises a coronary angiography. Less costly and low-risk techniques with adequate accuracy are desired. In this study we tested the diagnostic accuracy and cost of three available medical techniques to detect coronary artery stenosis (CAD) in HTx patients.

Methods: Fifty stable HTx patients aged (mean \pm SD) 57 \pm 8 years were studied during annual routine control with dobutamine stress echocardiography (dobECHO), dobutamine ^{99m}Tc-tetrofosmin emission tomography (dobSPET) and exercise ECG (exECG), and compared with coronary angiography. Cost of methods were derived from hospital accountancy data.

Results: Significant coronary artery stenosis in ≥ 1 major epicardial vessel was present in 14 patients (28.0%), but only 16 (32.0%) had complete normal angiograms. Sensitivity, specificity, and accuracy for CAD as compared to angiograms, was for dobECHO: 67%, 91%, and 82%; for dobSPET: 71%, 74%, and 73%; and for exECG: 20%, 91%, and 70%, respectively. By combining dobECHO with echocardiographic wall motion analysis, the rate of false negatives was reduced to 4%. Cost of dobECHO, dobSPET and exECG was estimated to 0.58, 1.45, and 0.25 times cost of angiography. DobSPET gives similar radiation exposure (7 mSv) as angiography.

Conclusion: DobECHO and dobSPET are feasible tests in HTx patients. DobECHO or dobSPET alone or combined with echocardiographic resting wall motion analysis, can be used with acceptable accuracy for identifying HTx patients in whom routine coronary angiography intermittently can be deferred. Of these, dobECHO is the least expensive, and carries the least risk to the patient. ExECG has low accuracy and cannot be recommended in HTx in spite of low cost.

Acknowledgement

My thanks go to professor Grete Botten and professor Tor Iversen for their advices on this thesis work. Thanks also to Department of Cardiology, Oslo University Hospital for allowance of some time to complete this final writing. Last but most important, my thanks go to colleagues contributing to the original article which is the basis of this thesis work, and in particular to the patients that dedicated their time and effort by participating in this study.

Oslo, October 2013

Svend Aakhus

Content

1	Introduction	9
1.1	Radiation exposure	9
1.2	Choice of imaging modality	10
1.3	Medical hazard	10
1.4	Heart transplant patients	12
1.5	Immunosuppressive treatment	13
1.6	Vasculopathy in heart transplant patients	13
1.7	Methods for detection of myocardial ischemia	13
1.8	Other imaging modalities	15
2	Methods	16
2.1	Cardiac catheterizations	16
2.2	Dobutamine stress echocardiography	16
2.3	Dobutamine stress SPET	17
2.4	Exercise ECG test	17
2.5	Cost analysis	18
2.6	Statistics	18
3	Results	19
3.1	False negative tests	20
3.2	Analysis of cost of the diagnostic tests	20
4	Discussion	23
4.1	Focus of an alternative test	23
4.2	Coronary artery stenosis versus myocardial ischemia	23
4.3	Discrepancies between diagnostic methods	24
4.4	Cost analysis	24
4.5	Radiation exposure	25
4.6	Proposed algorithm	26
4.7	Conclusion	27
5	References	28
6	Appendix	31

7	ORIGINAL ARTICLE	33
	ABSTRACT	36
	INTRODUCTION	37
	PATIENTS AND METHODS	38
	RESULTS	43
	DISCUSSION	47
	REFERENCES	52
	Figure 1	57
	Table 1	58
	Table 2	59
	Table 3	60
	Table 4	61
	Table 5	62

1 Introduction

Medical imaging has over the last three decades become pivotal in diagnosis, treatment and monitoring of a vast range of diseases. The benefit of improved diagnostic precision with earlier detection of disease, better planning of medical and surgical treatment has been immense for patients. This is the result of major advances in medical technology and engineering, combined with new treatment principles for prevalent disease entities as ischemic heart disease and cancer. International guidelines for diagnosis, treatment and monitoring of patients with established or at risk for heart disease have been produced by the international medical professional organizations (1-6). With the intention of benefit for the patient, algorithms for clinical decision making in these recommendations, often include a frequent use of advanced medical imaging techniques, in particular for patients with established heart disease, patients with cancer, with pulmonary disease and patients with rheumatologic diseases.

The increase in medical imaging over the last decades (7) has contributed to the concordant significant increase in health costs in the developed countries. For example, the estimated annual cost of medical diagnostic imaging in the United States in 2004 was USD 100 billion (8), with cardiac imaging as a major contributor with more than 9.3 million myocardial nuclear perfusion scans performed in the United States in 2002 (9) and with an increasing number of investigations thereafter (10).

1.1 Radiation exposure

Ionizing radiation is the basic principle of imaging techniques as X-ray, fluoroscopy, angiography, and computerized tomography (CT). Nuclear medical imaging techniques utilize isotopes with short half-life which emits radiation to the patient and personnel. There are, however, also natural sources of radiation as cosmic background radiation, inhalation of radioactive substances, i.e. radon gas, and ingestion of radioactive substances in food (11). The radiation exposure generated by medical imaging has steadily increased over the last three decades, and now cumulates to approximate the magnitude of natural source of radiation (11). Myocardial nuclear perfusion imaging and coronary angiography accounts for 22% and 5% of the total effective radiation dose by medical imaging in US, respectively (12).

1.2 Choice of imaging modality

Hitherto, the preferred imaging modality has in principle been the best diagnostic method available for the patient. Method quality has traditionally been assessed by testing in the clinical situation (13). Any new diagnostic method will in principle be evaluated in terms of sensitivity, specificity, and diagnostic accuracy when compared with a “gold standard” method. The best diagnostic method regardless of cost and risk is regarded “diagnostic gold standard”. The second level is evaluation of the method’s added value compared to existing methods. The third level is assessment of the new method’s ability to predict outcome in patients. The fourth level is assessment of the cost of the new method in comparison with the other available methods. Unfortunately, many methods are introduced on the basis of results for the first or two of these levels only.

The major increase in total cost of medical imaging worldwide strongly support that choice of test also should be based on proven cost-effectiveness. In consequence, the diagnostic yield of a method should be balanced against cost and hazard inferred to patients, personnel and society (14).

1.3 Medical hazard

Any medical imaging method will in principle influence living tissue. The hazard by use of the relevant methods can be summarized as in Table I. Acute hazard refers to the risk of adverse events during or immediately after a patient exam with the particular method. Chronic hazard refers to long term biological effects that may elicit or worsen disease progression.

Table 1.

<i>Methods</i>	Ionizing radiation	Isotope radioactive emission	Acute hazard	Chronic hazard	Personnel hazard	Society hazard
Fluoroscopy, x-ray	Yes	No	No	Yes, cancer	Yes, cancer	No
Angiography with radio-opaque contrast	Yes	No	Yes, allergic reaction, renal failure, emboli,	Yes, cancer	Yes, cancer	No

			hemorrhage			
CT with radio-opaque contrast	Yes	No	Yes, allergic reaction, renal failure	Yes, cancer	Yes, cancer	No
Nuclear imaging techniques (SPET)	No	Yes	Yes, allergic reaction	Yes, cancer	Yes, cancer	Yes, disposing of isotope remains
Echocardiography	No	No	No	No, unlikely	No	No
MRI with contrast	No	No	Yes, magnetic hazard	Yes, renal failure	Yes, magnetic effects (trauma)	No

SPET = Single photon emission tomography, CT = Computed tomography, MRI = Magnetic resonance imaging,

More attention is drawn to the acute hazards of the diagnostic tests, than to their potential chronic hazards. Of the acute hazards, the most feared adverse event is a cerebral insult, i.e. stroke, acutely inflicted on the patient by an embolus produced by an arterial catheterization. Although, many strokes resolves with an acceptable outcome, cerebral insult is a threat to all patients scheduled for angiography of the coronary arteries, thoracic aorta, or cervical arteries. For coronary angiography, the expected rate of severe complications is 0.5 to 2% (15-17), however, the risk rate varies between patient populations, and are higher in women and elderly. Moreover, hypertensive atherosclerotic patients with long lasting procedures have higher complication rates than young, normotensive patients without vascular disease where procedure time usually is short.

Coronary angiography and coronary CT necessitates the use of radio-opaque contrast medium which impairs renal function (18), and may elicit allergic reactions. Renal failure is usually reversible, but may be permanent in susceptible patients and require the use of temporary or permanent hemodialysis.

Diagnostic use of ionizing techniques represents a hazard to personnel performing the exams. To reduce the radiation exposure on personnel, protective coating and glasses containing lead

are obligatory during exam. However, these protective measures cannot eliminate radiation exposure to personnel. Therefore, radiation dosimeters are mandatory and should be worn by all health workers in environment using ionizing radiation. Dosimeters should be regularly monitored by experts on health physics. Standards are established that dictates the maximal radiation dosage for personnel.

1.4 Heart transplant patients

Heart transplantation is the preferred treatment for end-stage heart disease where all other treatment modalities have been exhausted. The number of heart transplantations is limited by the availability of donator hearts. Thus, a strict selection of patients has been implemented in order to preserve the optimal result for the donated organs. Norway is part of the Scandinavian heart transplant network. Available donor organs are exchanged between the other countries in this network. Organ transplantation requires an immunological compatibility, and there is time limit between organ explant and implant (usually 6 hours) set to preserve donor organ function, which both restrict the use of organs from more distant locations.

The annual rate of heart transplantations in Norway varies between 25 and 40, median survival time is 12 years (19) (Figure 1), and there are at present approximately 400 patients living with heart transplants in Norway today.

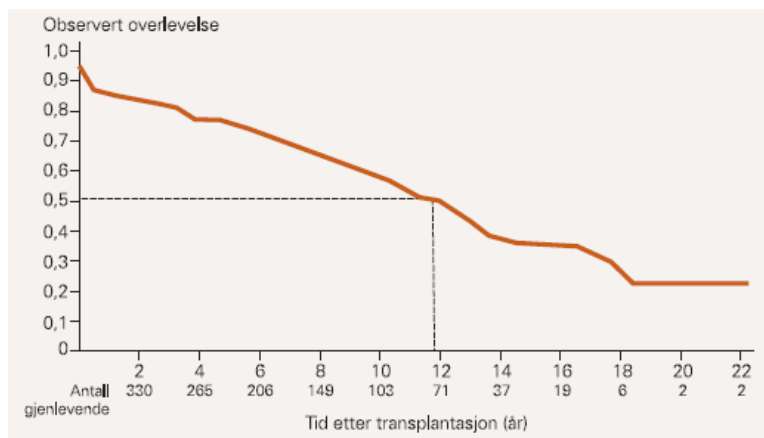


Figure 1. Cumulative survival for 522 first-time heart transplant recipients, Rikshospitalet, Norway. Adapted from reference 18 with permission.

1.5 Immunosuppressive treatment

Immunosuppressive treatment is necessary to avoid host versus graft rejection.

Immunosuppressive regimens are based on pharmacological calcineurin inhibition by cyclosporine or tacrolimus, in addition to prednisolone and mycophenolat or everolimus.

Immunosuppressive treatment minimizes the risk for transplant rejection, but have adverse effects such as impairment of renal function and hypertension (20).

1.6 Vasculopathy in heart transplant patients

Heart transplant patients are prone to develop vasculopathy (21), which is a major cause for their morbidity and mortality (22). This vasculopathy comprises atherosclerosis with a more transplant-specific vasculopathy characterized by increased endothelium thickness, both resulting in reduction of vessel lumen (21, 23, 24). Particularly important are vasculopathy in the transplant coronary arteries. Since the grafted heart is denervated, heart transplant patients do generally not experience typical chest pain (i.e. angina pectoris) during myocardial ischemia. More typically, an unspecific reduction of exercise capacity is typical for development of significant coronary artery disease in these patients. Thus, to reduce the risk of acute myocardial infarction, severe arrhythmias and heart failure after heart transplantation, a rigorous follow-up procedure has been implemented at most transplantation centers. In principle, all surviving patients are recommended an annual major follow-up comprising clinical exam, blood tests, echocardiography and coronary angiography.

Coronary angiography is regarded to be an expensive diagnostic method with potential hazard for the patient, and will due to the diffuse process of transplant vasculopathy not always be able to identify significant narrowing (stenosis) of the coronary arteries (25, 26). Thus, there has been a desire to replace it at least intermittently, with less costly methods with less risk, and adequate diagnostic accuracy.

1.7 Methods for detection of myocardial ischemia

In principle, there are three relevant alternative clinical methods available for identification of myocardial ischemia.

Exercise electrocardiogram (ExECG)

ExECG has been established as the first level test for patients suspect of having coronary artery disease (27). With ExECG, a 12 channel surface electrocardiogram is recorded from the patient at rest and during exercise. Typical voltage-alterations in the ECG pattern, i.e. so called STT segment depression, are used to identify ischemia. In populations with moderate prevalence of coronary artery disease, exECG have repeatedly proven diagnostic precision which is but moderate, with sensitivities 60-80%, specificities 80-90% and diagnostic accuracy 70%.

The test is feasible and safe for most patients (28), but requires that the patients is able to perform leg exercise either by ergometer bicycle, treadmill or step case.

Perfusion single photon emission tomography (SPET)

SPET has been widely used and established as the preferred second level method in diagnosis of coronary artery disease after exECG. With SPET, a radioactive short-lived isotope perfusing the myocardium is injected at rest and during peak exercise. The isotope emits photons that are recorded by a gamma camera, and differences in myocardial perfusion between rest and exercise can be detected as markers of ischemia (29). SPET is feasible in most patients since both medication (adenosine, dipyridamole or dobutamine) and ergometer bicycle/treadmill exercise can be employed to induce myocardial ischemia. Diagnostic accuracy is regarded better than exECG, in particular is the sensitivity higher, whereas specificity is somewhat lower.

Stress echocardiography

Stress echocardiography is an alternative to SPET in diagnosis of coronary artery disease (30). With stress echocardiography, ultrasound images of the left ventricle are obtained at rest and during increasing heart rate. Left ventricular wall motion is visually assessed at baseline and during stress, and reduced contractions (wall thickening) indicate ischemia. Stress echocardiography is feasible in most patients since both medication (dobutamine, dipyridamole) and ergometer bicycle/treadmill exercise can be employed to induce myocardial ischemia.

It is important to note that these alternative methods are designed to detect myocardial ischemia which is the presumed physiological result of significant coronary artery stenosis. A stenosis is defined as significant when the vessel diameter is reduced at least 50% as

compared to preceding segments. At rest, when little demands are put on the myocardium, even significant coronary artery stenosis do normally not elicit myocardial ischemia. However, when the patient starts to work and myocardial work and oxygen demands raise, ischemia and typical chest pain (angina pectoris) are elicited (31).

1.8 Other imaging modalities

Recently, computed tomography (CT) and magnetic resonance imaging (MRI) have been used to visualize coronary arterial anatomy (32). The precision of these methods have increased rapidly. CT is now used for screening of low-prevalence patients with chest pain to identify normal coronaries. If pathology is identified, coronary angiography is still needed. MRI has been used in a stress test setting for detection of myocardial ischemia (33). Both these techniques are, however, costly. They were not relevant at the time of planning of the present study, and were therefore not included in this work.

2 Methods

All heart transplantations and the main medical follow-up of HTx patients in Norway are performed at our institution. In the present study, patients were included after giving written informed consent. The study was approved by the Regional Committee for Ethics in Medicine. All patients were required to be clinically and hemodynamical stable without evidence for transplant rejection on endomyocardial biopsy. Patients with coronary vasculopathy on angiography were selected into the study by an outside observer in order to obtain that at least 20% of the group had CAD. Observers were blinded for patients' coronary status. The purpose of this semi-selection was to assure that a significant proportion, unknown to the other observers, of the study group had significant coronary artery disease. A too low prevalence of significant coronary artery disease in the study group would not allow evaluation of the accuracy of the diagnostic tests.

In all, fifty patients were included, and underwent head-to-head comparisons of dobECHO, dobSPET, and exECG testing as compared to the gold standard method, coronary angiography which was performed less than 4 weeks apart from the noninvasive tests.

2.1 Cardiac catheterization

Left heart catheterization with coronary angiography was performed by conventional Judkin's technique and each coronary artery assessed in at least 3 views. Coronary vasculopathy was assessed by an experienced radiologist without knowledge of patient data. A hemodynamically significant stenosis was considered present when vessel diameter stenosis was $\geq 50\%$. Right heart cardiac catheterization was performed using a standard Swan-Ganz balloon catheter technique.

2.2 Dobutamine stress echocardiography

A standard stress protocol was used. After resting recordings, dobutamine was infused intravenously in 3-minute increments from 5 to 40 $\mu\text{g}/\text{kg}/\text{min}$ in increments of 3 minutes. Conventional ultrasound images of the left ventricle were obtained at baseline, during and at peak stress. The test was completed at peak stress which was defined as the occurrence of either 1) new or worsened wall motion abnormality; 2) heart rate $\geq 85\%$ of age determined maximum ($220 - \text{age in years}$); 3) severe hypertension with either systolic or diastolic blood

pressure above 200 and 110 mmHg, respectively; 4) significant patient discomfort, or 5) peak dobutamine dose (40 $\mu\text{g}/\text{kg}/\text{min}$).

Image analysis was performed off-line by comparing wall motion and thickening in 16 left ventricular segments at baseline and during test by an experienced observer who was blinded for results of the other tests. A score was assigned to each of 16 left ventricular segments excluding the apical cap (34, 35). Ischemia was defined as new or worsening wall motion in at least 1 myocardial segment during test. The analysis was repeated by a blinded second observer for assessment of inter-observer repeatability.

2.3 Dobutamine stress SPET ($^{99\text{m}}$ Technetium-tetrofosmin myocardial perfusion imaging)

Baseline perfusion registrations were first obtained. Technetium-tetrofosmin (MyoviewTM, Amersham, Buckinghamshire, UK) were intravenously administered to patients with bodyweight below 75 kg, else 300 MBq was given. Single photon emission tomography (SPET) was performed 1 hour later. Later the same day, patients underwent a dobutamine stress test protocol identical with that used for the stress echocardiography. At 1.5 minute at peak dobutamine dose, the infusion was briefly terminated and a second dose of 750 MBq (<75 kg) or 900 MBq (≥ 75 kg) was injected intravenously, before the dobutamine infusion was resumed for the final minute. Following 30 - 60 minutes after test termination, a second SPET was performed.

Image processing and analysis was performed on the APEX Expert System (Elscent) with the CEqualTM software using both automatic and observer determined assessment of myocardial perfusion images.

2.4 Exercise ECG test

Maximal symptom-limited exercise testing was performed using an electrically braked bicycle ergometer. The test protocol was individualized using a starting load of 20-50 W increasing by 20 W every second minute until exhaustion. Exercise test was terminated at either of: patient exhaustion, typical chest pain, significant ST segment depression (≥ 2 mm measured 0.8 s after J-point), significant arrhythmias, or hypotension (drop in systolic blood

pressure >20 mmHg). Myocardial ischemia was defined by typical ST-T segment changes in 2 or more ECG leads.

2.5 Cost analysis

The variable and basic cost for each of the four diagnostic methods was estimated on the basis of accountancy data from Oslo University Hospital. For the calculations, the following assumptions were made: 1. Personnel cost including overhead was for physician set to 1000 NOK per hour, and for technician 500 NOK per hour. Personnel attendance in time is derived from the average values given by leaders of the respective hospital sections performing these methods (personal communication, dr. Knut Endresen, Section of Coronary Intervention, dr. Fjeld, Department for Nuclear Medicine, both Oslo University Hospital, Rikshospitalet), and own knowledge about exECG and dobECHO resources. Cost of single-use equipment and medication was derived from hospital accountancy, housing costs were assumed equal for the methods. The additional cost by a coronary angiography – only based strategy per false negative exam by any other method was obtained as cost of coronary angiography minus cost of method divided by %false negative exams (36).

2.6 Statistics

Results are presented as mean values with standard deviation (SD). The results of the respective noninvasive tests were compared to coronary angiography, with respect to overall test positivity for ischemia and for the location of ischemia related to the typical coronary vessel distribution. In this comparison, coronary stenosis was defined significant when ≥ 1 significant stenosis was present in any of the major epicardial vessels (LAD, CX or RCA), or in any of their major branches. Sensitivity, specificity, positive and negative predictive values, and diagnostic accuracy of each test were determined by conventional methods (37). Inter-observer agreement for stress echocardiography interpretation was assessed by percent agreement.

3 Results

Cardiac catheterization

In all, 18 patients (36.0%) had significant stenosis on ≥ 1 of the three major epicardial vessels, 23 (46.0%) had diffuse changes in major vessels and 16 (32.0%) in peripheral vessels. Sixteen patients (32.0%) had completely normal angiograms. No adverse events occurred.

Dobutamine stress echocardiography

Left ventricular resting wall motion abnormalities were present in 37 (74.0%). Scar formation was present in 17 (34.0%) patients, 14 (28.0%) in the LAD region. Reversible ischemia was found in 16 patients (32.0%), 10 (20.0%) comprising the LAD region. Sensitivity, specificity, and diagnostic accuracy was 67, 91, and 82%, respectively. Positive and negative predictive value was 80 and 83%. No adverse events occurred. The inter-observer agreement for interpretation of dobECHO was for reversible ischemia in ≥ 1 segment 74%, and for scar tissue 84%.

Dobutamine SPET test

Resting perfusion abnormalities were found in anterior wall in 10 patients (20.8%) and in inferior wall in 7 (14.6%). Evidence for irreversible injury, i.e. fibrosis, was present in 13 (27.1%), 9 (18.8%) in the LAD region, 2 (4.2%) in the CX region, and 9 (18.8%) in the RCA region, affecting $16 \pm 9\%$ of the myocardium. Nineteen (39.6%) had evidence for reversible ischemia, and the ischemic region comprised $7 \pm 4\%$ of the myocardium. Sensitivity, specificity, and diagnostic accuracy was 71, 74, and 73%, respectively. Positive and negative predictive value was 60 and 82%. No adverse events occurred.

Exercise ECG

In 8 patients (17.8%) ECG was not interpretable for ischemic changes due to complete right bundle branch block in 7 patients and technically inadequate ECG in one. Of the 33 patients completing the test, only 4 (12.1%) had ECG changes positive for myocardial ischemia, Sensitivity, specificity, and diagnostic accuracy was 20, 91, and 70%, respectively. Positive and negative predictive value was 50 and 72%. No adverse events occurred.

3.1 False negative tests

There were 6 false negative tests (12.0%) in dobECHO, 5 (10,4%) in dobSPET, and 8 (24,2%) in exECG. By combining dobECHO and dobSPET with resting echocardiography, false negatives were reduced to 2 and 0 patients, respectively.

3.2 Analysis of cost of the diagnostic tests

The estimated cost per exam in terms of personnel costs, used of medication and single use equipment was for dobECHO, dobSPET, exECG and coronary angiography NOK 1.961, 4.867, 829, and 3.356, respectively (Table 2).

Table 2. Estimated cost of diagnostic tests for myocardial ischemia

Cost				
(in 1000 NOK)				
	dobECHO	dobSPET	exECG	Angiography
Time for exam (h)	1	4	0,5	1
Number of physicians (N)	1	1	1	1
Number of technicians (N)	1	2	1	2
Salary phys pr exam	0,921	0,921	0,461	0,921
Salary techn pr exam	0,500	1,200	0,250	1,000
<i>Variable expenses</i>				
Medication per exam	0,200	2,100	0,000	0,317
Single use equipment	0,100	0,100	0,050	0,550
Sum variable costs	1,721	4,321	0,761	2,788
<i>Basic expenses</i>				
Equipment cost per exm	0,195	0,455	0,034	0,284
Equipment maintenance per	0,045	0,091	0,034	0,284
Housing = equal	0	0	0	0
Sum basic cost	0,240	0,545	0,068	0,568
Total costs per exam	1,961	4,867	0,829	3,356

*Assumptions: See Methods section.

When using cost of coronary angiography as unity, the cost of the exECG was 0.25, dobECHO 0.58 and dobSPET 1.45, respectively (Figure 2).

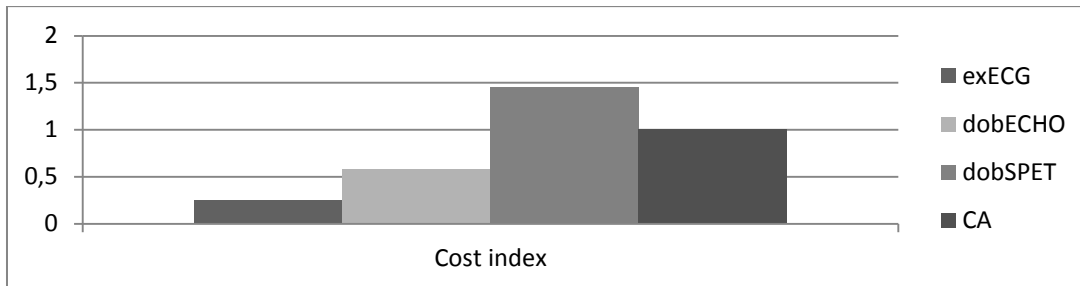


Figure 2. Estimated cost for dobutamine stress echocardiography (dobECHO), dobutamine stress SPET (dobSPET) and coronary angiography (CA) normalized for cost of exercise ECG = 1.

Analysis of the added cost of different treatment strategies (Table 3), revealed that the cost of false positive exams leading to unnecessary coronary angiographies were lowest for dobECHO and highest for dobSPET combined with wall motion analysis. The additional direct cost of a coronary angiography-only based strategy is NOK 34873 when compared to dobECHO with resting wall motion analysis, but actually less costly than any of the dobSPET based strategies.

The average radiation exposure for the patients is 6.0 mSv for coronary angiography and 7.2 mSv for SPET (Department of Radiation Physics, Oslo University Hospital: personal communication). There is no radiation exposure during dobECHO or exECG.

Table 3. Added cost of different diagnostic strategies.

	CA	dobECHO	dobECHO + WMA	dobSPET	dobSPET + WMA	exECG
N =	50	50	58	48	48	33
Cost per exam (NOK)	3356	1961	1961	4867	5867*	829
No. false negatives	0	6	2	5	0	8
No. false positives	0	3	19	8	23	2
Added cost per exam**	NA	201	1275	559	1608	203
Added cost per identified CAD by a CA strategy***	NA	11264	34873	-14522	- ∞	10444

WMA = wall motion analysis by echocardiography; CA = coronary angiography; * Added cost of baseline echocardiography: 1000. **Cost added due to false positive exam leading to an (unnecessary) coronary angiography. CAD = Coronary stenosis. *** calculated as difference in cost between CA and method divided by percent false negatives. NA = Not applicable.

4 Discussion

4.1 Focus of an alternative test

In heart transplant patients, coronary angiography is used as part of the annual follow-up. The reason is that coronary artery disease is prevalent and do not elicit typical symptoms in the patients due to the denervated transplanted heart. Due to the risks of adverse events as well as the cost of coronary angiography, alternatives have been sought for. The most important aspect of the annual follow-up exams is to identify patients who have developed significant coronary artery disease. Thus, a test which is positive for myocardial ischemia would lead to referral of the patient to coronary angiography. A negative test would decline further investigation until next follow-up. A false positive test result implies that a patient without coronary artery disease would undergo a coronary angiography which was not needed. A false negative result implies that a patient with a significant coronary artery disease would (incorrectly) be classified as healthy and further investigation postponed to next follow-up. Such a patient carries the risk of acute and chronic myocardial ischemia which relates to infarctions, rhythm disturbances, heart failure and sudden death (38). The latter prospect is by far more threatening to the patient than the former. Thus, the focus of any alternative test competing coronary angiography should be to minimize the number of false negative exams.

The present analysis revealed that the diagnostic accuracy of dobECHO and dobSPET was comparable, and by far exceeded that of exECG. Moreover, when combining knowledge of left ventricular wall motion abnormalities on resting echocardiography with the results of stress tests, the number of false negative stress test was reduced from 6 and 5 for dobECHO and dobSPET, to 1 and 0, respectively. Whereas, left ventricular wall motion abnormalities are evaluated by echocardiography as part of dobECHO, the use of dobSPET would require an added resting echocardiography to get access to this information. Moreover, the cost and radiation exposure related to dobSPET does hamper its use in a clinical setting where dobECHO is available.

4.2 Coronary artery stenosis versus myocardial ischemia

There is a principal diagnostic difference between coronary angiography and the alternative tests used in the present paper. Coronary angiography by means of intracoronary injection of

radio-opaque contrast medium displays the coronary arterial anatomy and identifies coronary arterial luminal shape and direction. A stenosis of a coronary vessel is identified by a reduction of luminal diameter as compared to the preceding vessel segment, and is defined as at least 50% diameter reduction. This type of stenosis elicits myocardial ischemia during exercise, and do represent an indication for treatment by either percutaneous intervention (balloon arterioplasty) or surgery (coronary artery bypass grafting). DobSPET, dobECHO and exECG are all methods designed to identify myocardial ischemia. With these methods, myocardial ischemia can be identified either as reduced blood flow (perfusion) in the ischemic region of the working left ventricular muscular wall by SPET, as reduced thickening and movement of the myocardial wall during stress (echocardiography), or as changes in the electrical depolarization patterns of the heart (electrocardiogram). Thus, whereas coronary angiography identifies vessel anatomy, the other tests are designed to detect the likely consequence of significant coronary vessel disease, namely myocardial ischaemia.

4.3 Discrepancies between diagnostic methods

From this, it is understandable that the inherent differences between the methods will produce discrepant results in some patients. For example, it may be that a particular coronary stenosis which was defined significant on coronary angiography, do in fact not elicit myocardial ischemia during exercise, for example due to the exercise work load being too low. The classification of coronary stenosis on angiograms is also susceptible to variations in interpretation, and borderline significant stenosis, i.e. diameter reduction 30-50%, may be misclassified. A coronary stenosis misclassified as significant on angiography, with negative tests on myocardial ischemia by dobECHO, dobSPET, and exECG would lead to misclassification of these tests as false negatives. Other well-known obstacles to interpretation of the alternative tests are suboptimal increase in heart rate (dobECHO and dobSPET), submaximal exercise work load (exECG), reduced image quality and bundle branch blocks (dobECHO and to a lesser degree, dobSPET), suboptimal voltage recordings and bundle branch blocks (exECG).

4.4 Cost analysis

The high cost of coronary angiography is often used as an argument against its use. In the present analysis, coronary angiography was found surprisingly inexpensive with estimated

direct costs only 1.7 times cost of dobECHO and in fact less expensive than dobSPET. Thus, it is reasonable to maintain that direct costs are not a significant argument against the use of coronary angiography.

The cost of the treatment strategies (Table 2) was lowest for dobECHO and highest for dobSPET combined with echocardiographic wall motion analysis. This argument is based on the cost of false positives which increase in number with the latter strategy. A false positive exam will lead to an unnecessary coronary angiography. On the other hand, it is difficult to estimate the cost of false negatives, since exact rates of coronary events linked by different sets of coronary vasculopathy is not known in this population. It is, however, known that intervention on significant stenosis is a sound clinical strategy (38), thus the strategy which reduces the number of false negatives would be preferable. In this perspective, dobECHO with wall motion analysis would be the preferred strategy, but carries an extra cost due to the 12% rate of false negatives. The estimated additional costs for using a coronary angiography based-only strategy was estimated to NOK 34.873 for each false negative dobECHO combined with resting wall motion analysis.

However, one should consider the indirect costs of the methods as well. The rate of significant adverse events (acute and chronic) are negligible for dobECHO (i.e. < 10.000) (39), and exECG (28). DobEcho has also been found safe and feasible in the subpopulation of heart transplant patients (40). The rate of acute adverse events are low for dobSPET (41), whereas coronary angiography has a documented rate of major adverse events of approx. 0.5% (17), concordant with the registered rate of major complications (i.e. cerebral emboli, myocardial infarction, or pericardial tamponade) at our institution of 0.2% (Quality register, Department of Cardiology, Oslo University Hospital, 2011).

4.5 Radiation exposure

The long term effects of radiation exposure to the patient and risk for cancer have obtained much recent attention (42-45). The per-capita effective radiation dose of the US population from all sources increased by 72% from 1980 to 2006, primarily due to a 5.7 fold increase in medical imaging (45). Recently, UK estimates of 700 cancers per year as a cause of medical diagnostic imaging with radiation exposure have been presented (46). However, the link between radiation effects on living tissue and subsequent cancer development in patients are based on wide approximations, in part based on data derived after nuclear bomb detonations

in Japan in 1945 (46), and this potential link is under debate (45, 47, 48). The intrinsic risk of cancer is much greater than the potential risk of radiation which would be expected to raise the relative risk less than 1% (45).

This said there is general agreement about the “do not harm” principle in medicine which infers that medical imaging radiation exposure indeed should be kept as low as possible.

Coronary angiography and dobspET both carries a radiation exposure of about 6-7 mSv, which is considered moderate (12). An estimated increase in risk for development of cancer for 50 year old persons in the lifetime perspective would be 1 per 1000 tests (0.1%) at this level of radiation exposure (49). When considering the present algorithm of annual follow up of the HTx patients, this perspective emerges more important. The median survival of HTX patients in Norway is approximately 12 years, and many patients live more than 20 years after HTx (19). Considering that cancer development is one of the major threats for these patients (19), due to their obligatory immunosuppressive treatment, radiation exposure should certainly be kept at a minimum.

The additional cost of radiation exposure to the personnel is also relevant, but will be but little affected by the choice of diagnostic algorithm due to the relatively small population of heart transplant patients.

4.6 Proposed algorithm

Considering the chronic progressive inflammatory nature of the HTx vasculopathy and the inherent inaccuracies of all noninvasive tests, coronary angiography is still needed for accurate monitoring of coronary artery status. The question is whether coronary angiograms can be intermittently deferred. By choosing doBECHO combined with echocardiographic analysis of resting left ventricular wall motion, only 4% false negative tests would be expected. The predictive value of a negative doBECHO for subsequent coronary events in patients with ischemic heart disease and in HTx population is high (50-52). Thus, it seems appropriate to defer coronary angiography at least every second annual follow-up, when replaced by a doBECHO.

4.7 Conclusion

Advanced cardiac imaging methods for coronary artery disease in heart transplant patients carry different precision and cost. ExECG, in spite of being inexpensive, cannot be recommended due to its low sensitivity for disease. The diagnostic accuracy of dobECHO and dobSPET are comparable, however, the direct cost of dobSPET exceeds dobECHO with a factor of 2.5. Moreover, dobSPET carries a significant radiation dose which may contribute to the patient's long-term risk for cancer. The gold standard, coronary angiography, was less expensive than reported elsewhere, but carries a defined risk for acute and long-term adverse events. Based on an analysis of cost of the diagnostic tests, dobECHO with wall motion analysis is recommended to replace coronary angiography at least every second year in the follow-up program for heart transplant patients.

5 References

1. Curigliano G, Cardinale D, Suter T, Plataniotis G, de Azambuja E, Sandri MT, et al. Cardiovascular toxicity induced by chemotherapy, targeted agents and radiotherapy: ESMO Clinical Practice Guidelines. *Ann Oncol* 2012;23 Suppl 7:155-66
2. Gender M, Regitz-Zagrosek V, Blomstrom Lundqvist C, Borghi C, et al. ESC Guidelines on the management of cardiovascular diseases during pregnancy: the Task Force on the Management of Cardiovascular Diseases during Pregnancy of the European Society of Cardiology (ESC). *Eur Heart J* 2011;32:3147-97
3. Fox K, Garcia MA, Ardissino D, Buszman P, Camici PG, Crea F, et al. Guidelines on the management of stable angina pectoris: executive summary. *Eur Heart J* 2006;27:1341-81
4. Tendera M, Aboyans V, Bartelink ML, Baumgartner I, Clement D, et al. ESC Guidelines on the diagnosis and treatment of peripheral artery diseases. *Eur Heart J* 2011;32:2851-906
5. Gomez-Marcos MA, Gonzalez-Elena LJ, Recio-Rodriguez JI, Rodriguez-Sanchez E, Magallon-Botaya R, Munoz-Moreno MF, et al. Cardiovascular risk assessment in hypertensive patients with tests recommended by the European Guidelines on Hypertension. *Eur J Prev Cardiol.* 2012;19:515-22
6. Ryden L, Grant PJ, Anker SD, Berne C, Cosentino F, et al. ESC Guidelines on diabetes, pre-diabetes, and cardiovascular diseases developed in collaboration with the EASD. *Eur Heart J* E-pub:2013-09-03
7. Smith-Bindman R, Miglioretti DL, Larson EB. Rising use of diagnostic medical imaging in a large integrated health system. *Health affairs.* 2008;27:1491-502
8. Iglehart JK. The new era of medical imaging-progress and pitfalls. *N Engl J Med* 2006;354:2822-8
9. Brindis RG, Douglas PS, Hendel RC, Peterson ED, Wolk MJ, Allen JM, et al. ACCF/ASNC appropriateness criteria for single-photon emission computed tomography myocardial perfusion imaging (SPECT MPI). *J Am Coll Cardiol* 2005;46:1587-605
10. Picano E. Economic and biological costs of cardiac imaging. *Cardiovasc Ultrasound.* 2005;3:13-20
11. Picano E. Informed consent and communication of risk from radiological and nuclear medicine examinations: how to escape from a communication inferno. *Br Med J* 2004;329:849-51
12. Fazel R, Krumholz HM, Wang Y, Ross JS, Chen J, Ting HH, et al. Exposure to low-dose ionizing radiation from medical imaging procedures. *N Engl J Med* 2009;361:849-57
13. Schaafsma JD, van der Graaf Y, Rinkel GJ, Buskens E. Decision analysis to complete diagnostic research by closing the gap between test characteristics and cost-effectiveness. *J Clin Epidemiol* 2009;62:1248-52
14. Nissen SE, Thomas JD. President's page: the rapid emergence of multi-modality cardiovascular imaging. *J Am Coll Cardiol* 2006;48:217-8
15. Johnston N, Schenck-Gustafsson K, Lagerqvist B. Are we using cardiovascular medications and coronary angiography appropriately in men and women with chest pain? *Eur Heart J* 2011;32:1331-6
16. Pohler E, Gunther H, Diekmann M, Eggeling T. Outpatient coronary angiography—safety and feasibility. *Cardiology* 1994;84:305-9
17. Werner N, Zahn R, Zeymer U. Stroke in patients undergoing coronary angiography and percutaneous coronary intervention: incidence, predictors, outcome and therapeutic options. *Exp Rev Cardiovasc Ther* 2012;10:1297-1305

18. Budano C, Levis M, D'Amico M, Usmiani T, Fava A, Sbarra P, et al. Impact of contrast-induced acute kidney injury definition on clinical outcomes. *Am Heart J* 2011;161:963-71
19. Simonsen S, Andreassen AK, Gullestad L, Leivestad T, Fiane AE, Geiran OR. Overlevelse etter hjertetransplantasjon i Norge.[Survival after heart transplantation in Norway]. *Tidssk Nor Laegeforen* 2007;127:865-8
20. Al Aly Z, Abbas S, Moore E, Diallo O, Hauptman PJ, Bastani B. The natural history of renal function following orthotopic heart transplant. *Clin Transpl* 2005;19:683-9
21. Gao SZ, Alderman EL, Schroeder JS, Silverman JF, Hunt SA. Accelerated coronary vascular disease in the heart transplant patient: coronary arteriographic findings. *J Am Coll Cardiol* 1988;12:334-40
22. Kaye MP. The Registry of the International Society for Heart and Lung Transplantation: tenth official report--1993. *J Heart Lung Transplant* 1993;12:541-8
23. Rickenbacher PR, Kemna MS, Pinto FJ, Hunt SA, Alderman EL, Schroeder JS, et al. Coronary artery intimal thickening in the transplanted heart. An in vivo intracoronary ultrasound study of immunologic and metabolic risk factors. *Transplantation* 1996;61:46-53
24. Johnson DE, Alderman EL, Schroeder JS, Gao SZ, Hunt S, DeCampi WM, et al. Transplant coronary artery disease: histopathologic correlations with angiographic morphology. *J Am Coll Cardiol* 1991;17:449-57
25. Spes CH, Klauss V, Rieber J, Schnaack SD, Tammen AR, Uberfuhr P, et al. Functional and morphological findings in heart transplant recipients with a normal coronary angiogram: an analysis by dobutamine stress echocardiography, intracoronary Doppler and intravascular ultrasound. *J Heart Lung Transplant* 1999;18:391-8
26. Marcovitz PA, Armstrong WF. Accuracy of dobutamine stress echocardiography in detecting coronary artery disease. *Am J Cardiol* 1992;69:1269-73
27. Erikssen G, Bodegard J, Erikssen J. Arbeids-EKG. [Exercise ECG]. *Tidsskr Nor Laegeforen* 2004;124:339-41
28. Sandvik L, Erikssen J, Thaulow E, Erikssen G, Mundal R, Rodahl K. Physical fitness as a predictor of mortality among healthy, middle-aged Norwegian men. *N Engl J Med* 1993;328:533-7
29. Elhendy A, Sozzi FB, van Domburg RT, Vantrimpont P, Valkema R, Krenning EP, et al. Accuracy of dobutamine tetrofosmin myocardial perfusion imaging for the noninvasive diagnosis of transplant coronary artery stenosis. *J Heart Lung Transplant* 2000;19:360-6.
30. Marwick T, Willemart B, D'Hondt AM, Baudhuin T, Wijns W, Detry JM, et al. Selection of the optimal nonexercise stress for the evaluation of ischemic regional myocardial dysfunction and malperfusion. Comparison of dobutamine and adenosine using echocardiography and 99mTc-MIBI single photon emission computed tomography. *Circulation*. 1993;87:345-54
31. Zeiher AM, Wollschlaeger H, Bonzel T, Kasper W, Just H. Hierarchy of levels of ischemia-induced impairment in regional left ventricular systolic function in man. *Circulation* 1987;76:768-76.
32. Reddy GP, Pujadas S, Ordovas KG, Higgins CB. MR imaging of ischemic heart disease. *Magn Resonance Imag Clin North Am* 2008;16:201-12
33. Raman SV, Dickerson JA, Jekic M, Foster EL, Pennell ML, McCarthy B, et al. Real-time cine and myocardial perfusion with treadmill exercise stress cardiovascular magnetic resonance in patients referred for stress SPECT. *J Cardiovasc Magn Res* 2010;12:41-50
34. Cerqueira MD, Weissman NJ, Dilsizian V, Jacobs AK, Kaul S, Laskey WK, et al. Standardized myocardial segmentation and nomenclature for tomographic imaging of the heart. *Circulation*. 2002;105:539-42

35. Schiller NB, Shah PM, Crawford M, DeMaria A, Devereux R, Feigenbaum H, et al. Recommendations for quantitation of the left ventricle by two-dimensional echocardiography. American Society of Echocardiography Committee on Standards, Subcommittee on Quantitation of Two-Dimensional Echocardiograms. *J Am Soc Echocardiogr* 1989;2:358-67
36. Armstrong GT, Plana JC, Zhang N, Srivastava D, Green DM, Ness KK, et al. Screening adult survivors of childhood cancer for cardiomyopathy: comparison of echocardiography and cardiac magnetic resonance imaging. *J Clin Oncol* 2012;30:2876-84
37. Altman DG. Practical statistics for medical research. London: Chapman and Hall; 1991.
38. Syeda B, Roedler S, Schukro C, Yahya N, Zuckermann A, Glogar D. Transplant coronary artery disease: Incidence, progression and interventional revascularization. *Int J Cardiol* 2005;104:269-74
39. Mertes H, Sawada SG, Ryan T, Segar DS, Kovacs R, Foltz J, et al. Symptoms, adverse effects, and complications associated with dobutamine stress echocardiography. Experience in 1118 patients. *Circulation*. 1993;88:15-9
40. Akosah KO, Denlinger B, Mohanty PK. Safety profile and hemodynamic responses to beta-adrenergic stimulation by dobutamine in heart transplant patients. *Chest* 1999;116:1587-92
41. Elhendy A, Bax JJ, Poldermans D. Dobutamine stress myocardial perfusion imaging in coronary artery disease. *J Nucl Med* 2002;43:1634-46
42. Picano E. Sustainability of medical imaging. *Br Med J* 2004;328:578-80
43. Leo CG, Carpeggiani C, Picano E. Cost and benefit in cardiovascular imaging: the quest for economic sustainability. *Int J Cardiovasc Imag* 2010;26:613-6
44. Marwick TH, Buonocore J. Environmental impact of cardiac imaging tests for the diagnosis of coronary artery disease. *Heart* 2011;97:1128-31
45. Gerber TC, Gibbons RJ. Weighing the risks and benefits of cardiac imaging with ionizing radiation. *J Am Coll Cardiol Cardiovasc imag*. 2010;3:528-35
46. Berrington de Gonzalez A, Darby S. Risk of cancer from diagnostic X-rays: estimates for the UK and 14 other countries. *Lancet* 2004;363:345-51
47. Tubiana M, Aurengo A, Masse R, Valleron AJ. Risk of cancer from diagnostic x-rays. *Lancet* 2004;363:1908
48. Cameron JR. Link between diagnostic X-rays and cancer uncertain. *Evidencebased Healthcare* 2004;8:205-6
49. Berrington de Gonzalez A, Kim KP, Smith-Bindman R, McAreavey D. Myocardial perfusion scans: projected population cancer risks from current levels of use in the United States. *Circulation* 2010;122:2403-10
50. Chaowalit N, McCully RB, Callahan MJ, Mookadam F, Bailey KR, Pellikka PA. Outcomes after normal dobutamine stress echocardiography and predictors of adverse events: long-term follow-up of 3014 patients. *Eur Heart J* 2006;27:3039-44
51. Akosah KO, McDaniel S, Hanrahan JS, Mohanty PK. Dobutamine stress echocardiography early after heart transplantation predicts development of allograft coronary artery disease and outcome. *J Am Coll Cardiol* 1998;31:1607-14
52. Spes CH, Klauss V, Mudra H, Schnaack SD, Tammen AR, Rieber J, et al. Diagnostic and prognostic value of serial dobutamine stress echocardiography for noninvasive assessment of cardiac allograft vasculopathy: a comparison with coronary angiography and intravascular ultrasound. *Circulation* 1999;100:509-15

6 Appendix

The authors of the *original article* contributed to the work as follows:

Svend Aakhus: Conception and design of study, performing all dobutamine stress echocardiograms, analysis and interpretation of data, drafting and revising article, approval of final version.

Helge Rootwelt: Performing all dobutamine stress SPET, analysis and interpretation of data, revising article.

Lars Aaberge: Analysis and interpretation of data, revising article.

Lars Gullestad: Performing all exercise ECG tests, analysis and interpretation of data, revising article.

Kjell Levorstad: Performing coronary angiograms, analysis and interpretation of data, revising article.

Svein Simonsen: Contributed to design of study, analysis and interpretation of data, revising article.

7 ORIGINAL ARTICLE

Accuracy and cost of advanced cardiological diagnostic techniques in coronary artery disease in stable heart transplant patients.

A head-to-head comparison of dobutamine stress echocardiography, dobutamine stress ^{99m}Tc-tetrofosmin SPET imaging, and exercise ECG vs. coronary angiography.

*Svend Aakhus, MD, PhD, **Helge Rootwelt, MD, PhD, *Lars Aaberge, MD, PhD, *Lars Gullestad, MD, PhD, #Kjell Levorstad, MD, PhD, *Svein Simonsen, MD, PhD.

*Department of Cardiology, **Department of Clinical Chemistry, Section of Nuclear Medicine, and #Department of Radiology,

Oslo University Hospital, Rikshospitalet

ORIGINAL ARTICLE

Accuracy and cost of advanced cardiological diagnostic techniques in coronary artery disease in stable heart transplant patients.

A head-to-head comparison of dobutamine stress echocardiography, dobutamine stress ^{99m}Tc-tetrofosmin SPET imaging, and exercise ECG vs. coronary angiography.

*Svend Aakhus, MD, PhD, **Helge Rootwelt, MD, PhD, *Lars Aaberge, MD, PhD, *Lars Gullestad, MD, PhD, #Kjell Levorstad, MD, PhD, *Svein Simonsen, MD, PhD.

*Department of Cardiology, **Department of Clinical Chemistry, Section of Nuclear Medicine, and #Department of Radiology

Oslo University Hospital, Rikshospitalet

Grant support: The study was supported by an unrestricted research grant from Medinnova AS, Rikshospitalet, 0027 Oslo

Corresponding author:

Svend Aakhus, MD, PhD, FESC

Department of Cardiology, Oslo University Hospital, Rikshospitalet

0027 OSLO, NORWAY

Telephone: + 47 23 07 24 09, Fax: + 47 23 07 24 18, E-mail: saakhus@ous-hf.no

ABSTRACT:

Background: Coronary vasculopathy is prevalent in heart transplant (HTx) patients, and is a major cause of post-transplant morbidity and mortality. Present follow-up strategies include annual coronary angiography which is expensive and carries a risk for the patient. Thus, non-invasive less costly and low-risk techniques to assess ischemic heart disease in these patients are desired. We tested the diagnostic accuracy and cost of stress echocardiography, stress scintigraphy, and exercise ECG to detect coronary stenosis (CAD) in HTx patients.

Methods: Fifty stable HTx patients aged (mean±SD) 57±8 years were studied during an annual routine control with dobutamine stress echocardiography (dobECHO), dobutamine ^{99m}Tc-tetrofosmin emission tomography (dobSPET) and exercise ECG (exECG), and compared to the routine coronary angiography.

Results: Significant coronary artery stenosis in ≥1 major epicardial vessel was present in 14 patients (28.0%), but only 16 (32.0%) had complete normal angiograms. Sensitivity, specificity and accuracy for CAD as compared to angiograms, was for dobECHO: 67%, 91%, and 82%; for dobSPET: 71%, 74%, and 73%; and for exECG: 20%, 91%, and 70%, respectively. There were 6 false negatives (12.0%) in dobECHO, 5 (10.4%) in dobSPET, and 8 (24.2%) in exECG. By combining dobECHO and dobSPET with resting wall motion data on echocardiography, the number of false negatives was reduced to 1 and 0 patients, respectively. Cost of dobECHO, dobSPET and exECG was estimated to 0.58, 1.45, and 0.25 times the cost of angiography.

Conclusion: DobECHO and dobSPET are feasible tests in HTx patients. DobECHO or dobSPET combined with echocardiographic resting wall motion analysis, can be used with acceptable accuracy for identifying HTx patients in whom routine coronary angiography intermittently can be deferred. Of these, dobECHO is the least expensive and carries the least risk. ExECG has low accuracy and cannot be recommended in HTx in spite of low cost.

INTRODUCTION

Health care expenses have increased significantly in the developed countries over the last decades (1). The increasing use of advanced imaging techniques importantly contributes to this (2, 3). Moreover, many imaging techniques are based on ionizing radiation, which in the long term contributes to risk of cancer (4). Thus, less costly diagnostic techniques with minimal hazard, but with adequate accuracy have been sought for. In selected patient populations, follow-up care comprises regular investigation with coronary angiography which is an invasive and costly procedure with a risk for major adverse events of 0.5% (5). A typical example is heart transplant (HTx) patients who conventionally undergo annual coronary angiography during follow-up.

Coronary vasculopathy is prevalent in heart transplant (HTx) patients (6, 7), and represents the major limitation for their long-term survival (8). The vasculopathy in HTx recipients is characterized by diffuse intimal thickening (9) combined with atheromatous lesions, ectasies, stenoses, and distal obliterative disease (7, 10). Treatment of a significant coronary artery stenosis in HTx improves patients' outcome (11). Due to cardiac denervation, these patients usually do not experience typical symptoms as anginal pain, and most follow-up programmes therefore comprise regular coronary angiography. Since angiography is potentially harmful to the patients (5), costly, and does not always identify the vasculopathy correctly (10, 12), accurate noninvasive stress tests have been sought for.

Stress echocardiography with dobutamine is a feasible and accurate noninvasive test in patients with ischemic heart disease (13-15), but the diagnostic value in HTx patients have varied (16-21), although its prognostic value has been proven (22). Stress perfusion imaging and exercise electrocardiograms (ECG) have both demonstrated suboptimal sensitivities for significant coronary artery disease in HTx patients (23-25), but have been useful in predicting long-term survival (26). Recently, ^{99m}Tc-tetrofosmin has held promise as a more suitable agent for diagnosis of allograft vasculopathy (27), and diagnostic accuracy was found to

improve when results of stress perfusion testing were combined with resting echocardiography data (28).

The aim of the present study was to assess prospectively, the diagnostic accuracy and cost-effectiveness of dobutamine stress echocardiography (dobECHO), dobutamine stress ^{99m}Tc-tetrofosmin perfusion tomography (dobSPET), and ergometer bicycle maximal symptom limited exercise ECG testing (exECG) for CAD as compared to the “gold standard” coronary angiography, in HTx patients.

PATIENTS AND METHODS

All heart transplantations and main follow-up of HTx patients in Norway are performed at our institution. During the time of study, immunosuppressive treatment was a combination of cyclosporine A, azathioprine, and prednisolone. Patients were included after giving written informed consent. All patients were required to be clinically and hemodynamically stable without evidence for transplant rejection on endomyocardial biopsy. Patients with coronary vasculopathy on angiography were selected into the study by an outside observer in order to obtain at least 20% of the group with CAD. Observers were blinded for the coronary status of the patients. The purpose of this selection was to assure that the accuracy of the diagnostic tests could be evaluated. The study protocol was approved by the Regional Committee for Ethics in Medicine.

In all, fifty patients were included, and underwent dobECHO, dobSPET, and exECG testing less than 4 weeks apart from the cardiac catheterizations with coronary angiography. The noninvasive tests were performed after patients had discontinued beta-blockers, calcium antagonists, and nitrates for at least 24 hours and in case of long-acting beta-blockers for at least 36 hours. At the day of dobSPET, the patients also abstained from caffeine, tea, and nicotine.

Cardiac catheterization: Left heart catheterization with coronary angiography was performed by conventional Judkin's technique and each coronary artery assessed in at least 3 views. Coronary vasculopathy was assessed by an experienced radiologist without knowledge of patient data. Each major coronary artery vessel with branches was described, i.e. left main stem; left anterior descending artery (LAD) with branches (1. and 2. diagonal arteries); circumflex artery (CX) with branches (obtuse marginal, posteriolateral and posteriomarginal arteries); and right coronary main stem artery (RCA) with branches (right descending posterior and atrioventricular branch) in terms of normal, stenotic, or comprising diffuse changes in large and/or small coronary arteries or ectasies. A hemodynamically significant stenosis was considered present when diameter stenosis was $\geq 50\%$. Diffuse changes and ectasies were classified as mild, moderate or severe. In occluded vessels, the collateral circulation was also described.

Right heart cardiac catheterization was performed using a standard Swan-Ganz balloon catheter technique.

Dobutamine stress echocardiography: The stress test was performed with the patient in left lateral position. After resting recordings, dobutamine was infused intravenously in 3-minute increments from 5 to 40 $\mu\text{g}/\text{kg}/\text{min}$ in increments of 3 minutes. Ultrasound digital images from 3 apical and 2 parasternal views were obtained (CFM 750, GE Vingmed Sound, Horten, Norway) at baseline, at dobutamine 10 and 20 $\mu\text{g}/\text{kg}/\text{min}$ and at peak stress. The images were transferred as cine-loops to a computer (Macintosh PowerMac, Apple Computers, Cupertino, California) for subsequent analysis (29). We have previously demonstrated the improved accuracy by use of this approach (30). Dobutamine test was not started if systolic or diastolic blood pressures were above 200 or 110 mmHg. The test was completed at peak stress defined as the occurrence of either 1) new or worsened wall motion abnormality; 2) heart rate $\geq 85\%$ of age determined maximum ($220 - \text{age in years}$); 3) severe hypertension with either systolic or diastolic blood pressure above 200 and 110 mmHg, respectively; 4) significant patient

discomfort, or 5) peak dobutamine dose (40 $\mu\text{g}/\text{kg}/\text{min}$). Brachial artery blood pressures were obtained every minute (Dinamap 1846 SXP, Critikon inc., Tampa, FL), and 12 channel electrocardiograms every 3 minutes during test.

Image analysis was performed off-line by comparing wall motion and thickening in 16 left ventricular segments at baseline and during test by an experienced observer blinded for patient data. A score was assigned to each of 16 left ventricular segments excluding the apical cap (31, 32), where normal wall motion and thickening scored 1, hypokinesia 2, akinesia 3, dyskinesia 4, and aneurysm 5. Intermediate scores, i.e. 1.5, 2.5, and 3.5, were allowed to better define the severity of wall motion abnormality. Resting wall motion abnormality was defined as a score ≥ 2 in ≥ 1 segment at baseline. Reversible myocardial ischemia was defined as new or progressing wall motion abnormality during test in ≥ 1 segment. Irreversible injury was defined as segments with a baseline score ≥ 2 without improvement during test.

The analysis was repeated by a blinded second observer for assessment of inter-observer repeatability.

Dobutamine stress SPET (99mTechnetium-tetrofosmin myocardial perfusion imaging):

Baseline perfusion registrations were first obtained. After an overnight fast, 250 MBq 99m Technetium-tetrofosmin (MyoviewTM, Amersham, Buckinghamshire, UK) were intravenously administered to patients with bodyweight below 75 kg, else 300 MBq was given. Single photon emission tomography (SPET) was performed 1 hour later using a dual-head gamma camera with detectors fixed at 90^o (CardialTM, Elscint, Haifa, Israel). Thirty projections of 25 s were acquired over 180^o, extending from 45^o right anterior oblique to 45^o left posterior oblique in step-and-shoot mode. Later the same day, patients underwent a dobutamine stress test protocol identical with that used for the stress echocardiography tests. At 1.5 minute at peak dobutamine dose, the infusion was briefly terminated and a second dose of 750 MBq (<75 kg) or 900 MBq (≥ 75 kg) was injected intravenously, before the

dobutamine infusion was resumed for the final minute. Following 30 - 60 minutes after test termination, a second SPET was performed.

Image processing and analysis was performed on the APEX Expert System (Elscent) with the CEqualTM software to produce short-axis, vertical and horizontal long-axis tomographic slices, bull's eye plot and 3D images of the left ventricle. The CEqualTM software quantifies rest and dobutamine stress distribution of the radionuclide for the short-axis myocardial tomograms, and compares the count distribution values to those observed in a normal group of patients. Quantification was made for the total myocardium as well as the individual vascular regions. In addition to the CEqualTM analysis, an experienced observer unaware of the results of the other noninvasive tests and cardiac catheterization performed a visual reading from the computer screen. Whenever quantification and qualitative analysis were discordant, the qualitative visual reading was given priority.

Exercise ECG test: Maximal symptom-limited (general or leg fatigue, shortness of breath or lightheadedness) exercise testing was performed using an electrically braked bicycle ergometer. The test protocol was individualized using a starting load of 20-50W increasing by 20-50W every second minute until exhaustion (defined as an inability to keep pedaling rate at steady 60 rpm). Simultaneous gas exchange and hemodynamic monitoring were performed. Ventilatory oxygen uptake (VO_2) was measured using the EOS/SPRINT system (E. Jaeger, GmbH CoKG, Wurtzburg, Germany). Gas exchange data were measured with a mixing chamber and recorded every 30 s. Oxygen uptake, carbon dioxide output (VCO_2), minute ventilation (VE), and respiratory exchange ratio (RER) were calculated on-line. Peak oxygen uptake (peak VO_2) was defined as the highest VO_2 achieved during exercise. Age-predicted maximal oxygen uptake was calculated according to the equation of Wassermann (33). Heart rate was recorded continuously from an ECG and blood pressure recorded before, during exercise, and throughout the recovery period. Subjective perception of fatigue (Borg 6-20 scale) was recorded throughout exercise. Exercise test was terminated at either of: patient

exhaustion, typical chest pain, significant ST segment depression (≥ 2 mm measured 0.8 s after J-point), significant arrhythmias, or hypotension (drop in systolic blood pressure >20 mmHg). A test positive for ischemia was defined by a typical change in 2 or more electrocardiogram leads with ST segment depression above 1 mm as measured 0.8 s after J-point on the QRS complex and or major changes in the T-wave vector. Right bundle branch block with typical rSR pattern in V1 was defined as complete when QRS duration was at least 0,12 s, else defined incomplete.

Cost-analysis: The variable and basic cost for each of the four diagnostic methods was estimated on the basis of accountancy data from Oslo University Hospital. In addition, the following assumptions were made: 1. Personnel cost including overhead was for physician set to 1000 NOK per hour, and for technician 500 NOK per hour; 2. Equipment cost, estimated equipment lifetime, maintenance cost, and average number of exams per equipment per working day were obtained from in-house information; 3. Cost of single-use equipment and medication were derived from hospital accountancy; 4. Housing costs were assumed equal for the methods. The additional cost by a coronary angiography-only based strategy per false negative exam by any other method was obtained as cost of coronary angiography minus cost of method divided by %false negative exams (34)

Statistical analysis: Results are presented as mean values with standard deviation (SD). The results of the respective noninvasive tests were compared to coronary angiography, with respect to overall test positivity for ischemia and for the location of ischemia related to the typical coronary vessel distribution (Figure 1). In this comparison, coronary stenosis was defined significant when ≥ 1 significant stenosis was present in any of the major epicardial vessels (LAD, CX or RCA), or in any of their major branches. Sensitivity, specificity, positive and negative predictive values, and diagnostic accuracy of each test were determined by conventional methods (35). Inter-observer agreement for stress echocardiography interpretation was assessed by percent agreement.

RESULTS

General characteristics of the patients are given in Table 1. One patient was excluded from stress SPET because of severe hypertension, and for one patient the stress SPET data were lost because of technical problems.

All patients were in sinus rhythm, 16 with normal ECG, 10 with complete and 17 with incomplete right bundle branch blocks, 5 had evidence for old anterior myocardial infarction, and 2 for left ventricular hypertrophy. None had left bundle branch block. Calcium channel antagonists were used by 17 patients, ACE inhibitors by 22, furosemide by 12, alpha-adrenergic receptor blockers by 5 and beta-adrenergic receptor blockers by 3 patients.

Cardiac catheterization (Table 2): Left ventricular systolic function was generally well preserved with normal average values for ejection fraction and end-diastolic pressure. Only one patient had reduced ejection fraction (< 50%), and two had severely elevated filling pressures (end-diastolic pressures >20 mmHg). In all, 18 patients (36.0%) had significant stenosis on ≥ 1 of the three major epicardial vessels, 23 (46.0%) had diffuse changes in major vessels and 16 (32.0%) in peripheral vessels, 28 (56.0%) had signs of ectatic vessels, 3 (6.0%) had fistulas between coronary vessels and right ventricle, and 3 (6.0%) had intracoronary stents. Sixteen patients (32.0%) had completely normal angiograms. Right heart and pulmonary artery pressures were normal, and cardiac index was mildly reduced.

Dobutamine stress echocardiography: The dobutamine stress response was adequate (Table 3), and all but 2 patients reached $\geq 95\%$ of age predicted maximal heart rate, and only 2 patients received atropine. None experienced chest pain or showed ischemic ECG changes during test. One patient experienced a brief episode of atrial flutter at high doses of dobutamine, and one had a brief sinus arrest, both episodes rapidly normalized after

termination of infusion. Four patients had mild flushing symptoms; else there were no adverse reactions during test.

Resting wall motion abnormalities in ≥ 1 segment were present in 37 (74.0%) patients, 17 (34.0%) in the LAD region exclusively. Irreversible injury in ≥ 1 segment was present in 17 (34.0%) patients, 14 (28.0%) in the LAD region. Overall resting wall motion was moderately impaired (Table 3). Reversible ischemia in ≥ 1 segment was found in 16 patients (32.0%), 10 (20.0%) comprising the LAD region. Sensitivity for significant coronary stenosis was good and specificity high (Table 4). Although specificity for stenoses in the different coronary distributions also was high (LAD 85%, CX 98%, and RCA 93%), sensitivity was lower (LAD 44%, RCA 63%). Only 3 (6.0%) had stenosis in CX, neither identified with doBECHO.

DobECHO identified reversible ischemia in 4 of 6 patients with 2-vessel disease, and in 6 of 8 with single vessel disease. In the 10 patients with complete right bundle branch blocks, doBECHO was correct in 6 and false positive in 4.

The inter-observer agreement for interpretation of doBECHO was for reversible ischemia in ≥ 1 segment 74%. For the specific coronary distributions, agreement was 72% for ischemia in the LAD region, 74% in CX and 72% in the RCA region. The overall agreement for irreversible injury, i.e. scar tissue was 84% (80% in the LAD region, 92% in the CX and 88% in the RCA).

Dobutamine SPET test: Test response was adequate with average peak heart rate slightly above age predicted heart rate maximum (Table 3). None had chest pain or arrhythmias during test. Except mild flushing symptoms (14 patients) and mild headache (3 patients), there were no adverse reactions during test.

Resting perfusion abnormalities were found in anterior wall in 10 patients (20.8%) and in inferior wall in 7 (14.6%). Evidence for irreversible injury, i.e. fibrosis, was present in 13 (27.1%) patients, 9 (18.8%) in the LAD region, 2 (4.2%) in the CX region, and 9 (18.8%) in

the RCA region, affecting $16\pm 9\%$ of the myocardium. Nineteen patients (39.6%) had evidence for reversible ischemia (11-22.9%, in the LAD region), and the ischemic region comprised $7\pm 4\%$ of the myocardium. When reversible ischemia on dobSPET was compared to stenosis on angiography, the overall sensitivity and specificity was good (Table 4). Specificity for stenosis in the coronary regions was also high (LAD 85%, CX 93%, and RCA 80%), whereas sensitivity was lower (LAD 63%, RCA 63%). Only 2 had stenosis in CX, neither was identified with dobSPET.

DobSPET test identified reversible ischemia in 4 of 5 patients with 2-vessel disease and in 5 of 8 with single vessel disease. In the 9 patients with complete right bundle branch blocks undergoing dobSPET, the test was correct in 5 and false positive in 4.

Exercise ECG: Test response was considered adequate since all reached anaerobic threshold and had subjective rating of fatigue above Borg scale 16. Peak workload was (mean \pm SD) 132 ± 39 watts, peak minute oxygen uptake was 17.9 ± 4.3 mL/kg/min, and peak R-value was 1.15 ± 0.11 . Peak heart rate was slightly above age predicted maximum (Table 3)

Of 45 patients remitted for exECG, 4 patients (8.9%) could not perform bicycling due to physical disabilities and in 8 (17.8%) ECG was not interpretable for ischemic changes due to complete right bundle branch block in 7 patients and technically inadequate ECG in one. Fifteen patients (33.3%) had incomplete right bundle branch blocks with ECGs found adequate for interpretation. Of the 33 patients completing the test, only 4 (12.1%) had ECG changes positive for myocardial ischemia, i.e. normalization of inverted T wave during test (1 patient), deep T wave inversion and mild ST depression during test (2 patients), and typical ST depression in the inferior wall leads during test (1 patient). Whereas specificity was high, sensitivity was poor (Table 4).

ExECG identified reversible ischemia in none of the 2 patients tested with 2-vessel disease, and in only 2 of 7 with single vessel disease.

Combining information of the tests (Table 5): By combining information from echocardiographic and scintigraphic investigations, sensitivity and negative predictive value improved while specificity and positive predictive value decreased. In all, 37 patients (74.0%) had resting wall motion abnormalities in ≥ 1 segment on echocardiography, and 31 (62.0%) had abnormalities in ≥ 2 segments. Resting perfusion defects were present in 18 (37.5%) patients.

By combining resting wall motion abnormalities (≥ 2 segment) and/or a positive doBECHO, false negative tests were limited to 2 patients, with sensitivity 86% and specificity 47%. The combination of either resting wall motion abnormalities ≥ 2 segment on echocardiography and/or a positive doSPET was present in 36 patients (72.0%) comprising all those with significant coronary stenosis. All patients with normal resting wall motion and a negative doSPET were free of significant coronary stenosis. There were 23 false positives; thus sensitivity was 100% and specificity 34%. The combination of either resting perfusion defects and/or a positive doSPET was present in 22 patients (45.8%), 3 (6.3%) were false negative and 12 (25.0%) false positive, with sensitivity 77% and specificity 66%. The combination of a positive stress echocardiography and/or a positive doSPET was present in 25 patients (52.1%); there were 14 (29.2%) false positives and 2 (4.2%) false negatives, with specificity 60% and sensitivity 85%.

Thus, the combined strategies reduced the number of false negatives and gave high negative predictive values, but low positive predictive values.

Cost analysis

The estimated cost per exam including personnel costs, equipment cost, use of medication and single-use equipment was for doBECHO, doSPET, exECG and coronary angiography NOK 1.961, 4.867, 829, and 3.356, respectively. Of this cost, the equipment cost per exam was

low, i.e. NOK 45, 91, 6, and 57 for the respective methods. Whereas the additional cost by a coronary angiography – only based strategy, is NOK 34873 for each false negative dobECHO with resting wall motion analysis, this strategy is less expensive (> NOK 14500) than any dobSPET based strategy.

DISCUSSION

HTx vasculopathy represents a diagnostic and therapeutic challenge, since it is often asymptomatic and unpredictable in terms of progression rate, severity and clinical consequences. Our present follow-up programme includes a coronary angiography where percutaneous coronary intervention is the recommended treatment of any significant coronary stenosis in a major epicardial artery.

The present study demonstrates that both dobECHO and dobSPET are feasible in HTx patients, whereas exercise test could only be used in 66% due to resting ECG abnormalities. Furthermore, dobECHO and dobSPET had similar and acceptable overall sensitivities for coronary artery stenosis, whereas sensitivity of exECG was as low as 22%. Thus, exECG cannot be used in the screening for allograft vasculopathy.

The accuracy of the noninvasive tests in the present study was slightly lower than that obtained in patients with native ischemic heart disease. For dobECHO, the overall sensitivity was reduced (15, 36, 37), whereas sensitivity for locating the stenoses to the different coronary vessels was even lower (27, 38, 39). This may in part be due to the combination of resting wall motion, bundle branch blocks, diffuse vasculopathy, and reduced ultrasound image quality after thoracotomy in the HTx patients.

The unique pattern of allograft vasculopathy is likely to be of particular significance since it produces diffuse coronary vessel wall affection with peripheral obliterative disease. It is well known that this vasculopathy may not be adequately identified on angiograms (10, 12). Thus, false positive stress tests may be due not only to erroneous interpretation of wall motion or

perfusion patterns, but also to significant stenoses that pass undetected on coronary angiography. It is also known dobECHO elicit wall motion abnormalities in HTx patients without vasculopathy although the mechanism for this is not clear (40). Similarly, false negative stress tests may be caused not only by erroneous stress test interpretation, but also by stenosis in a coronary artery producing ischemia in a very small region if any at all, and finally to an erroneous interpretation of angiograms due to particular interpretation difficulties in these patients. Interestingly, of the 16 patients with completely normal angiograms 14 (87.5%) had normal dobECHO and dobSPET tests.

The particular low accuracy for CX stenosis deserves a comment. Only three patients had significant CX stenosis, two with additional stenosis on RCA stenosis and one on LAD. In two of these, dobECHO correctly indicated reversible ischemia in the RCA and LAD regions, respectively. DobSPET correctly indicated reversible ischemia in RCA region in one patient; one did not perform the test. One patient was false negative on both dobECHO and dobSPET. Two of the three had false negative exECG and one could not perform the test. Whereas the low sensitivity for Cx stenosis is related to the low prevalence, it underscores that the stress tests sensitivity for specific coronary vessels is lower than expected, and should not be used to predict affected vessel in the individual HTx patient.

Bundle branch blocks, particularly right bundle branch block, are prevalent in HTx patients. Whereas the accuracy of dobECHO is maintained in patients with left bundle branch block (41), that of SPET is reduced, mainly due to reduced specificity (25). However, the effects of right bundle branch block on stress tests in HTx patients have not been well documented. We found that 20% of the patients had complete and 36% incomplete right bundle branch blocks. Complete bundle branch block was associated with false positive tests in both dobECHO (4/10) and in dobSPET (4/11) and may in part be explained by the associated abnormal septal movement on echocardiography. Importantly, none of the patients with right bundle branch blocks had false negative stress echocardiography or SPET.

An improved diagnostic accuracy for identification of allograft vasculopathy was recently reported by Ciliberto et al., who combined resting wall motion (≥ 2 segments) on echocardiography with results of dipyridamole stress perfusion testing (28). We found that sensitivity improved while specificity decreased by this approach due to the high prevalence of resting wall motion abnormalities (n=37) and perfusion defects (n=18). For instance, of the 36 patients with either resting wall motion abnormalities ≥ 2 segments and/or positive dobsPET, only 13 (36.1%) had significant coronary artery stenosis. Although sensitivity with this approach was 100%, specificity was as low as 34% due to the many false positive tests (Table 5). The practical consequence of the combined approach would in our patient group, given that the 12/48 patients (25.0%) with normal resting wall motion on echocardiography and a negative dobsPET, would be advised to defer their upcoming yearly angiogram. Patients with either resting wall motion abnormality and/or a positive dobsPET would be advised to have their angiography, and 78% of these would be expected to be without significant coronary stenosis.

A similar consideration holds for the combination of either resting wall motion abnormalities ≥ 2 segments and/or a positive dobsECHO where 19/50 patients would be advised to defer angiograms. Of the 31/50 patients (62.0%) who will be advised annual angiogram, 61% would be expected to have normal angiograms. This approach is, however, considered more practical in clinical routine since all information is obtained from one investigation, i.e. echocardiography, less costly, and does not expose the patient for radiation. Although the number of false positives is reduced when combining the results of dobsECHO with dobsPET, the accuracy was only slightly better. Dobutamine stress testing is considered safe and with minimal patient discomfort (42), the cumulative risk of duplicated repeated pharmacological stress testing raise concern, and in our opinion the minor improvement in diagnostic accuracy does not justify routine use of both dobsECHO and dobsPET in these patients.

Dobutamine stress protocol: Dobutamine stress testing in HTx patients is considered safe (43), although the chronotropic response is often exaggerated as compared to normals (44) and other patient groups (45). This is concordant with our results where all but two reached at least 95% of predicted maximal heart rate and only two were given additional atropine. The dobutamine test protocol was well tolerated in all patients and atropine is rarely needed to achieve predicted maximal heart rate (45).

Clinical implications: Both dobECHO and dobSPET had acceptable accuracy for significant coronary stenosis in HTx patients; both are feasible and can be used with few side effects. Test result in the individual patient should be interpreted as positive vs. negative for reversible ischemia without reference to coronary vessel distribution. ExECG cannot be used as a diagnostic test for coronary artery disease in these patients. DobECHO is the by far the most cost-efficient method. In fact, the cost of dobSPET in fact exceeded that of coronary angiography by 45%. DobSPET and coronary angiography exposes the patient for a similar level of radiation. Thus, the long term risk of developing radiation-related cancer should be similar in dobSPET and coronary angiography, however, the risk of acute complications is in principle restricted to the latter method.

Thus, the present study supports dobECHO and not dobSPET testing as an interim supplement for coronary angiography. Although, the cost of coronary angiography is 70% above that of dobECHO, the expense per exam is still moderate and probably not high enough to argue against annual use in this selected patient group. On the other hand, the calculated cost given here is based on plain routine coronary angiograms. Recently, new catheter-based techniques e.g. intracoronary pressure measurements and intracoronary ultrasound (IVUS) have been increasingly used, and adds to cost.

Choice of strategy for noninvasive screening for coronary stenosis in these patients depend on whether the aim is either to identify all patients with coronary stenoses (higher sensitivity) or whether it is to reduce the number of unnecessary coronary angiographies (higher specificity). For the first strategy (higher sensitivity), dobECHO should be combined with

echocardiographic assessment of resting wall motion abnormalities. A practical clinical algorithm (Figure 1) for a patient with normal coronary angiography at last annual follow-up would then be to first evaluate resting wall motion on echocardiography. If resting wall motion is abnormal, coronary angiography should be advised. If resting wall motion is normal, the patient progresses to dobECHO. If dobECHO is positive, coronary angiography is advised, if not, angiography is declined.

For the second strategy (higher specificity), dobECHO alone would be the best option. If test result is positive for ischemia, coronary angiography is advised, if not, it is deferred.

Conclusion: Both dobECHO and dobSPET are feasible and have acceptable accuracy for detecting angiographically significant coronary stenosis in HTx patients. ExECG cannot be used for this purpose. DobECHO has the lowest cost and represents the least hazard for the patient. Depending on strategy for screening for coronary stenosis, dobECHO combined with echocardiographic resting wall motion assessment, can with acceptable accuracy help selecting patients for whom coronary angiography may be deferred.

REFERENCES

1. Smith-Bindman R, Miglioretti DL, Larson EB. Rising use of diagnostic medical imaging in a large integrated health system. *Health affairs* 2008;27:1491-502
2. Iglehart JK. The new era of medical imaging--progress and pitfalls. *N Engl J Med* 2006;354:2822-8
3. Brindis RG, Douglas PS, Hendel RC, Peterson ED, Wolk MJ, Allen JM, et al. ACCF/ASNC appropriateness criteria for single-photon emission computed tomography myocardial perfusion imaging (SPECT MPI). *J Am Coll Cardiol* 2005;46:1587-605
4. Berrington de Gonzalez A, Darby S. Risk of cancer from diagnostic X-rays: estimates for the UK and 14 other countries. *Lancet* 2004;363:345-51
5. Werner N, Zahn R, Zeymer U. Stroke in patients undergoing coronary angiography and percutaneous coronary intervention: incidence, predictors, outcome and therapeutic options. *Exp Rev Cardiovasc Ther* 2012;10:1297-305
6. Klauss V, Ackermann K, Spes CH, Zeitlmann T, Henneke KH, Werner F, et al. Coronary plaque morphologic characteristics early and late after heart transplantation: in vivo analysis with intravascular ultrasonography. *Am Heart J* 1997;133:29-35
7. Gao SZ, Alderman EL, Schroeder JS, Silverman JF, Hunt SA. Accelerated coronary vascular disease in the heart transplant patient: coronary arteriographic findings. *J Am Coll Cardiol* 1988;12:334-40
8. Kaye MP. The Registry of the International Society for Heart and Lung Transplantation: tenth official report--1993. *The Journal of heart and lung transplantation : the official publication of the International Society for Heart Transplantation*. 1993;12(4):541-8. Epub 1993/07/01.
9. Rickenbacher PR, Kemna MS, Pinto FJ, Hunt SA, Alderman EL, Schroeder JS, et al. Coronary artery intimal thickening in the transplanted heart. An in vivo intracoronary ultrasound study of immunologic and metabolic risk factors. *Transplantation* 1996;61:46-53
10. Johnson DE, Alderman EL, Schroeder JS, Gao SZ, Hunt S, DeCampi WM, et al. Transplant coronary artery disease: histopathologic correlations with angiographic morphology. *J Am Coll Cardiol* 1991;17:449-57
11. Syeda B, Roedler S, Schukro C, Yahya N, Zuckermann A, Glogar D. Transplant coronary artery disease: Incidence, progression and interventional revascularization. *Int J Cardiol* 2005;104:269-74
12. Spes CH, Klauss V, Mudra H, Schnaack SD, Tammen AR, Rieber J, et al. Diagnostic and prognostic value of serial dobutamine stress echocardiography for noninvasive assessment of cardiac allograft vasculopathy: a comparison with coronary angiography and intravascular ultrasound. *Circulation* 1999;100:509-15

13. Marcovitz PA, Armstrong WF. Accuracy of dobutamine stress echocardiography in detecting coronary artery disease. *Am J Cardiol* 1992;69:1269-73
14. Mazeika PK, Nadazdin A, Oakley CM. Dobutamine stress echocardiography for detection and assessment of coronary artery disease. *J Am Coll Cardiol* 1992;19:1203-11
15. Marwick T, Willemart B, D'Hondt AM, Baudhuin T, Wijns W, Detry JM, et al. Selection of the optimal nonexercise stress for the evaluation of ischemic regional myocardial dysfunction and malperfusion. Comparison of dobutamine and adenosine using echocardiography and ^{99m}Tc-MIBI single photon emission computed tomography. *Circulation* 1993;87:345-54
16. Akosah K, Olsovsky M, Mohanty PK. Dobutamine stress-induced angina in patients with denervated cardiac transplants. Clinical and angiographic correlates. *Chest* 1995;108:695-700
17. Larsen RL, Applegate PM, Dyar DA, Ribeiro PA, Fritzsche SD, Mulla NF, et al. Dobutamine stress echocardiography for assessing coronary artery disease after transplantation in children. *J Am Coll Cardiol* 1998;32:515-20
18. Derumeaux G, Redonnet M, Mouton-Schleifer D, Bessou JP, Cribier A, Saoudi N, et al. Dobutamine stress echocardiography in orthotopic heart transplant recipients. VACOMED Research Group. *J Am Coll Cardiol* 1995;25:1665-72
19. Herregods MC, Anastassiou I, Van Cleemput J, Bijmens B, De Geest H, Daenen W, et al. Dobutamine stress echocardiography after heart transplantation. *J Heart Lung Transplant* 1994;13:1039-44
20. Ciliberto GR, Massa D, Mangiavacchi M, Danzi GB, Pirelli S, Faletta F, et al. High-dose dipyridamole echocardiography test in coronary artery disease after heart transplantation. *Eur Heart J* 1993;14:48-52
21. Di Filippo S, Semiond B, Roriz R, Sassolas F, Raboisson MJ, Bozio A. Non-invasive detection of coronary artery disease by dobutamine-stress echocardiography in children after heart transplantation. *J Heart Lung Transplant* 2003;22:876-82
22. Bacal F, Moreira L, Souza G, Rodrigues AC, Fiorelli A, Stolf N, et al. Dobutamine stress echocardiography predicts cardiac events or death in asymptomatic patients long-term after heart transplantation: 4-year prospective evaluation. *J Heart Lung Transplant* 2004;23:1238-44
23. Legare JF, Haddad H, Barnes D, Sullivan JA, Buth KJ, Hirsch G. Myocardial scintigraphy correlates poorly with coronary angiography in the screening of transplant arteriosclerosis. *Can J Cardiol* 2001;17:866-72

24. Smart FW, Ballantyne CM, Cocanougher B, Farmer JA, Sekela ME, Noon GP, et al. Insensitivity of noninvasive tests to detect coronary artery vasculopathy after heart transplant. *Am J Cardiol* 1991;67:243-7
25. Mairesse GH, Marwick TH, Arnese M, Vanoverschelde JL, Cornel JH, Detry JM, et al. Improved identification of coronary artery disease in patients with left bundle branch block by use of dobutamine stress echocardiography and comparison with myocardial perfusion tomography. *Am J Cardiol* 1995;76:321-5
26. Verhoeven PP, Lee FA, Ramahi TM, Franco KL, Mendes de Leon C, Amatruda J, et al. Prognostic value of noninvasive testing one year after orthotopic cardiac transplantation. *J Am Coll Cardiol* 1996;28:183-9
27. Elhendy A, Sozzi FB, van Domburg RT, Vantrimpont P, Valkema R, Krenning EP, et al. Accuracy of dobutamine tetrofosmin myocardial perfusion imaging for the noninvasive diagnosis of transplant coronary artery stenosis. *J Heart Lung Transplant* 2000;19:360-6.
28. Ciliberto GR, Ruffini L, Mangiavacchi M, Parolini M, Sara R, Massa D, et al. Resting echocardiography and quantitative dipyridamole technetium-99m sestamibi tomography in the identification of cardiac allograft vasculopathy and the prediction of long-term prognosis after heart transplantation. *Eur Heart J* 2001;22:964-71
29. Bjornstad K, Aakhus S, Hatle L. Digital high frame rate stress echocardiography for detection of coronary artery stenosis by high dose dipyridamole stress testing. *Int J Card Imag* 1995;11:163-70
30. Bjornstad K, Aakhus S, Hatle L. Comparison of digital dipyridamole stress echocardiography and upright bicycle stress echocardiography for identification of coronary artery stenosis. *Cardiology* 1995;86:514-20
31. Schiller NB, Shah PM, Crawford M, DeMaria A, Devereux R, Feigenbaum H, et al. Recommendations for quantitation of the left ventricle by two-dimensional echocardiography. American Society of Echocardiography Committee on Standards, Subcommittee on Quantitation of Two-Dimensional Echocardiograms. *J Am Soc Echocardiogr* 1989;2(5):358-67
32. Cerqueira MD, Weissman NJ, Dilsizian V, Jacobs AK, Kaul S, Laskey WK, et al. Standardized myocardial segmentation and nomenclature for tomographic imaging of the heart. A statement for healthcare professionals from the Cardiac Imaging Committee of the Council on Clinical Cardiology of the American Heart Association. *Circulation* 2002;105:539-42
33. Wasserman K, Hansen JE, Sue DY. Principles of exercise testing and interpretation. 3 ed. Baltimore: Lippincott, Williams and Wilkins; 1999.

34. Armstrong GT, Plana JC, Zhang N, Srivastava D, Green DM, Ness KK, et al. Screening adult survivors of childhood cancer for cardiomyopathy: comparison of echocardiography and cardiac magnetic resonance imaging. *J Clin Oncol* 2012;30:2876-84
35. Altman DG. *Practical statistics for medical research*. London: Chapman and Hall; 1991.
36. Cohen JL, Greene TO, Ottenweller J, Binenbaum SZ, Wilchfort SD, Kim CS. Dobutamine digital echocardiography for detecting coronary artery disease. *Am J Cardiol* 1991;67:1311-8
37. McNeill AJ, Fioretti PM, el-Said SM, Salustri A, Forster T, Roelandt JR. Enhanced sensitivity for detection of coronary artery disease by addition of atropine to dobutamine stress echocardiography. *Am J Cardiol* 1992;70:41-6
38. Segar DS, Brown SE, Sawada SG, Ryan T, Feigenbaum H. Dobutamine stress echocardiography: correlation with coronary lesion severity as determined by quantitative angiography. *J Am Coll Cardiol* 1992;19:1197-202
39. Takeuchi M, Araki M, Nakashima Y, Kuroiwa A. Comparison of dobutamine stress echocardiography and stress thallium-201 single-photon emission computed tomography for detecting coronary artery disease. *J Am Soc Echocardiogr* 1993;6:593-602
40. Jackson PA, Akosah KO, Kirchberg DJ, Mohanty PK, Minisi AJ. Relationship between dobutamine-induced regional wall motion abnormalities and coronary flow reserve in heart transplant patients without angiographic coronary artery disease. *J Heart Lung Transplant* 2002;21:1080-9
41. Geleijnse ML, Vigna C, Kasprzak JD, Rambaldi R, Salvatori MP, Elhendy A, et al. Usefulness and limitations of dobutamine-atropine stress echocardiography for the diagnosis of coronary artery disease in patients with left bundle branch block. A multicentre study. *Eur Heart J* 2000;21:1666-73
42. Mertes H, Sawada SG, Ryan T, Segar DS, Kovacs R, Foltz J, et al. Symptoms, adverse effects, and complications associated with dobutamine stress echocardiography. Experience in 1118 patients. *Circulation* 1993;88:15-9
43. Akosah KO, Denlinger B, Mohanty PK. Safety profile and hemodynamic responses to beta-adrenergic stimulation by dobutamine in heart transplant patients. *Chest* 1999;116:1587-92.
44. Gerber BL, Bernard X, Melin JA, Delestinne T, Vanbutsele R, Goenen M, et al. Exaggerated chronotropic and energetic response to dobutamine after orthotopic cardiac transplantation. *J Heart Lung Transplant* 2001;20:824-32

45. Flox A, Sanchez V, Delgado JF, Fernandez S, Tello R, Jimenez J, et al. Is atropine infusion necessary to achieve the target heart rate in heart transplant patients during dobutamine stress echocardiography? *Transpl proc* 2002;34:3241-2

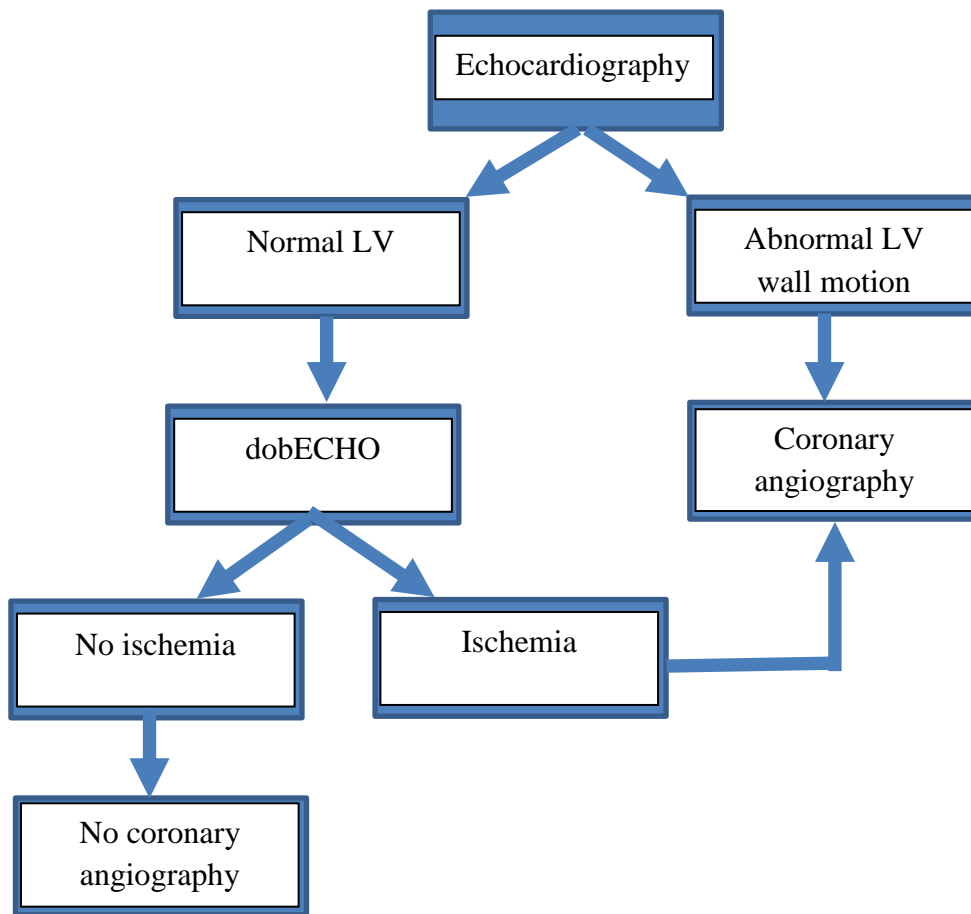


Figure 1. Proposed “high sensitivity” algorithm for selection of heart transplantation to coronary angiography based on echocardiographic evaluation of left ventricular (LV) wall motion at annual follow-up (see text).

Table 1. General patient characteristics.

Gender F/M	3 / 47
Age (years)	57 ± 8
Time since heart Tx (years)	6,3 ± 3,3
Body mass index (kg/m ²)	26,4 ± 3,5
Systemic hypertension (%)	80%
Systolic blood pressure (mmHg)	145 ± 21
Diastolic blood pressure (mmHg)	93 ± 15
Hemoglobin (g/100mL)	13,3 ± 1,5
Creatinine (mmol/L)	118 ± 37
Cyclosporine A (nmol/L)	124 ± 29

Mean values±SD or per cent (%).

Table 2. Cardiac catheterization data.

Left heart catheterization:

Left ventricular ejection fraction, n=45 (%)	73 ± 12
Left ventricular end-diastolic pressure (mmHg)	12 ± 5
Coronary artery diameter stenosis ≥50%*	14
1-vessel disease*	8
2-vessel disease*	6
Patients with LAD stenosis (N)*	9
Patients with CX stenosis (N)*	3
Patients with RCA stenosis (N)*	8

Right heart catheterization:

Pulmonary capillary wedge pressure (mmHg)	9 ± 3
Mean pulmonary artery pressure (mmHg)	17 ± 4
Right atrial pressure (mmHg)	5 ± 3
Cardiac index (L/m ²)	2,6 ± 0,6
Pulmonary arterial resistance (Woods units)	1,6 ± 0,7

*Values are mean±SD or per cent (%). * Number of patients. LAD = Left anterior descending coronary artery, CX = circumflex coronary artery, RCA = right coronary artery.*

Table 3. Hemodynamic response during stress testing in stable heart transplant patients.

	dobECHO (n=50)			dobSPET (n=48)			ExECG (n=33)		
Peak dose DOB ($\mu\text{g}/\text{kg}/\text{min}$)	29	\pm	9	27	\pm	9	-		
BL HR (b/min)	90	\pm	13	85	\pm	13	103	\pm	13
Peak HR (b/min)	145	\pm	8	140	\pm	12	150	\pm	19
% increase in HR	64	\pm	26	69	\pm	27	47	\pm	21
HR in % of max*	105	\pm	6	101	\pm	8	109	\pm	13
BL SBP (mmHg)	133	\pm	27	145	\pm	18	128	\pm	21
Peak SBP (mmHg)	131	\pm	25	158	\pm	23	185	\pm	30
% increase in SBP	0	\pm	19	9	\pm	16	41	\pm	32
Peak HRxSBP	19031	\pm	3692	22062	\pm	3629	28493	\pm	6721
% increase in HRxSBP	66	\pm	42	85	\pm	42	118	\pm	54
BL WMSI (units)	1,22	\pm	0,24	-			-		
Peak WMSI (units)	1,15	\pm	0,21	-			-		

*dobECHO= Dobutamine stress echocardiography; dobSPET=Dobutamine stress Tc SPET; ExECG=Bicycle ergometer exercise ECG; HR=Heart rate; SBP=Systolic blood pressure; *max=estimated maximal HR (220-age(years)); BL WMSI=Baseline wall motion score index. Values are mean \pm SD.*

Table 4. Detection of coronary artery stenosis (CAD) by noninvasive stress tests in stable heart transplant patients.

	dobECHO		dobSPET		exECG	
	(n=50)		(n=48)		(n=33)	
	+	-	+	-	+	-
CAD +	12	6	12	5	2	8
CAD -	3	29	8	23	2	21
Sensitivity (%)	67		71		20	
Specificity (%)	91		74		91	
Accuracy (%)	82		73		70	
Positive predictive value (%)	80		60		50	
Negative predictive value (%)	83		82		72	

Boxes comprise numbers of patients. CAD: significant stenosis on coronary angiography of $\geq 50\%$ diameter stenosis in a major coronary artery or any of its major branches. Abbrev. as in Table 3.

Table 5. Effect on diagnostic accuracy of detection of coronary artery stenosis (CAD) in stable heart transplant patients by combining information from the noninvasive tests.

	WMA BL echo + dobECHO (n=50)		WMA BL echo + dobSPET (n=48)		SPET BL abn + dobSPET (n=48)		dobECHO + dobSPET (n=48)	
	+	-	+	-	+	-	+	-
CAD +	12	2	13	0	10	3	11	2
CAD -	19	17	23	12	12	23	14	21
Sensitivity (%)	86		100		77		85	
Specificity (%)	47		34		66		60	
Accuracy (%)	58		52		69		67	
Pos. predictive value (%)	39		36		45		44	
Neg. predictive value (%)	89		100		88		91	

Boxes comprise numbers of patients. CAD: significant stenosis on coronary angiography of $\geq 50\%$ diameter stenosis in a major coronary artery or any of its major branches. WMA BL echo: Wall motion abnormality on resting echocardiography ≥ 2 segments; SPET BL abn: perfusion abnormalities on resting SPET. Other abbrev. as in Table 3.