

# Hemiarthroplasty and femoral neck fractures



Thesis

Paul Wender Figved

Orthopaedic Department, Oslo University Hospital, Ullevål

Orthopaedic Department, Asker and Bærum Hospital

University of Oslo, Institute of Clinical Medicine

Faculty of Medicine

University of Oslo

2010

© **Paul Wender Figved, 2010**

*Series of dissertations submitted to the  
Faculty of Medicine, University of Oslo  
No. 981*

ISBN 978-82-8072-624-7

All rights reserved. No part of this publication may be reproduced or transmitted, in any form or by any means, without permission.

Cover: Inger Sandved Anfinsen.  
Printed in Norway: AiT e-dit AS.

Produced in co-operation with Unipub.  
The thesis is produced by Unipub merely in connection with the thesis defence. Kindly direct all inquiries regarding the thesis to the copyright holder or the unit which grants the doctorate.

## Table of Contents

<b>Acknowledgements</b> .....	<b>5</b>
<b>List of abbreviations</b> .....	<b>7</b>
<b>List of papers with brief summary</b> .....	<b>9</b>
Paper 1 .....	9
Paper 2 .....	9
Paper 3 .....	10
Paper 4 .....	10
<b>Background</b> .....	<b>13</b>
<b>Definition of hip fractures</b> .....	<b>13</b>
<b>Definition of femoral neck fractures</b> .....	<b>14</b>
<b>Epidemiology</b> .....	<b>14</b>
<b>Diagnosis</b> .....	<b>14</b>
<b>Classification</b> .....	<b>15</b>
<b>Treatment</b> .....	<b>16</b>
Internal fixation .....	16
Hemiarthroplasty.....	17
Total hip arthroplasty.....	17
<b>The history and diversity of hemiarthroplasties</b> .....	<b>19</b>
The evolution of hemiarthroplasty – unipolar and bipolar prostheses .....	20
Cemented or uncemented hemiarthroplasty.....	21
Cement-related complications and death .....	22
<b>Aim of the studies</b> .....	<b>25</b>
<b>Patients</b> .....	<b>27</b>
Paper 1 – A retrospective study.....	27
Paper 2 – A register study .....	27
Paper 3 – A randomised controlled trial.....	27
Paper 4 – A phantom model study followed by a randomised controlled trial .....	28
<b>Methods</b> .....	<b>29</b>
<b>Treatment</b> .....	<b>29</b>
<b>Outcome measures</b> .....	<b>29</b>
Harris Hip Score .....	30
Barthel Index .....	30
EQ-5D .....	30
<b>Radiostereometric analysis (RSA)</b> .....	<b>31</b>
Phantom model study.....	31
<b>Statistical methods</b> .....	<b>32</b>
<b>Main results</b> .....	<b>35</b>
<b>Discussion</b> .....	<b>37</b>
<b>Methods</b> .....	<b>37</b>
<b>General discussion</b> .....	<b>38</b>
<b>Conclusions</b> .....	<b>43</b>
<b>Suggestions for further research</b> .....	<b>45</b>

<b>Reference list .....</b>	<b>47</b>
<b>Appendix 1 – Norwegian Arthroplasty Register forms.....</b>	<b>57</b>
<b>Appendix 2 – English and Norwegian Harris Hip Score.....</b>	<b>63</b>
<b>Appendix 3 – English and Norwegian Barthel Index .....</b>	<b>67</b>
<b>Appendix 4 – English and Norwegian EQ-5D .....</b>	<b>71</b>
<b>Appendix 5 – Paper 1-4.....</b>	<b>77</b>



## Acknowledgements

Asbjørn Hjall gave me my first job at the Orthopaedic Department at Asker and Bærum Hospital and has, since then, encouraged me and facilitated all my research work with great enthusiasm and a seemingly endless faith in me both as a surgeon and as a researcher.

Gudleik Dale introduced me to hip surgery very early in my career and was probably one of the first orthopaedic surgeons in Norway suggesting that far more patients with femoral neck fractures should be treated with hemiarthroplasty, also encouraging me to explore this field of research. Finnur Snorrason and Tore Jervidalo inspired me during my internship year at Buskerud sentralsykehus in Drammen. Fortunately, I have had the privilege of working with them both again, Tore at Asker and Bærum Hospital and Finnur at Ullevål University Hospital. Tore served as my local supervisor at Asker and Bærum hospital. Finnur was head of prosthetic surgery at Ullevål and supervised the important phantom model study leading to the planning, design, and methodology of paper 4.

The entire staffs at both hospitals have contributed with recruitment of patients, surgery and follow-up of patients. The expansive force of PhD students at Ullevål have provided indispensable support, among them Jon Dahl, Ola Wig, Marianne Westberg, Berte Bøe, Peter Grant, Annette Wikerøy, Elisabeth Ellingsen Husebye, Sverre Løken, Sigbjørn Dimmen and Hilde Apold. Also thanks to the residents and consultant orthopaedic surgeons at both hospitals including Dagfinn Bjørkøy, Vidar Opland, Ragnar Groenhof, Bjarne Grøgaard, Odd Arve Lien, Ole Koppang, Per William Bratlie-Jensen, Vinh Tran, Roger Trana, Petter Iversen, Ellen Aksnes, Gunnar Flugsrud, Geir Andreassen, Vera Halvorsen, Stephan Röhl, Kirsten Lundgreen, Anders Walløe, Olav Røyse and professor Lars Engebretsen.

Extensive thanks goes to research coordinators Merete Finjarn and Camilla Andersen at Baerum, and Karen Bjørø and Kenneth Nilsen at Ullevål, who have played a crucial role in conducting follow-up examinations of patients. I would also like to extend great thanks to Alexis Hinojosa and Mona Risdal for perfect RSA services at the radiological department, and to Sigmund Oswald for conducting ambulant radiographic examinations. Special thanks to our leader of the orthopaedic department at Bærum sykehus Wenche Sørensen, she is genuinely interested in the well-being of her employees and a great leader.

Although never a formally appointed supervisor, Frede Frihagen has been serving as what may best be described as my older brother in hip fracture research. His omnipresence at Ullevål and his dedication to do great orthopaedic research is a massive inspiration to everyone fortunate to have worked with him.

Most important, I have had the privilege of working with two extremely dedicated, enthusiastic and supportive professors: My supervisors Lars Nordsletten and Jan Erik Madsen have together provided an invaluable creative force, priceless discussions and debates, and hours of reading and revising my manuscripts. They have been easily available and always helpful, and have fulfilled their role as supervisors in the very meaning of the word supervise: Observing and directing rather than instructing, always pointing me in the right directions.

I would also like to thank my parents Inger and Odd Figved for letting me do almost everything I have wanted to do during my 36-year-old life and my sister Margrethe for being my older sister and a good friend.

Finally, and always most important in my life, is my wife Edda. I want to thank her for her unconditional and endless love and support, and our two wonderful daughters, Frida and Alma. They may not be able to read this thesis just yet, but I dedicate it to them both.

## List of abbreviations

ADL	Activities of daily living
ASA	American Society of Anesthesiologists
CI	Confidence interval
CoCr	Cobalt Chromium
EQ-5D	The five-dimensional scale of EuroQol
EQ-VAS	The visual analogue scale of EuroQol
HA	Hydroxyapatite
HHS	Harris hip score
ml	Millilitres
n	Number
NAR	Norwegian Arthroplasty Register
NHFR	Norwegian Hip Fracture Register
OA	Osteoarthritis
RCT	Randomised controlled trial
RR	Relative risk
RSA	Radiostereometric analyses
THA	Total hip arthroplasty



## List of papers with brief summary

### **Paper 1**

*Figved W, Norum OJ, Frihagen F, Madsen JE, Nordsletten L.*

*Interprosthetic dislocations of the Charnley/Hastings hemiarthroplasty - report of 11 cases in 350 consecutive patients. Injury 2006; Feb; 37(2):157-161.*

350 consecutive patients treated with a bipolar hemiarthroplasty for an acute femoral neck fracture was examined retrospectively. 14 patients (4.0%) had a dislocation of the prosthesis. 11 of these were dislocations between the two prosthetic components, usually referred to as an interprosthetic dislocation, diagnosed at 18 (4-64) days after insertion of the prosthesis. Very few cases describing this type of dislocation has been reported in the literature, and may be caused by either an assembly mistake perioperatively, by maximum angulation and impingement between the components, or by trauma. The median age of the 350 patients was 79 (36-99) and the median age of the 11 patients with an interprosthetic dislocation was 85 years (82-94). The manufacturer examined one retrieved prosthetic head and no irregularities were found. Only five of the 11 patients underwent a successful reduction or reoperation of the prosthesis, three died during hospitalisation, two patients had the prosthesis removed and one refused treatment accepting a permanently dislocated prosthesis. Mechanical failure after hemiarthroplasty of the hip is in most cases a devastating complication.

### **Paper 2**

*Figved W, Dybvik E, Frihagen F, Furnes O, Madsen JE, Havelin LI, Nordsletten L.*

*Conversion from failed hemiarthroplasty to total hip arthroplasty: a Norwegian Arthroplasty Register analysis of 595 hips with previous femoral neck fractures. Acta Orthop. 2007 Dec;78(6):711-718.*

Between 1987 and 2004, 595 total hip replacements were reported to the Norwegian Arthroplasty Register as conversion from a failed hemiarthroplasty after a femoral neck fracture, in patients aged 60 years and older. 122 operations left the femoral stem intact and 473 were converted with exchange of the femoral stem. We found a lower risk of failure (revision surgery for any reason) for the conversion procedures with stem exchange than for the conversion procedures that retained the femoral stem. For the conversion procedures with

exchange of the stem, we found no difference in risk of failure compared to all revision femoral stems in the register. For the conversion procedures where the femoral stem was retained, we found a significantly increased risk of failure for both the complete prosthesis and for the acetabular cup compared to primary hip arthroplasties in the Register. We concluded that implanting an acetabular cup to convert a hemiarthroplasty to a total hip arthroplasty is an uncertain procedure, and that the threshold for replacing the stem should be low.

### **Paper 3**

*Figved W, Opland V, Frihagen F, Jervidal T, Madsen JE, Nordsletten L.*

*Cemented versus uncemented hemiarthroplasty for displaced femoral neck fractures. Clin Orthop Relat Res. 2009 Sep;467(9):2426-2435.*

220 displaced femoral neck fractures were randomised to treatment with either a cemented hemiarthroplasty or an uncemented hydroxyapatite-coated hemiarthroplasty. The same bipolar head was used in both groups. The mean Harris hip score showed equivalence between the groups after 3 and 12 months. In the uncemented group, the mean duration of surgery was 12.4 minutes shorter and the mean intraoperative blood loss was 89 ml less. The Barthel Index and EQ-5D scores did not show any differences between the groups. The rates of complications and mortality were similar between groups. We concluded that both arthroplasties might be used with good results for the treatment of displaced femoral neck fractures.

### **Paper 4**

*Figved W, Dahl J, Frihagen F, Snorrason F, Röhrli SM, Madsen JE, Nordsletten L.*

*Radiostereometric analysis of acetabular wear in hemiarthroplasties of the hip. Submitted.*

A phantom model study was conducted to show that radiostereometric analyses (RSA) is suitable to calculate an accurate three-dimensional computer model of a bipolar prosthetic head, and is able to measure the acetabular wear in patients with hemiarthroplasties. 22 patients with femoral neck fractures were randomised to treatment with either a cemented hemiarthroplasty or an uncemented hydroxyapatite-coated hemiarthroplasty. Eight to ten 1 mm diameter tantalum markers were inserted in the pelvis around the acetabulum for conducting radiostereometric analyses (RSA) of acetabular wear. A mean migration of the

prosthetic head into the acetabulum of 0.62 mm was found at three months, and a further migration of -0.07 mm at 12 months. There were no differences between the two groups in prosthetic head migration or functional outcome. We concluded that RSA may be used for the measurement of cartilage wear in hemiarthroplasties of the hip, and that after three months there was no detectable cartilage degradation during the first postoperative year.





## Background

### *Definition of hip fractures*

The term "hip fractures" is the most frequently used term for describing fractures of the proximal part of the femur. Although the bony parts of the hip also include the acetabulum and the femoral head, the term is used for describing either a fracture of the femoral neck, a fracture in the trochanteric region, or a fracture in the subtrochanteric area of the femur (Figure 1). The term excludes fractures of the acetabulum, the femoral head, and the femoral shaft, all of which have more diverse and different features than hip fractures, in terms of clinical presentation, operative treatment and rehabilitation of patients.

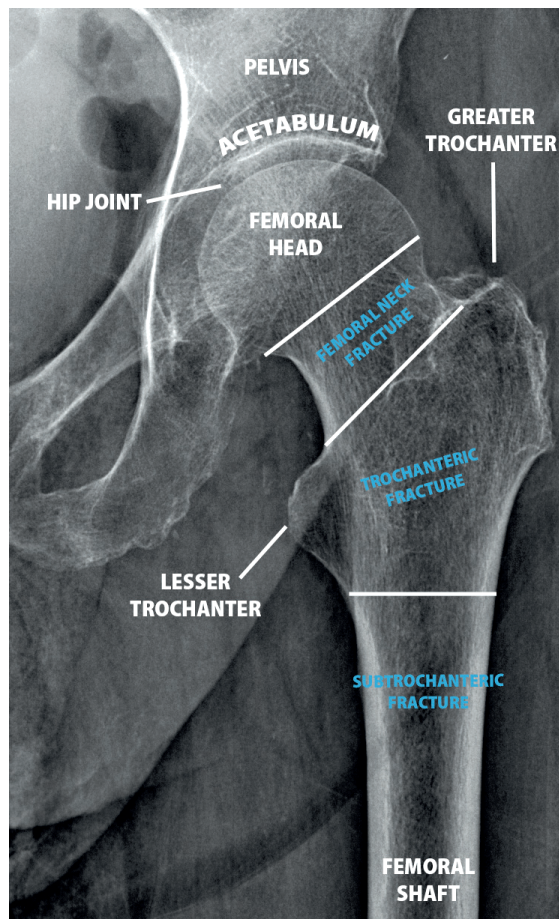


Figure 1. Radiograph of the hip joint and the proximal femur.

## ***Definition of femoral neck fractures***

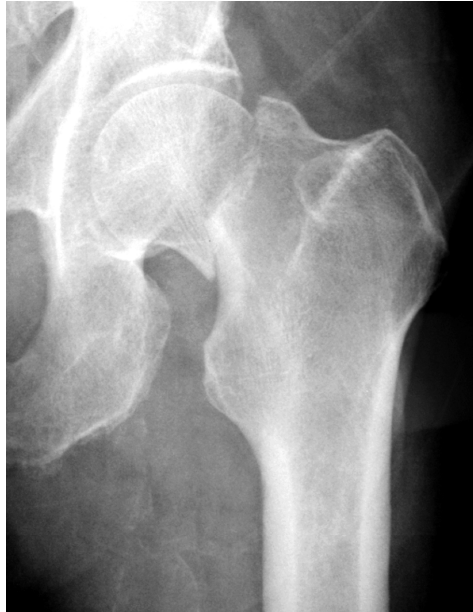The term “femoral neck fracture” is most often used to describe a fracture through the intracapsular part of the femoral neck, excluding fractures through the lateral area of the collum femoris. Fractures described as lateral femoral neck fractures, basocervical fractures or extracapsular femoral neck fractures are less common than intracapsular neck fractures comprising approximately 7-8% of all femoral neck fractures.<sup>1</sup> In the English literature, the terms “femoral neck fracture” without further specification, “intracapsular hip fracture” and “intracapsular proximal femoral fracture” have been used interchangeably.

## ***Epidemiology***

The incidences of hip fractures differ throughout the regions of the world. It has been reported to be highest in The United States, Iceland and the Scandinavian countries, and lowest in Turkey, Korea, Venezuela and Chile.<sup>2;3</sup> There is an exponential increase in incidence with age, the average age differing from 74 to 82 years in the literature and 81 years in Oslo, Norway.<sup>4-6</sup> Norway has the highest incidence of hip fractures in the world, and the capital of Oslo has the highest incidence reported in Norway. 59% of the patients are more than 80 years old, only 4% are below 60 and 75% of the patients are women.<sup>6;7</sup> Although there has been an increase in the incidence rate of hip fractures throughout the world during the last decades, this trend seems to have stopped, and in some countries the hip fracture rates have even decreased.<sup>3;8;9</sup> The number of annual hip fractures worldwide has been reported to be between 1.3 and 1.7 million.<sup>10;11</sup>

## ***Diagnosis***

Most patients with a femoral neck fracture have experienced a low-energy trauma such as falling from erect position to the ground. The usual symptoms of a hip fracture include almost invariably pain in the affected hip, inability to move and bear weight on the leg, usually shortening and external rotation of the affected extremity and pain on passive movement. Standard radiographs in two planes will usually confirm the diagnosis (Figure 2). If the radiographs are inconclusive, other radiological modalities may in some cases reveal the suspected fracture. Magnetic resonance imaging has proved to be a useful procedure in these cases.<sup>12-14</sup>



**Figure 2. Displaced femoral neck fracture as seen on the front projection of a plain radiograph.**

### ***Classification***

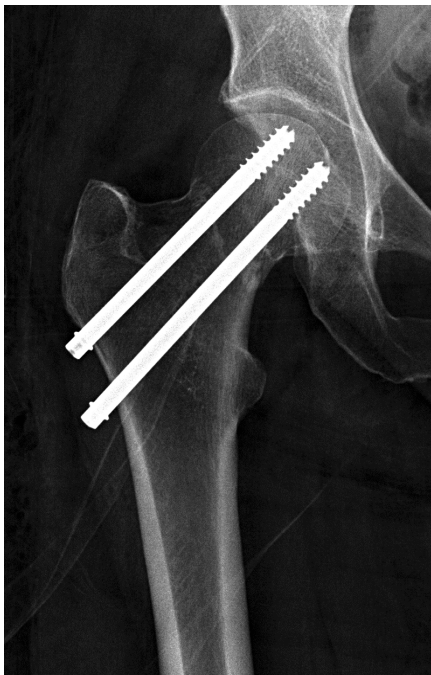
The rationale for classifying fractures in general, is that one subgroup of a specific fracture type may have a different prognosis or outcome than another, and that the best treatment between subgroups may differ. Fracture classification systems are meant to provide clinical guidelines for healthcare professionals, and are essential for conducting research and comparing results of different types of treatment. Several radiological classification systems for femoral neck fractures exist, and the most widely used are Garden's<sup>15</sup> and AO.<sup>16</sup> For the treatment of femoral neck fractures, radiological characteristics providing prognostic signs of healing with internal fixation would be ideal. However, there are problems with interobserver reliability, and there is a lack of documentation that classifications with multiple subgroups will predict different healing potential of fractures.<sup>16-20</sup> The seemingly simple classification of displaced and non-displaced fractures has been the most widely used in recent clinical trials.<sup>21-26</sup> However, a clear definition of an undisplaced fracture is missing. In this thesis, a fracture with an angular displacement in any radiographic plane, not allowing for internal fixation without reducing the fracture, has been defined as a displaced fracture.

## **Treatment**

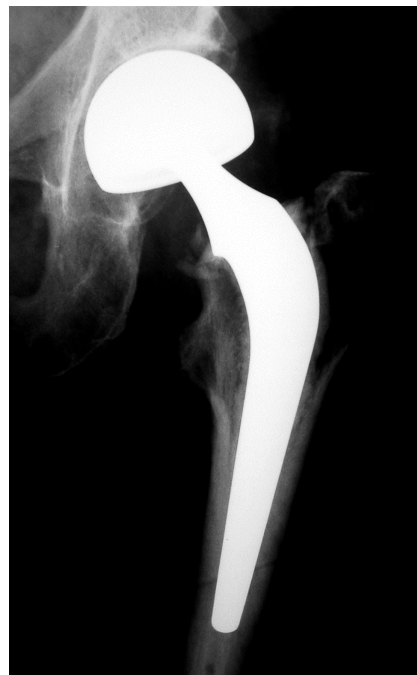
Almost all patients with femoral neck fractures are treated surgically. Rare exceptions may include extremely frail or dying patients, where the risk of surgery outweighs the prognosis without surgery. Nonoperative treatment will inevitably lead to a poor functional result, and is associated with a high risk of further fracture displacement and pain.<sup>27-29</sup>

### **Internal fixation**

Several devices including screws and pins have been used for treating femoral neck fractures and more than 100 different types of internal fixations exist. Fractures are either treated with fixation without any attempt to reduce the fracture, or with closed or open reduction prior to fixation (Figure 2). The results after internal fixation of undisplaced fractures are reasonably good<sup>27,29-33</sup> with union rates of approximately 90% and complication rates of 10-15%. Internal fixation remains the evidence-based treatment of choice for undisplaced fractures in patients of any age. Because of a presumed high mortality rate with arthroplasty, internal fixation has been recommended for very old and frail patients with displaced fractures, but the evidence



**Figure 3.** Radiograph of a femoral neck fracture operated with two parallel screws.



**Figure 4.** Radiograph of a femoral neck fracture operated with a cemented bipolar hemiarthroplasty.

that supports this opinion is very limited.<sup>22;34</sup> Internal fixation also remains the treatment of choice for young patients with both undisplaced and displaced fractures.

## **Hemiarthroplasty**

Treatment with hemiarthroplasty involves removal of the femoral head and most of the femoral neck including the fracture, and inserting a femoral stem with a femoral head the same size as the patient's (Figure 4). The acetabulum is left intact. There is substantial evidence that most patients with a displaced femoral neck fracture should be treated with a hip replacement: Over the last 10 years, there has been an increase in randomised controlled trials comparing internal fixation with arthroplasty for the treatment of femoral neck fractures. Three meta-analyses of RCTs are available, and the most consistent finding is a reoperation rate of 30-40% for internal fixation and below 10% for arthroplasties.<sup>25;26;35</sup> One recent high-quality RCT found a poorer functional outcome for internal fixation even in the subgroup of patients with uneventfully healed fractures.<sup>23</sup> Many different types of hemiarthroplasties exist, and this is explained in more detail in the next section. There is insufficient evidence in the literature to conclude what surgical approach is best for inserting a hemiarthroplasty to the hip, and also insufficient evidence regarding what type of hemiarthroplasty that is preferable in the treatment of femoral neck fractures.<sup>36</sup>

## **Total hip arthroplasty**

Treatment with a total hip arthroplasty involves replacing the acetabulum with a prosthetic cup, in addition to resecting the femoral head and most of the femoral neck, including the fracture, and inserting a femoral stem with a femoral head with the same diameter as the inner diameter of the prosthetic cup (Figure 5). There is limited evidence in the literature that elderly lucid, independent patients may benefit from treatment with a total hip arthroplasty.<sup>35;37</sup> Some of this evidence is based on RCTs with hemiarthroplasties with poor outcome when compared to better hemiarthroplasties. One recent high-quality RCT including only lucid healthy patients 70-90 years old, comparing an Exeter cemented bipolar hemiarthroplasty with an Exeter THA, showed excellent results in both groups and a very small but still significantly higher HHS in the THA group.<sup>38</sup> Two other RCTs, using either several different bipolar hemiarthroplasties with a different stem than the THA group<sup>39</sup> or using a unipolar prosthesis,<sup>40</sup> both conclude that THA may be the best option for some

patients. The dislocation rate after THA for the treatment of femoral neck fractures differ greatly between studies, from 0 to 20%.<sup>38;41</sup> Although the surgery is more extensive than for hemiarthroplasties, no differences in mortality have been found. The most common complications after both hemi- and total hip arthroplasty are dislocations with rates ranging from 0% to 22% between studies, and infections with rates between 0 to 18%.<sup>26</sup>

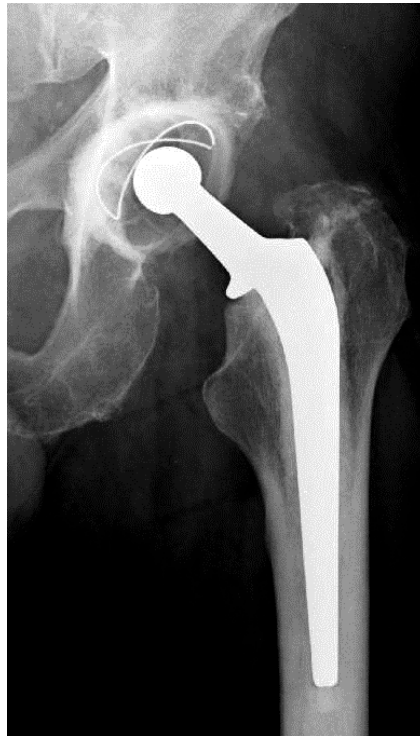

Figure 5. Radiograph of a total hip arthroplasty.

<b>Text box 1 – Treatment options for femoral neck fractures</b>		
<b>Type of treatment</b>	<b>Recommended fracture type or patient group</b>	<b>Specification of implant</b>
Internal fixation	Undisplaced fractures. <sup>27;29;31;32</sup> All fractures in healthy young patients <sup>42-44</sup> (below 60-70).	No evidence of differences between fixation devices.
Hemiarthroplasty	Displaced fractures, also with minimal osteoarthritis. Young patients with significant comorbidities. <sup>7</sup>	Cemented or uncemented well-documented femoral stem with unipolar or bipolar head.
Total hip arthroplasty	Displaced fracture with concurrent symptomatic arthritis. May also be appropriate in healthy, lucid, independent patients. <sup>35;37</sup>	No evidence of difference between total hip arthroplasties for femoral neck fractures.

### ***The history and diversity of hemiarthroplasties***

A multitude of different implants have been used in the treatment of femoral neck fractures, and an exceeding number of prostheses are available today. The option of combining any femoral stem with a vast number of different hemiarthroplasty heads gives an abundance of combinations that are all unique. Most clinical trials compare two prostheses with one or more different features, but comparisons are difficult because there are several features of an implant that may affect the end result. It is well known from the available knowledge on total hip arthroplasty that an ideal prosthesis design for cementing is substantially different from the best design for uncemented fixation,<sup>45</sup> hence, comparing the same implant with or without cement does not reflect the current standards of treatment. Different prosthetic heads with or without an additional articulating joint also have different properties such as a spherical or a slightly aspherical surface, small or big inner head, different locking mechanisms, and differences in surface material and surface treatment.

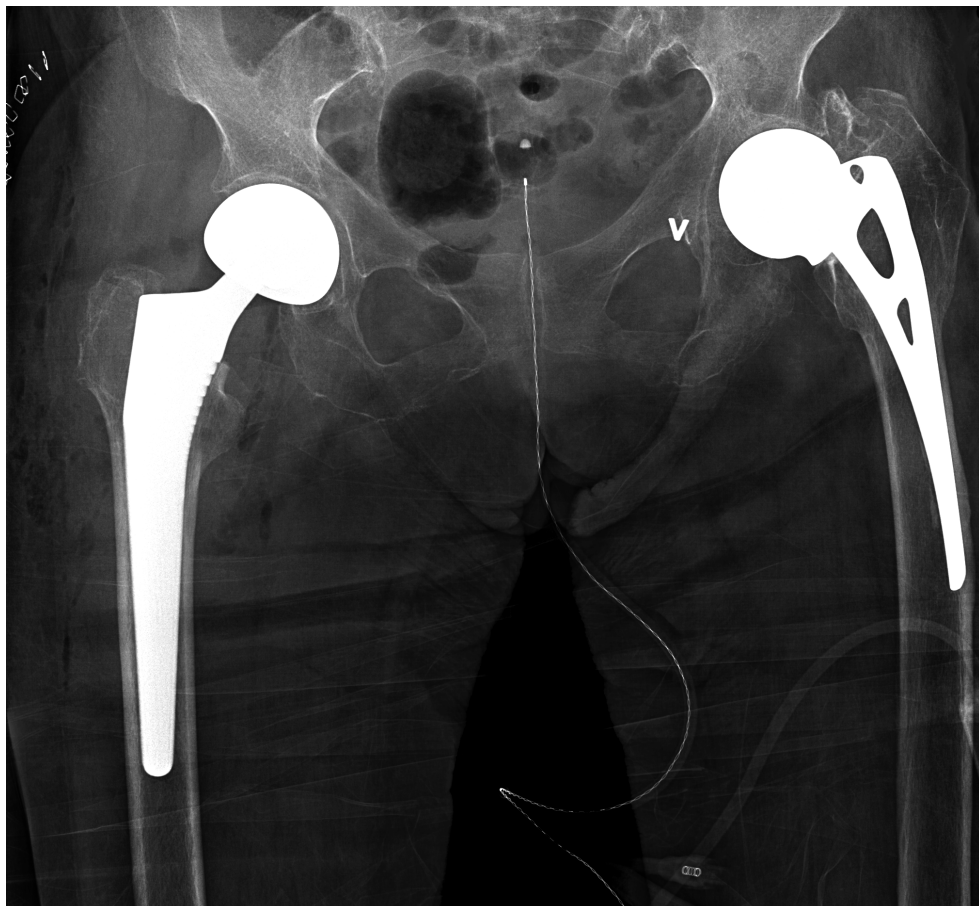


## **The evolution of hemiarthroplasty – unipolar and bipolar prostheses**

Moore and Bohlman first reported the use of a hemiarthroplasty in 1943.<sup>46</sup> The patient was first seen in 1934, presenting with a 15-month old non-union of a femoral neck fracture. After several operations and development of a giant-cell tumour, a wax model was made based on radiographs, and an approximately 12-inch long vitallium prosthesis with a smooth head was made. He was operated in 1940, a periprosthetic fracture followed that eventually healed. Nine months after the surgery he moved well without walking aids, and the original paper states "moving pictures made 15 months after operation reveal an excellent functional result". The patient unfortunately died from cardiac failure almost 2 years after implantation of the prosthesis. During the 1950s the one-piece prostheses Judet,<sup>47</sup> Thompson<sup>48-50</sup> and Austin-Moore<sup>51;52</sup> were gaining popularity in the treatment of various hip conditions including fractures. The Thompson and Austin-Moore prostheses are still used extensively for treatment of femoral neck fractures in some countries today.<sup>53</sup> Early results were promising and marked a substantial step forward compared to internal fixation, but complications remained high in several studies throughout the next decades.<sup>54-57</sup> The main problems were loosening of the femoral stem, acetabular erosion and protrusion of the prosthetic head into the pelvis. In a review by Lestrangle (1990) of seven reports from 1969 through 1982 on the use of the Judet, the Thompson and the Austin-Moore prostheses, the rate of "unsatisfactory (fair or poor)" results ranged from 30 to 48 percent. Later research have also shown a higher revision rate for these one-piece prostheses than for modern cemented bipolar implants.<sup>58</sup> The first step towards a bipolar hemiarthroplasty was introduced by Christiansen in the late 1960s.<sup>59</sup> The Christiansen prosthesis had a built-in trunnion bearing that allowed some movement between the stem and the head of the prosthesis. Again the results were promising,<sup>60;61</sup> but acetabular protrusion remained a problem.<sup>57</sup> The first true bipolar model with a ball and socket joint between the femoral stem and the prosthetic head was the Bateman hemiarthroplasty introduced in 1974.<sup>62</sup> The bipolar design was then used in similar models such as the Giliberty, Monk, and Hastings. Many series with short- and long-term follow-up showed less pain and decreased protrusion of the acetabulum than previous reports on one-piece prostheses,<sup>63-69</sup> but no randomised controlled trials comparing one-piece prostheses with the newer bipolar models were undertaken until much later. Early radiological studies of interprosthetic motion in bipolar hemiarthroplasties showed little or no movement between the stem and the head over time when analysing passive motion of the hip without weight-bearing.<sup>70-74</sup> Later studies analysing the interprosthetic movement during weight-bearing



have, however, showed a preserved movement of the inner joint during the stance phase of gait.<sup>68;75;76</sup> Despite the seemingly obvious differences in favour of bipolar prostheses reported in separate patient series, the advantages of the bipolar design has yet to be proven in randomised trials.<sup>77-80</sup>



**Figure 3.** Radiograph of a patient with an Austin-Moore hemiarthroplasty in her left hip, implanted 10 years prior to a femoral neck fracture of her right hip. In her right hip, she was operated with a Corail bipolar hemiarthroplasty.

### **Cemented or uncemented hemiarthroplasty**

The outcomes after cemented and uncemented hemiarthroplasties differ between trials and reports (Table 1). The studied implants have different characteristics, and the fixation modalities between different types of uncemented arthroplasties also differ: The only known

comparison of two different uncemented hemiarthroplasties was reported in a retrospective study by Livesley in 1993.<sup>81</sup> 48 hydroxyapatite-coated Furlong bipolar hemiarthroplasties were compared with 34 Moore bipolars with a tendency toward better functional results and less pain in the group with HA-coated implants. In 2004, Bezwada reported excellent results in a series of 256 Taperloc uncemented bipolar hemiarthroplasties with a proximal press-fit design.<sup>67</sup> Several recent systematic reviews address the problem with comparing different types of arthroplasties that may have shortcomings with stability of fixation that is not directly related to whether they are cemented or not: Parker conclude in a Cochrane review (2006) that there is limited evidence that cemented prostheses may be associated with less pain.<sup>82</sup> In a more recent systematic review that included 11 studies, Ahn (2008) found no differences in mortality, complications or pain – addressing the need for high-quality clinical trials with consistent reporting of outcomes using implants meeting the standards of our current practice.<sup>83</sup> Discussing the problem with different features of implants even further in a review, Heetveld (2009) stated that the differences found between different types of hemiarthroplasties is minimal, except for the cementless Austin-Moore prosthesis which is out-dated.<sup>37</sup> Rogmark (2006) came to the same conclusion in a meta-analysis of 14 randomised controlled trials.<sup>35</sup> By some researchers, the cementless Austin-Moore prosthesis is still being defended as a treatment option for frail elderly patients.<sup>84</sup>

### **Cement-related complications and death**

Cement-related cardiovascular and respiratory complications and fatalities have been well known since the advent of cementing techniques. A cemented femoral stem may be associated with a small increase in mortality compared with an uncemented stem.<sup>85-88</sup> In a prospective but not randomised trial of 1000 patients with different hip fractures that included 291 cemented and 54 uncemented Monk prostheses, Holt (1994) found an increased mortality rate in the cemented group, the day of discharge being the final follow-up, even when patients who were frail and had a high risk for anaesthesia were specifically allocated to the uncemented group.<sup>89</sup> Most clinical trials and patient series are too small to detect any differences in mortality between treatment with a cemented or an uncemented femoral stem. Conversely, an uncemented prosthesis may be associated with design-specific complications such as thigh pain, and a higher risk of periprosthetic fracture.<sup>45;90</sup>

Author and year	Study design	Cemented implant	Uncemented implant	Conclusions
Wrighton 1971 <sup>91</sup>	Retrospective	Thompson (50)	Austin-Moore (89) Thompson (15)	Better functional outcome in cemented group.
Sadr 1977 <sup>92</sup>	Prospective, nonrandomised	Thompson (20)	Thompson proplast-coated (20)	9 cases of stem loosening in uncemented group.
Suman 1980 <sup>93</sup>	Retrospective	Thompson stem with Moore bipolar head (72)	Austin-Moore (98)	Less pain, better functional outcome in cemented group.
Meyer 1981 <sup>61</sup>	Retrospective	Christiansen (40)	Austin-Moore (43)	Higher HHS in cemented group.
Sonne-Holm 1982 <sup>94</sup>	RCT	Moore unfenestrated (55)	Moore (57)	Less pain in cemented group.
Schwarz Lausten 1982 <sup>95</sup>	Retrospective	Monk (45)	Monk (61)	No difference in pain, better mobility in cemented group.
Dorr 1986 <sup>96</sup>	RCT	UHR (37)	UHR (13)	Less pain, better mobility in cemented group.
Schwarz Lausten 1987 <sup>97</sup>	Retrospective	Monk bipolar (59)	Monk bipolar (124)	No differences.
Gebhard 1992 <sup>98</sup>	Retrospective	Not specified (77)	Not specified (45)	Less use of walking aids but higher revision rate in uncemented group.
Eiskjær 1993 <sup>58</sup>	Retrospective	Christiansen (209) Hastings bipolar (268)	Austin-Moore (202)	Higher long-term prosthesis survival in cemented group.
Lennox 1993 <sup>86</sup>	Retrospective	Hastings bipolar (136)	Monk bipolar (71)	Higher perioperative mortality in cemented group.
Holt 1994 <sup>89</sup>	Prospective, nonrandomised	Monk (291)	Monk (54)	Higher mortality in cemented group.
Emery 1991 <sup>99</sup>	RCT	Thompson bipolar (27)	Moore bipolar (26)	Less pain in cemented group.
Lo 1994 <sup>100</sup>	Retrospective	Bateman (190)	Bateman (261)	Less pain in cemented group.
Harper 1994 <sup>82</sup>	RCT	Thompson (29)	Thompson (31)	Less pain in cemented group.
Faraj 1999 <sup>101</sup>	Retrospective	Thompson (23)	Thompson (78)	No differences.
Branfoot 2000 <sup>102</sup>	RCT	Thompson (38)	Thompson (53)	No differences.
Khan 2002 <sup>103</sup>	Retrospective	Austin-Moore (123)	Austin-Moore (121)	Less pain, better walking ability and ADL in cemented group.
Foster 2005 <sup>104</sup>	Retrospective	Thompson (174)	Austin-Moore (70)	Increased risk of periprosthetic fracture in uncemented group.
Santini * 2005 <sup>105</sup>	RCT	Wright-Cremascoli bipolar (53)	Intracanal bipolar Zweymuller bipolar CLS bipolar (53)	No differences.
Singh 2006 <sup>106</sup>	Retrospective	Thompson (25)	Austin-Moore (29)	Less pain, fewer reoperations in cemented group.
Parker 2010 <sup>107</sup>	RCT	Thompson (189)	Austin-Moore (189)	Less pain, better mobility in cemented group.

**Table 1: Available reports on cemented versus uncemented hemiarthroplasties for femoral neck fractures. Grey rows indicate randomised controlled trials. \* indicates that the brand of arthroplasties was not disclosed in the publication, the first author provided this information by e-mail.**



## **Aim of the studies**

The overall objective of this thesis was to explain different aspects and features of hemiarthroplasties for the treatment of femoral neck fractures. The specific aims of the present studies were, in the form of research questions:

- 1      What are the outcomes after interprosthetic dislocations of the Charnley/Hastings hemiarthroplasty? Do patients with this complication have any common features?
  
- 2      What are the results of conversion from failed hemiarthroplasties to total hip arthroplasties?
  
- 3      Is there a difference in complications, functional outcome and quality of life between cemented and uncemented hemiarthroplasties using well-documented femoral stems? Does the use of a well-documented and modern bipolar HA-coated hemiarthroplasty benefit patients in terms of postoperative pain and earlier mobilisation, compared to clinical trials of previous-generation cementless implants?
  
- 4      Is it possible to measure the acetabular wear in a bipolar hemiarthroplasty using radiostereometric analysis (RSA)? What is the extent of early cartilage wear of the acetabulum after hemiarthroplasty? Is there a difference in acetabular wear between a cemented and an uncemented hemiarthroplasty?



## Patients

### Paper 1 – A retrospective study

The 350 consecutive patients in **paper 1** were treated for an acute, displaced femoral neck fracture with a Charnley/Hastings bipolar hemiarthroplasty between January 1998 and April 2003 at Asker and Bærum hospital. A retrospective study was conducted using the patients' complete charts and radiographs. No patients were excluded from the series, and there was no control group. 86% of the patients were followed up at 8 weeks with a radiological and clinical examination. All but one patient lived in the hospital catchment area.

### Paper 2 – A register study

The 595 procedures included in **paper 2** were a Norwegian Arthroplasty Register analysis of conversion from failed hemiarthroplasty to total hip arthroplasty. The Norwegian Arthroplasty register (NAR) was established by the Norwegian Orthopaedic Association in September 1987.<sup>108;109</sup> The register collects information on primary and revision total hip arthroplasties from all hospitals in Norway, based on a form completed by the surgeon after surgery (Appendix 1). The register has been validated and has an excellent reporting rate, both for primary and revision surgery<sup>110;111</sup> and contains prospective data on more than 110,000 primary hip arthroplasties and 18,000 revisions.<sup>1</sup> The study was based on data from September 1987 to December 2004, selecting patients 60 years or older, leaving 595 conversion procedures for further analyses. 74,865 primary total hip arthroplasties, 4,145 revisions, and subgroups of these procedures were used as control groups in various analyses. Subsequent procedures conducted on the same hip were defined as end-points, using the personal identification number for Norwegian citizens.

### Paper 3 – A randomised controlled trial

The 230 hip fractures included in this randomised controlled trial were recruited from Asker and Bærum hospital (150 fractures) and Ullevål university hospital (80 fractures) between September 2004 and August 2006. The patients were randomised to treatment with either a Spectron cemented or a Corail uncemented hemiarthroplasty. All patients received the same

bipolar head. All patients 70 years or older who were admitted with a displaced femoral neck fracture were eligible for inclusion. Patients who had fractures caused by malignant disease, had ongoing infectious disease, had previous symptomatic hip disease such as osteoarthritis, or who were unable to walk before the fracture, were excluded. Of the 390 patients who were admitted with 402 intracapsular femoral neck fractures, 239 patients (247 fractures) were eligible for inclusion and 223 patients (230 fractures) were recruited. There were three protocol violations in the cemented group and seven in the uncemented group, leaving 112 and 108 hips in the respective groups for the per-protocol analyses. The patients were followed at three and 12 months postoperatively. No patients were completely lost to follow-up.

#### **Paper 4 – A phantom model study followed by a randomised controlled trial**

The 22 patients included in this study were recruited from Ullevål university hospital from March 2006 to January 2008 and were randomised according to the protocol for the clinical trial presented in **paper 3**. The same criteria for inclusion and exclusion were applied, but the age-limit was lowered to 65 years or older and the patients had to be able to walk without aids to be eligible for inclusion. The study started as a subgroup of the large clinical trial with 230 hip fractures, but only three patients were included before the original trial stopped including patients. Therefore, the remaining 19 patients were included only in this smaller trial. The patients received the same treatment as in **paper 3**, with addition of the insertion of eight to ten 1 mm diameter tantalum markers spread around the acetabulum for conducting radiostereometric analyses (RSA) of acetabular wear. Patients were followed at 3 and 12 months postoperatively.



## Methods

### *Treatment*

The patients in **paper 1** were all operated with a Charnley/Hastings bipolar cemented hemiarthroplasty (DePuy International Ltd, Leeds, UK). The patients in **papers 3 and 4** were randomised to treatment with either a Spectron cemented femoral stem (Smith & Nephew, Inc, Memphis, TN, USA) or a Corail uncemented femoral stem (DePuy International Ltd, Leeds, UK), a 28 mm cobalt-chromium head and the same Mobile Cup bipolar head (DePuy International Ltd, Leeds, UK). For all patients in **papers 1, 3 and 4**, surgery was standardised using a posterolateral approach with a T-shaped incision of the joint capsule, repair of the capsular incision over the prosthetic head and repair of the piriformis and small lateral rotator tendons. All patients were given 2 g preoperative intravenous cefalotin and an additional three doses the first 24 hours after the operation. All patients received a daily dose of 5000 IU low-molecular-weight heparin subcutaneously for at least 7 days. Early mobilisation was encouraged in all patients with full weight-bearing when tolerated. The surgeons on call performed all procedures according to the departmental routines: In **paper 1** there were 31 different resident surgeons and 6 consultants. In **paper 3** there were 36 surgeons involved and in **paper 4** only five surgeons who were trained for inserting tantalum markers performed the surgeries. The patients in **paper 2** were reported to the Norwegian Arthroplasty Register because they were treated with conversion from a failed hemiarthroplasty to a total hip arthroplasty.

### *Outcome measures*

In **paper 1** the objective was to describe the outcome after interprosthetic dislocations of the Charnley/Hastings hemiarthroplasty. The primary outcome was the result after treatment for an interprosthetic dislocation of a hemiarthroplasty. The secondary outcomes were subsequent complications, reoperations and death. In **paper 2** the results after conversion from failed hemiarthroplasty to a total hip arthroplasty were assessed using subsequent procedures after conversion as end-points. The main outcome was the risk of a subsequent revision after conversion. The secondary outcomes were the number of reoperations, the number of perioperative complications, survival of separate prosthetic components, and death. In **paper**

3 the clinical result after cemented or uncemented hemiarthroplasty was assessed using Harris hip score<sup>112</sup> (Appendix 2) as the main outcome measure. Secondary outcomes were EQ-5D<sup>113</sup> (Appendix 4), Barthel Index<sup>114</sup> (Appendix 3), surgical complications and reoperations. In **paper 4** the main outcome was the acetabular wear of hemiarthroplasties measured using radiostereometric analysis – with penetration of the bipolar head into the acetabulum as a function of time. Secondary outcomes were Harris hip score,<sup>114</sup> EQ-5D<sup>113</sup> and Barthel Index.<sup>114</sup>

### **Harris Hip Score**

The Harris hip score (Appendix 2) was originally developed for evaluating arthroplasty treatment of traumatic arthritis of the hip after dislocation and acetabular fractures.<sup>112</sup> It is widely used by surgeons as a measurement of disability and pain in osteoarthritis in general.<sup>115</sup> It has been used in several recent clinical trials comparing different treatment methods for femoral neck fractures,<sup>23;38;41</sup> and has been found to have a good discriminatory ability and responsiveness in patient populations with femoral neck fractures.<sup>116</sup> The Harris Hip Score has a maximum of 100 points indicating no presence of hip pain or symptoms. There are several subsets of scoring comprising pain (0-44 points), gait (0-33 points), activities (0-14 points), range of motion and absence of deformity (0-9 points).

### **Barthel Index**

The Barthel Index (Appendix 3) is a scale used to measure a patient's ability to perform activities of daily living (ADL) – the score is also referred to as the Barthel ADL Index. It consists of ten items describing ADL and mobility with a possible total score of 0-20. A higher number is associated with a greater likelihood of living without attendant care: A patient with a BI of 20 is “continent, feeds himself, dresses himself, gets up out of bed and chairs, bathes himself, walks at least a block, and can ascend and descend stairs”.<sup>114</sup> The BI has been found to be appropriate for use on patients with femoral neck fractures.<sup>116</sup>

### **EQ-5D**

EQ-5D<sup>113</sup> (Appendix 4) is a standardised instrument for use as a measure of health-related quality of life. It is applicable to a wide range of health conditions and treatments. EQ-5D was

originally designed to complement other instruments but is now increasingly used as a 'stand alone' measure. It is designed to be completed by the respondents, and instructions are included in the questionnaire. The form consists of two parts: The EQ-5D descriptive system and a visual analogue scale (EQ-VAS). The first part consists of five questions regarding mobility, self-care, usual activities, pain/discomfort, and anxiety/depression, each with three possible responses (no problem, some problems, major problems). Based on the answers given, the EQ-5D index score is calculated from a large European reference population.<sup>117</sup> An EQ-5D index score of less than zero indicates the worst possible health state, and a score of 1 indicates the best possible health state. The second part is the EQ-VAS comprised solely of a 20-cm visual scale ranging from zero (worst) to 100 (best). The respondent is asked to draw a line indicating his or her opinion of their health status today. The EQ-5D has also been found to be appropriate for use on patients with femoral neck fractures.<sup>116</sup>

### ***Radiostereometric analysis (RSA)***

Radiostereometric analysis (RSA) is a widely used and well documented method for measuring very small three-dimensional movements between prosthesis components, or between a prosthesis and the patient's skeleton. Minimal movements of prosthetic components in an early postoperative phase, have proven to be indicative of good long-term results for arthroplasties.<sup>118;119</sup> The method consists of placing small 1 mm radiopaque spherical tantalum (Ta) markers (balls) into the patient's skeleton. Two simultaneous radiographs are used for computer-assisted calculations of movements between prosthesis components and the markers, in three dimensions. Two review articles describe this method in detail.<sup>120;121</sup> The method is explained in more detail in **paper 4**.

### **Phantom model study**

We found no studies in the literature making use of RSA for measuring the penetration of a prosthetic head into an untouched acetabulum. Therefore, we conducted a phantom model study using a plastic pelvis with inserted tantalum markers and a bipolar hemiarthroplasty (Figure 6 and 7). Eight sets of double-exposure radiographs were taken, and the position of the bipolar head was altered between each set. Analyses of the point motion between the sets showed that the rotation of the head about its axis of symmetry had no influence on the distance between the head and the acetabulum in any of the three dimensions X, Y and Z. We

concluded that this method calculates an accurate three-dimensional model of the bipolar head, and should be able to measure the acetabular wear in patients with hemiarthroplasties. While conducting the final RSA analysis for **paper 4**, one research paper was published on the same method for measuring the prosthetic femoral head impact on acetabular articular cartilage in a hemiarthroplasty model in sheep.<sup>122</sup>

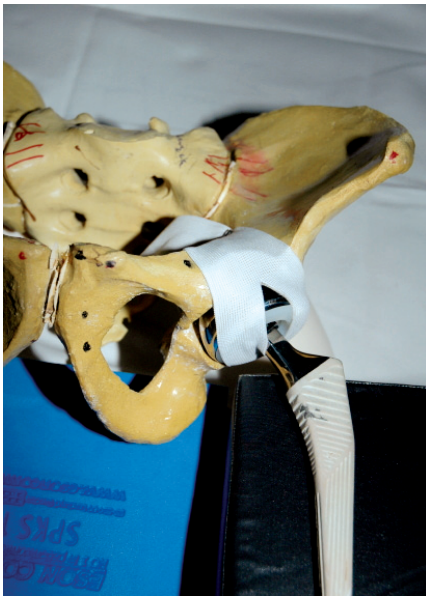

Figure 6: Plastic pelvis with Tantalum markers and a bipolar hemiarthroplasty

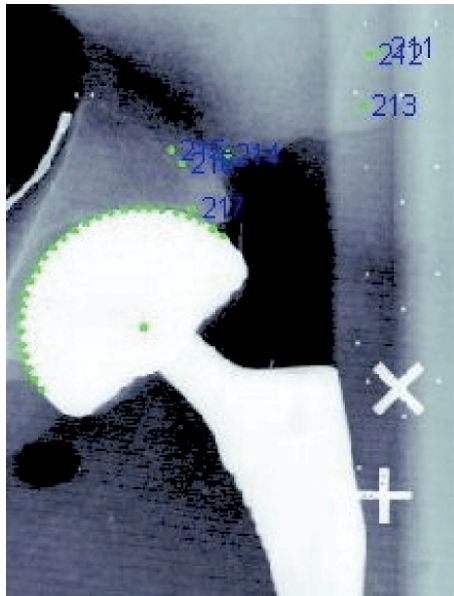


Figure 7: RSA-image with markers in the pelvis and computer-calculated centre of the bipolar head.

### ***Statistical methods***

In **paper 2**, we used Kaplan-Meier analysis to calculate survival probabilities with 95% confidence limits at 5 and 10 years. The reverse Kaplan-Meier method was used to calculate the median follow-up.<sup>123</sup> Adjusted survival curves were calculated using Cox regression. Multiple Cox regression analyses were performed to calculate relative risks (hazard ratios) for the different covariates (age, sex, cemented vs. uncemented implants, and indication for the index operation). For all analyses in **paper 2**, we used the statistical packages S-Plus (S-Plus 2000 for Windows; MathSoft Inc, Seattle, WA, USA) and SPSS version 13 for Windows (SPSS Inc, Chicago, IL, USA). In **paper 3 and 4**, t-tests were used for analyses of Harris hip score, EQ-5D index score, and analyses of continuous variables. For the primary outcome,

Harris hip score, we used the equivalence criterion,<sup>124</sup> defining equivalence between the two groups if the 95% confidence interval of the difference in Harris hip score was completely within the interval of -10 to 10 points. Two-tailed Fisher's exact test was used for analyses of dichotomous variables. **In paper 3 and 4**, all analyses were conducted on per-protocol basis to minimize the risk of falsely concluding equivalence. Power calculations were conducted using SPSS SamplePower 2.0 for Windows (SPSS Inc, Chicago, IL, USA) and were verified using Altman's nomogram.<sup>125</sup> For **paper 3 and 4**, versions 16 and 17 of SPSS Statistics for Macintosh were used for all statistical analyses (SPSS Inc, Chicago, IL, USA). Randomisation was performed using a computer random number generator with permuted blocks of five (<http://www.randomization.com>).



## Main results

**Paper 1** demonstrated that the results after interprosthetic dislocations of the Charnley/Hastings hemiarthroplasty are poor: These 11 patients were generally old and frail; only two patients had an uneventful recovery following a successful reduction of the dislocation. One recovered successfully after a myocardial infarction, two died before the planned follow-up, three died during hospitalisation, two had a girdlestone procedure, and one refused treatment.

In **paper 2** we found that the median annual incidence of conversion arthroplasty reported to the Norwegian Arthroplasty Register was 35. The most important finding was the significantly lower risk of failure (revision surgery for any reason) for the conversion procedures with stem exchange than for the conversion procedures that retained the femoral stem (RR = 0.4; 95% CI: 0.25 to 0.81). The predominant cause of subsequent surgery after conversion to a total hip arthroplasty was stem loosening in the group with stem exchange and dislocation in the group with retention of the stem. For the 122 conversion procedures in which the femoral stem was retained, we found an increased risk of failure for both the complete prosthesis (RR = 4.6; 95% CI: 2.8 to 7.6) and for the acetabular cup (RR = 4.8; 95% CI: 2.3 to 10) compared to primary hip arthroplasties. There was no difference in cup survival when comparing the group of 122 procedures involving retention of the femoral stem with all first cup revisions in the register involving retention of the stem (RR = 0.8; 95% CI: 0.3 to 1.9). For the 473 conversion arthroplasties with exchange of the stem, we found no difference in risk of failure compared to all revision stems in the register, neither for the complete prosthesis (RR = 0.8; 95% CI: 0.50 to 1.20) nor for the stem (RR = 0.9; 95% CI: 0.53 to 1.59).

In **paper 3** we found equivalent Harris hip scores between the two groups with a mean difference of 1.18 at three months (95% CI: -4.3 to 6.7) and 0.89 at 12 months (95% CI: -4.2 to 6.0). No other outcome measures showed any difference between the groups except for a shorter duration of surgery of 12.4 minutes in the uncemented group ( $p < 0.001$ ; 95% CI: 7.2 to 17.6) and a difference in intraoperative blood loss between 300 ml in the uncemented group and 390 ml in the cemented group ( $p < 0.001$ ; 95% CI: 42 to 137). The rates of complications and mortality were similar.

In **paper 4** we showed that radiostereometric analysis may be used for measuring the acetabular wear in hemiarthroplasties of the hip, described as the point migration of the centre of the prosthetic head relative to a rigid body of tantalum markers implanted around the acetabulum. In the phantom model study, we showed that the motion of the center of the prosthetic head relative to the pelvis was not influenced by the orientation of the prosthetic head. In the clinical trial, we found no difference between the cemented and the uncemented group. After an initial period of weight-bearing and seating of the bipolar head in the acetabulum, there was no wear from three to 12 months: A mean migration of the prosthetic head into the acetabulum of 0.62 mm was found at three months (95% CI: 0.27 to 0.97) and a further migration of -0.07 mm at 12 months (95% CI: -0.16 to 0.32).



## Discussion

### *Methods*

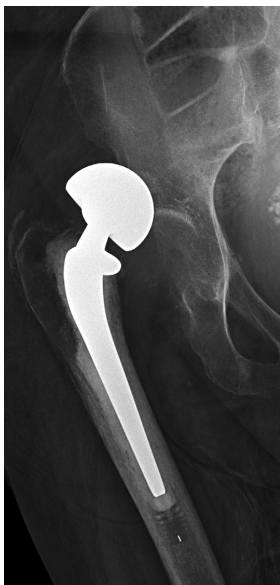This thesis is based on four papers ranging from a retrospective descriptive study in **paper 1**, a register study in **paper 2** and randomised controlled trials in **papers 3 and 4**. The level of evidence will therefore vary between the papers according to the Oxford Centre for Evidence-based Medicine (<http://www.cebm.net>). The evidence in **paper 1** would be of level 4, being a retrospective study describing the results of a specific treatment and subsequent complications, with no control group. Increasing the level of evidence in study on this topic is difficult: Further research exploring the results after treatment of a dislocated hemiarthroplasty would need a larger number of patients experiencing this complication, possibly a large register study. A randomised controlled trial (RCT) of different treatment modalities would be extremely difficult, both ethically and methodologically. This also applies to **paper 2**, which is a retrospective study based on prospectively collected data. Like other studies from the Norwegian Arthroplasty Register (NAR), this is a prognostic cohort study, and the evidence is probably of level 2. The evidence in this paper should be interpreted with caution, as there are several confounding factors not accounted for by the adjustments using Cox regression analyses: Most important, the selection of patients in need of surgery to either conversion to a THA, to a different surgical procedure that does not involve conversion, or to no surgery. The latter two would not cause the surgeon to file a report to the NAR. **Paper 3** was given the rating of a level 1 therapeutic study by the journal, defined as a high quality randomised trial with statistically significant difference or no statistically significant difference but narrow confidence intervals. Although the evidence in this paper is of level 1, it is important to keep in mind that an RCT of this size lacks the statistical power to show any potential differences in less common complications between the groups, such as cement-related complications and death, periprosthetic fractures, and infections.

Both **paper 3 and 4** contains a well-defined primary outcome, a power analysis including details of how the sample size was determined, and adequate reporting of the results. The RCTs in **paper 3 and 4** were conducted in accordance with the CONSORT (Consolidated Standards of Reporting Trials) Statement.<sup>126</sup> The evidence in **paper 4** is, however, of lesser

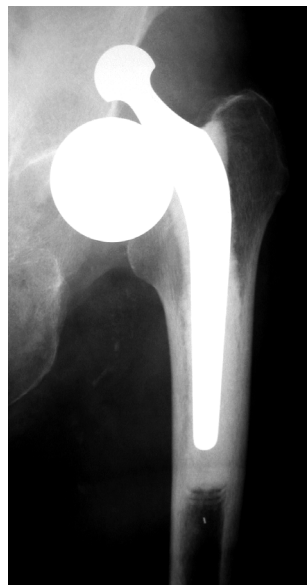quality, because there were no difference in the primary outcome between the two groups. Although the sample size calculation was performed with a properly defined effect size, the results in this trial indicate that a larger number of patients or a longer follow-up would be needed to show a difference between the groups. Therefore, the evidence in **paper 4** is probably of level 2. Nevertheless, the strength of this paper lies in our primary aim of showing that RSA may be used for measuring acetabular wear in hemiarthroplasties, and the narrow confidence interval of the acetabular wear between three and 12 months.

### ***General discussion***

In **paper 1** we found an overall dislocation rate of 4% and 11 of 14 dislocations were interprosthetic. In the literature, the rate of dislocation ranges from 0 to 22%.<sup>26</sup> It is uncertain whether the outcome after an interprosthetic dislocation is worse than after a dislocation of an intact prosthesis: A separation of prosthetic components will almost definitely need surgical treatment, whereas a dislocated but intact prosthesis may have a higher probability of successful closed reduction (Figure 8 and 9). Nonetheless, the outcome of dislocation of a hemiarthroplasty is in general very poor. In a retrospective review of 1000 consecutive hemiarthroplasties, Blewitt (1992) reported a mortality as high as 65% for patients with a



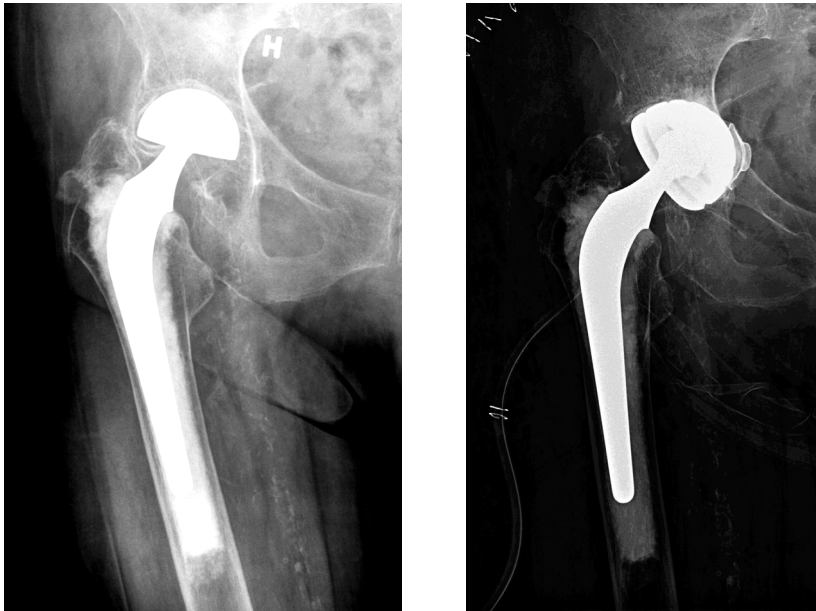**Figure 8: Dislocation of an intact bipolar hemiarthroplasty**



**Figure 9: Interprosthetic dislocation of a bipolar hemiarthroplasty**

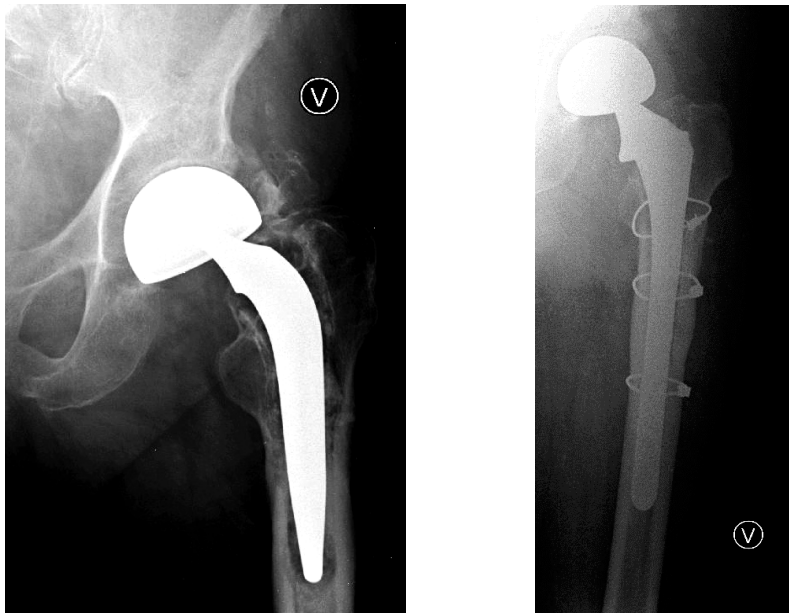
dislocation, and a rate of re-dislocation of 75%.<sup>127</sup> Sierra (2006) reported that closed reduction resulted in no further surgery in only 30% of dislocations in a series of 1812 patients treated with a bipolar hemiarthroplasty.<sup>128</sup> Mental disease or cognitive impairment is a known risk factor for dislocation, both for THA and hemiarthroplasties.<sup>41;129;130</sup> Although there is insufficient evidence in the literature with regard to what surgical approach is best for inserting a hemiarthroplasty to the hip, there is a trend towards a higher dislocation rate when using the posterior approach and a lower rate when using an anterior approach.<sup>26;131;132</sup> Large and probably multi-centre RCTs comparing different surgical approaches, preferably using the same prosthesis, are needed to show a potential advantage of an anterior approach. The optimal treatment for a dislocated hemiarthroplasty will necessarily depend on the type of prosthesis and the status of the patient.

**Paper 2** should be followed by a similar study using patients from the Norwegian Hip Fracture Register (NHFR),<sup>133;134</sup> rather than the Norwegian Arthroplasty Register. The NHFR was started as a separate register in 2004 and contains a nation-wide registration of all hip fractures, including type of fracture and specific treatment method. While the NAR only



**Figure 10.** A patient with a cemented bipolar hemiarthroplasty implanted 5 years ago, presenting with groin pain and stiffness of the hip (left). She was treated with conversion to a total hip arthroplasty, inserting a cemented dual-mobility acetabular component, leaving the femoral stem in place (right).

records procedures where a prosthetic component is implanted, replaced or removed – the NHFR records all subsequent procedures regardless of implants. The 595 patients in our study were selected based on a reported reoperation for a failed hemiarthroplasty that was originally implanted for the treatment of a femoral neck fracture (Figure 10) – there was no information regarding type or brand of the original hemiarthroplasty, and the reported indications for conversion were inconsistent. A similar study from the NHFR would be able to present important information such as the specific indication for conversion and the type of hemiarthroplasty in need of conversion. Most important, it would be able to present all secondary procedures conducted on failed hemiarthroplasties that do not necessarily involve conversion to a THA (Figure 11). Several patient series of conversion of failed hemiarthroplasty to THA have demonstrated high rates of perioperative and postoperative complications.<sup>135-139</sup> While most studies have reported a high rate of postoperative dislocations, one as high as 50%<sup>140</sup>, other studies have reported low dislocation rates.<sup>141;142</sup> This type of surgery is technically challenging, and both surgical techniques, approaches and different prosthetic designs need further investigation. The role of acetabular components specifically designed for preventing dislocation should also be assessed.<sup>143</sup>



**Figure 11.** A patient with a bipolar cemented hemiarthroplasty implanted 20 years ago, presenting with thigh pain caused by a loose femoral stem (left). He was treated with revision surgery of the stem and replacement of the bipolar head (right). Since this procedure is not a conversion to a THA, the procedure was not reported to the NAR. Today, however, this procedure would have been reported to the NHFR.

In **paper 3** we found equivalent Harris hip score between a cemented and an uncemented hemiarthroplasty. Meta-analyses and systematic reviews have failed to provide evidence of less pain after cemented hemiarthroplasty,<sup>82;83</sup> but a trend towards less pain when using cemented implants has been reported.<sup>82</sup> This finding is strongly influenced by the inclusion of studies using the uncemented Austin-Moore hemiarthroplasty which has been shown to have inferior functional results and a poor prosthesis survival.<sup>35;37;58</sup> The results in our study only shows that treatment with one specific uncemented hemiarthroplasty gave the same functional results as the cemented hemiarthroplasty that was used. This finding might be generalised to some extent, as it is highly probable that similar HA-coated proximal press-fit uncemented hemiarthroplasties would give the same results. This should, however, be assessed in further RCTs. The many studies comparing cemented and uncemented hemiarthroplasties (Table 1), the one study comparing two uncemented hemiarthroplasties,<sup>81</sup> and the findings in our study, illustrate that the seemingly diverging results may indeed show a pattern: Well-fixed uncemented femoral stems may lead to the same good results as cemented stems. The studies showing poor outcomes after uncemented hemiarthroplasty have all used femoral stems that are not used for THA. Unsatisfactory fixation in the femoral canal may lead to pain and loosening of the prosthesis. The abundance of clinical trials, case series with long-term follow-up, and arthroplasty registers studying implants used for total hip arthroplasty, provide strong evidence of superior long-term results with uncemented femoral stems.<sup>45;144</sup> To examine the possible differences in complications between hemiarthroplasties of different design and fixation method, very large RCTs or register studies would be needed. Both functional results and the panorama of possible complications may be related to features of a specific implant that is unrelated to the use of cement in the femoral canal.<sup>145</sup>

**Paper 4** should be regarded as a pilot study, demonstrating a new application of RSA for measuring the acetabular wear in hemiarthroplasties. It was designed as an RCT comparing the acetabular wear of cemented and uncemented hemiarthroplasties, but we did not find any differences between the groups. It has been suggested that HA-coated femoral stems may increase osteolysis and acetabular wear,<sup>146</sup> but we did not expect to find any differences after a follow-up of only 12 months. Of the 22 patients included, there were eight who were unable to participate in the 12-month follow-up because of death (3), dislocation (2), and withdrawal from the trial (3). We are currently conducting a 3-year follow-up of the remaining patients. We found no acetabular wear from three to 12 months. An RCT comparing the acetabular

wear of a bipolar and a unipolar hemiarthroplasty in 30 patients is now including patients at Asker and Bærum hospital, using the same RSA method.

## Conclusions

1. After inserting a cemented bipolar hemiarthroplasty or an uncemented HA-coated press-fit bipolar hemiarthroplasty for a femoral neck fracture, the functional outcome measured with Harris hip score is equivalent between the two groups at three and at 12 months. Furthermore,
  - a) There is no difference in mortality up to 24 months.
  - b) Reoperation rates and complications are similar.
  - c) Duration of surgery is shorter with the uncemented implant.
  - d) Perioperative blood loss is lower with the uncemented implant.
  
2. Radiostereometric analysis (RSA) is suitable for measuring the acetabular wear in hemiarthroplasties, and:
  - a) After an initial period of three months, the acetabular wear is very low in bipolar hemiarthroplasties.
  - b) There is no difference in acetabular wear between cemented and uncemented bipolar hemiarthroplasties up to 12 months.
  
- 3) Conversion from a failed hemiarthroplasty to a total hip arthroplasty is an uncertain procedure, due to high rates of subsequent complications. Implanting an acetabular cup to convert a hemiarthroplasty to a THA carries a high risk of early failure, mainly because of dislocations.
  
- 4) The outcome after interprosthetic dislocation of a bipolar hemiarthroplasty is poor.





## Suggestions for further research

Further research should be conducted on an implant-specific basis as opposed to concept-based. From the literature on total hip arthroplasty, it is clear that minor changes to a specific implant may alter the results dramatically. The following questions remain unanswered, and a vast number of RCTs will be needed to answer them to the fullest extent possible. By using femoral stems commonly used for THA in all patients, cemented or uncemented, the results of RCTs would be easier to compare and extraction of data for meta-analyses would be simplified. There is a need for more randomised controlled trials that 1) compare *specific* hemiarthroplasties, cemented and uncemented. Larger studies may reveal differences in less common complications such as periprosthetic fractures, cement-related mortality and infection rate. 2) compare total hip arthroplasty with both bipolar and unipolar hemiarthroplasty, using the exact same femoral stem, with a follow-up of more than one year, and 3) compare different types of unipolar and bipolar hemiarthroplasties with special emphasis on the long-term outcome and acetabular wear.

- 1) Are the findings in this thesis reproducible? Will other comparisons of press-fit uncemented femoral stems and cemented stems used for hemiarthroplasty show equivalent results?
- 2) Is there a difference between bipolar and unipolar hemiarthroplasties with regard to long-term outcome and acetabular wear, when the exact same femoral stem is used in both groups?
- 3) Is the optimal shape of a bipolar or a unipolar head spherical or slightly aspherical?
- 4) What is the optimal diameter of the prosthetic head of a hemiarthroplasty – slightly larger, slightly smaller or the same diameter as the resected femoral head?
- 4) Will a large-diameter femoral head or a dual-mobility cup give the best result after conversion from hemiarthroplasty to total hip arthroplasty?
- 5) What subgroup of patients will benefit from total hip arthroplasty rather than hemiarthroplasty, when the exact same femoral stem is used?
- 6) What is the optimal type of total hip arthroplasty for the treatment of femoral neck fractures, regarding femoral head size, method of stem and cup fixation, and cup design?



## Reference list

1. Furnes O, Havelin LI, Espehaug B, Steindal K, Sørås TE. The Norwegian Arthroplasty Register. Report 2008. ISBN: 978-82-91847-13-9. ISSN: 0809-0405. 2008.
2. Kanis JA, Johnell O, De Laet C, Jonsson B, Oden A, Ogelsby AK. International variations in hip fracture probabilities: implications for risk assessment. *J Bone Miner Res.* 2002 Jul;17(7):1237-1244.
3. Brauer CA, Coca-Perrailon M, Cutler DM, Rosen AB. Incidence and mortality of hip fractures in the United States. *JAMA.* 2009 Oct 14;302(14):1573-1579.
4. Thorngren KG, Hommel A, Norrman PO, Thorngren J, Wingstrand H. Epidemiology of femoral neck fractures. *Injury.* 2002 Dec;33 Suppl 3:C1-7.
5. Chevalley T, Guilley E, Herrmann FR, Hoffmeyer P, Rapin CH, Rizzoli R. Incidence of hip fracture over a 10-year period (1991-2000): reversal of a secular trend. *Bone.* 2007 May;40(5):1284-1289.
6. Lofthus CM, Osnes EK, Falch JA, Kaastad TS, Kristiansen IS, Nordsletten L, et al. Epidemiology of hip fractures in Oslo, Norway. *Bone.* 2001 Nov;29(5):413-418.
7. Lofthus CM, Osnes EK, Meyer HE, Kristiansen IS, Nordsletten L, Falch JA. Young patients with hip fracture: a population-based study of bone mass and risk factors for osteoporosis. *Osteoporos Int.* 2006;17(11):1666-1672.
8. Johnell O, Borgstrom F, Jonsson B, Kanis J. Latitude, socioeconomic prosperity, mobile phones and hip fracture risk. *Osteoporos Int.* 2007 Mar;18(3):333-337.
9. Johnell O, Kanis JA. An estimate of the worldwide prevalence and disability associated with osteoporotic fractures. *Osteoporos Int.* 2006 Dec;17(12):1726-1733.
10. Gullberg B, Johnell O, Kanis JA. World-wide projections for hip fracture. *Osteoporos Int.* 1997;7(5):407-413.
11. Woolf AD, Pflieger B. Burden of major musculoskeletal conditions. *Bull World Health Organ.* 2003;81(9):646-656.
12. Chana R, Noorani A, Ashwood N, Chatterji U, Healy J, Baird P. The role of MRI in the diagnosis of proximal femoral fractures in the elderly. *Injury.* 2006 Feb;37(2):185-189.
13. Frihagen F, Nordsletten L, Tariq R, Madsen JE. MRI diagnosis of occult hip fractures. *Acta Orthop.* 2005 Aug;76(4):524-530.
14. Verbeeten KM, Hermann KL, Hasselqvist M, Lausten GS, Joergensen P, Jensen CM, et al. The advantages of MRI in the detection of occult hip fractures. *Eur Radiol.* 2005 Jan;15(1):165-169.
15. Garden RS. Low-angle fixation in fractures of the femoral neck. *J Bone Joint Surg Br.* 1963;43:647-663.
16. Blundell CM, Parker MJ, Pryor GA, Hopkinson-Woolley J, Bhonsle SS. Assessment of the AO classification of intracapsular fractures of the proximal femur. *J Bone Joint Surg Br.* 1998 Jul;80(4):679-683.
17. Alho A, Benterud JG, Ronningen H, Hoiseth A. Prediction of disturbed healing in femoral neck fracture. Radiographic analysis of 149 cases. *Acta Orthop Scand.* 1992 Dec;63(6):639-644.

18. Bjorgul K, Reikeras O. Low interobserver reliability of radiographic signs predicting healing disturbance in displaced intracapsular fracture of the femoral neck. *Acta Orthop Scand*. 2002 Jun;73(3):307-310.
19. Totterman A, Walloe A, Nordsletten L. Interpreting preoperative radiographs in displaced femoral neck fractures: observer variability in evaluating signs of poor outcome. *Arch Orthop Trauma Surg*. 2007 Apr;127(3):185-189.
20. Thomsen NO, Jensen CM, Skovgaard N, Pedersen MS, Pallesen P, Soe-Nielsen NH, et al. Observer variation in the radiographic classification of fractures of the neck of the femur using Garden's system. *Int Orthop*. 1996;20(5):326-329.
21. Zlowodzki M, Bhandari M, Keel M, Hanson BP, Schemitsch E. Perception of Garden's classification for femoral neck fractures: an international survey of 298 orthopaedic trauma surgeons. *Arch Orthop Trauma Surg*. 2005 Sep;125(7):503-505.
22. Parker MJ, Khan RJ, Crawford J, Pryor GA. Hemiarthroplasty versus internal fixation for displaced intracapsular hip fractures in the elderly. A randomised trial of 455 patients. *J Bone Joint Surg Br*. 2002 Nov;84(8):1150-1155.
23. Frihagen F, Nordsletten L, Madsen JE. Hemiarthroplasty or internal fixation for intracapsular displaced femoral neck fractures: randomised controlled trial. *BMJ*. 2007 Dec 15;335(7632):1251-1254.
24. Rogmark C, Carlsson A, Johnell O, Sernbo I. A prospective randomised trial of internal fixation versus arthroplasty for displaced fractures of the neck of the femur. Functional outcome for 450 patients at two years. *J Bone Joint Surg Br*. 2002 Mar;84(2):183-188.
25. Parker MJ, Gurusamy K. Internal fixation versus arthroplasty for intracapsular proximal femoral fractures in adults. *Cochrane Database Syst Rev*. 2006(4):CD001708.
26. Bhandari M, Devereaux PJ, Swiontkowski MF, Tornetta P, 3rd, Obremskey W, Koval KJ, et al. Internal fixation compared with arthroplasty for displaced fractures of the femoral neck. A meta-analysis. *J Bone Joint Surg Am*. 2003 Sep;85-A(9):1673-1681.
27. Handoll HH, Parker MJ. Conservative versus operative treatment for hip fractures in adults. *Cochrane Database Syst Rev*. 2008(3):CD000337.
28. Jensen J, Hogh J. Fractures of the femoral neck. A follow-up study after non-operative treatment of Garden's stage 1 and 2 fractures. *Injury*. 1983 Jan;14(4):339-342.
29. Cserhati P, Kazar G, Manninger J, Fekete K, Frenyo S. Non-operative or operative treatment for undisplaced femoral neck fractures: a comparative study of 122 non-operative and 125 operatively treated cases. *Injury*. 1996 Oct;27(8):583-588.
30. Chen WC, Yu SW, Tseng IC, Su JY, Tu YK, Chen WJ. Treatment of undisplaced femoral neck fractures in the elderly. *J Trauma*. 2005 May;58(5):1035-1039; discussion 1039.
31. Conn KS, Parker MJ. Undisplaced intracapsular hip fractures: results of internal fixation in 375 patients. *Clin Orthop Relat Res*. 2004 Apr(421):249-254.
32. Parker MJ, White A, Boyle A. Fixation versus hemiarthroplasty for undisplaced intracapsular hip fractures. *Injury*. 2008 Jul;39(7):791-795.
33. Rogmark C, Flensburg L, Fredin H. Undisplaced femoral neck fractures--no problems? A consecutive study of 224 patients treated with internal fixation. *Injury*. 2009 Mar;40(3):274-276.
34. Vestergaard P, Rejnmark L, Mosekilde L. Has mortality after a hip fracture increased? *J Am Geriatr Soc*. 2007 Nov;55(11):1720-1726.

35. Rogmark C, Johnell O. Primary arthroplasty is better than internal fixation of displaced femoral neck fractures: a meta-analysis of 14 randomized studies with 2,289 patients. *Acta Orthop*. 2006 Jun;77(3):359-367.
36. Parker MJ, Pervez H. Surgical approaches for inserting hemiarthroplasty of the hip. *Cochrane Database Syst Rev*. 2002(3):CD001707.
37. Heetveld MJ, Rogmark C, Frihagen F, Keating J. Internal fixation versus arthroplasty for displaced femoral neck fractures: what is the evidence? *J Orthop Trauma*. 2009 Jul;23(6):395-402.
38. Blomfeldt R, Tornkvist H, Eriksson K, Soderqvist A, Ponzer S, Tidermark J. A randomised controlled trial comparing bipolar hemiarthroplasty with total hip replacement for displaced intracapsular fractures of the femoral neck in elderly patients. *J Bone Joint Surg Br*. 2007 Feb;89(2):160-165.
39. Keating JF, Grant A, Masson M, Scott NW, Forbes JF. Randomized comparison of reduction and fixation, bipolar hemiarthroplasty, and total hip arthroplasty. Treatment of displaced intracapsular hip fractures in healthy older patients. *J Bone Joint Surg Am*. 2006 Feb;88(2):249-260.
40. Baker RP, Squires B, Gargan MF, Bannister GC. Total hip arthroplasty and hemiarthroplasty in mobile, independent patients with a displaced intracapsular fracture of the femoral neck. A randomized, controlled trial. *J Bone Joint Surg Am*. 2006 Dec;88(12):2583-2589.
41. Johansson T, Jacobsson SA, Ivarsson I, Knutsson A, Wahlstrom O. Internal fixation versus total hip arthroplasty in the treatment of displaced femoral neck fractures: a prospective randomized study of 100 hips. *Acta Orthop Scand*. 2000 Dec;71(6):597-602.
42. Damany DS, Parker MJ, Chojnowski A. Complications after intracapsular hip fractures in young adults. A meta-analysis of 18 published studies involving 564 fractures. *Injury*. 2005 Jan;36(1):131-141.
43. Gray AJ, Parker MJ. Intracapsular fractures of the femoral neck in young patients. *Injury*. 1994 Dec;25(10):667-669.
44. Zetterberg CH, Irstam L, Andersson GB. Femoral neck fractures in young adults. *Acta Orthop Scand*. 1982 Jun;53(3):427-435.
45. Learmonth ID, Young C, Rorabeck C. The operation of the century: total hip replacement. *Lancet*. 2007 Oct 27;370(9597):1508-1519.
46. Moore AT, Bohlman HR. Metal hip joint: a case report. 1942. *Clin Orthop Relat Res*. 2006 Dec;453:22-24.
47. Judet J, Judet R. The use of an artificial femoral head for arthroplasty of the hip joint. *J Bone Joint Surg Br*. 1950 May;32-B(2):166-173.
48. Thompson FR. Vitallium intramedullary hip prosthesis, preliminary report. *N Y State J Med*. 1952 Dec 15;52(24):3011-3020.
49. Thompson FR. Experiences with a vitallium intramedullary hip prosthesis. *Tex State J Med*. 1953 Oct;49(10):749-756.
50. Thompson FR. Two and a half years' experience with a vitallium intramedullary hip prosthesis. *J Bone Joint Surg Am*. 1954 Jun;36-A(3):489-502.
51. Moore AT. Metal hip joint; a new self-locking vitallium prosthesis. *South Med J*. 1952 Nov;45(11):1015-1019.
52. Moore AT. The self-locking metal hip prosthesis. *J Bone Joint Surg Am*. 1957 Jul;39-A(4):811-827.
53. Crossman PT, Khan RJ, MacDowell A, Gardner AC, Reddy NS, Keene GS. A survey of the treatment of displaced intracapsular femoral neck fractures in the UK. *Injury*. 2002 Jun;33(5):383-386.

54. Salvati EA, Wilson PD, Jr. Long-term results of femoral-head replacement. *J Bone Joint Surg Am.* 1973 Apr;55(3):516-524.
55. Sarmiento A. Austin Moore prosthesis in the arthritic hip. Experiences with 224 patients. *Clin Orthop Relat Res.* 1972 Jan-Feb;82:14-23.
56. Drinker H, Murray WR. The universal proximal femoral endoprosthesis. A short-term comparison with conventional hemiarthroplasty. *J Bone Joint Surg Am.* 1979 Dec;61(8):1167-1174.
57. Soreide O, Lillestol J, Alho A, Hvidsten K. Acetabular protrusion following endoprosthetic hip surgery: a multifactorial study. *Acta Orthop Scand.* 1980 Dec;51(6):943-948.
58. Eiskjaer S, Ostgard SE. Survivorship analysis of hemiarthroplasties. *Clin Orthop Relat Res.* 1993 Jan(286):206-211.
59. Christiansen T. A new hip prosthesis with trunnion-bearing. *Acta Chir Scand.* 1969;135(1):43-46.
60. Soreide O, Lerner AP, Thunold J. Primary prosthetic replacement in acute femoral neck fractures. *Injury.* 1975 May;6(4):286-293.
61. Meyer S. Prosthetic replacement in hip fractures: a comparison between the Moore and Christiansen endoprostheses. *Clin Orthop Relat Res.* 1981 Oct(160):57-62.
62. Bateman JE. The classic: single-assembly total hip prosthesis-preliminary report. 1974. *Clin Orthop Relat Res.* 2005 Dec;441:16-18.
63. Devas M, Hinves B. Prevention of acetabular erosion after hemiarthroplasty for fractured neck of femur. *J Bone Joint Surg Br.* 1983 Nov;65(5):548-551.
64. Haidukewych GJ, Israel TA, Berry DJ. Long-term survivorship of cemented bipolar hemiarthroplasty for fracture of the femoral neck. *Clin Orthop Relat Res.* 2002 Oct(403):118-126.
65. LaBelle LW, Colwill JC, Swanson AB. Bateman bipolar hip arthroplasty for femoral neck fractures. A five- to ten-year follow-up study. *Clin Orthop Relat Res.* 1990 Feb(251):20-25.
66. Isotalo K, Rantanen J, Aarimaa V, Gullichsen E. The long-term results of Lubinus interplanta hemiarthroplasty in 228 acute femoral neck fractures. A retrospective six-year follow-up. *Scand J Surg.* 2002;91(4):357-360.
67. Bezwada HP, Shah AR, Harding SH, Baker J, Johanson NA, Mont MA. Cementless bipolar hemiarthroplasty for displaced femoral neck fractures in the elderly. *J Arthroplasty.* 2004 Oct;19(7 Suppl 2):73-77.
68. Wada M, Imura S, Baba H. Use of osteonics UHR hemiarthroplasty for fractures of the femoral neck. *Clin Orthop Relat Res.* 1997 May(338):172-181.
69. Wetherell RG, Hinves BL. The Hastings bipolar hemiarthroplasty for subcapital fractures of the femoral neck. A 10-year prospective study. *J Bone Joint Surg Br.* 1990 Sep;72(5):788-793.
70. Langan P. The Giliberty bipolar prosthesis: a clinical and radiographical review. *Clin Orthop Relat Res.* 1979 Jun(141):169-175.
71. Verberne GH. A femoral head prosthesis with a built-in joint. A radiological study of the movements of the two components. *J Bone Joint Surg Br.* 1983 Nov;65(5):544-547.
72. Bochner RM, Pellicci PM, Lyden JP. Bipolar hemiarthroplasty for fracture of the femoral neck. Clinical review with special emphasis on prosthetic motion. *J Bone Joint Surg Am.* 1988 Aug;70(7):1001-1010.
73. Hodgkinson JP, Meadows TH, Davies DR, Hargadon EJ. A radiological assessment of interprosthetic movement in the Charnley-Hastings hemiarthroplasty. *Injury.* 1988 Jan;19(1):18-20.

74. Chen SC, Badrinath K, Pell LH, Mitchell K. The movements of the components of the Hastings bipolar prosthesis. A radiographic study in 65 patients. *J Bone Joint Surg Br.* 1989 Mar;71(2):186-188.
75. Mess D, Barmada R. Clinical and motion studies of the Bateman bipolar prosthesis in osteonecrosis of the hip. *Clin Orthop Relat Res.* 1990 Feb(251):44-47.
76. Gaine WJ, Sanville PR, Bamford DJ. The Charnley-Hastings bipolar prosthesis in femoral neck fractures - a study of dynamic motion. *Injury.* 2000 May;31(4):257-263.
77. Raia FJ, Chapman CB, Herrera MF, Schweppe MW, Michelsen CB, Rosenwasser MP. Unipolar or bipolar hemiarthroplasty for femoral neck fractures in the elderly? *Clin Orthop Relat Res.* 2003 Sep(414):259-265.
78. Calder SJ, Anderson GH, Jagger C, Harper WM, Gregg PJ. Unipolar or bipolar prosthesis for displaced intracapsular hip fracture in octogenarians. A randomised prospective study. *J Bone Jt Surg Ser B.* 1996;78(3):391-394.
79. Davison JN, Calder SJ, Anderson GH, Ward G, Jagger C, Harper WM, et al. Treatment for displaced intracapsular fracture of the proximal femur. A prospective, randomised trial in patients aged 65 to 79 years. *J Bone Joint Surg Br.* 2001 Mar;83(2):206-212.
80. Cornell CN, Levine D, O'Doherty J, Lyden J. Unipolar versus bipolar hemiarthroplasty for the treatment of femoral neck fractures in the elderly. *Clin Orthop Relat Res.* 1998 Mar(348):67-71.
81. Livesley PJ, Srivastava VM, Needoff M, Prince HG, Moulton AM. Use of a hydroxyapatite-coated hemiarthroplasty in the management of subcapital fractures of the femur. *Injury.* 1993 Apr;24(4):236-240.
82. Parker MJ, Gurusamy K. Arthroplasties (with and without bone cement) for proximal femoral fractures in adults. *Cochrane Database Syst Rev.* 2006;3:CD001706.
83. Ahn J, Man LX, Park S, Sodl JF, Esterhai JL. Systematic review of cemented and uncemented hemiarthroplasty outcomes for femoral neck fractures. *Clin Orthop Relat Res.* 2008 Oct;466(10):2513-2518.
84. Norrish AR, Rao J, Parker MJ. Prosthesis survivorship and clinical outcome of the Austin Moore hemiarthroplasty: An 8-year mean follow-up of a consecutive series of 500 patients. *Injury.* 2006 Aug;37(8):734-739.
85. Duncan JA. Intra-operative collapse or death related to the use of acrylic cement in hip surgery. *Anaesthesia.* 1989 Feb;44(2):149-153.
86. Lennox IA, McLauchlan J. Comparing the mortality and morbidity of cemented and uncemented hemiarthroplasties. *Injury.* 1993 Mar;24(3):185-186.
87. Parvizi J, Ereth MH, Lewallen DG. Thirty-day mortality following hip arthroplasty for acute fracture. *J Bone Joint Surg Am.* 2004 Sep;86-A(9):1983-1988.
88. Parvizi J, Holiday AD, Ereth MH, Lewallen DG. The Frank Stinchfield Award. Sudden death during primary hip arthroplasty. *Clin Orthop Relat Res.* 1999 Dec(369):39-48.
89. Holt EM, Evans RA, Hindley CJ, Metcalfe JW. 1000 femoral neck fractures: the effect of pre-injury mobility and surgical experience on outcome. *Injury.* 1994 Mar;25(2):91-95.
90. Berry DJ. Epidemiology: hip and knee. *Orthop Clin North Am.* 1999 Apr;30(2):183-190.
91. Wrighton JD, Woodyard JE. Prosthetic replacement for subcapital fractures of the femur: a comparative survey. *Injury.* 1971 Apr;2(4):287-293.

92. Sadr B, Arden GP. A comparison of the stability of proplast-coated and cemented Thompson prostheses in the treatment of subcapital femoral fractures. *Injury*. 1977 Feb;8(3):234-237.
93. Suman RK. Prosthetic replacement of the femoral head for fractures of the neck of the femur: a comparative study. *Injury*. 1980 May;11(4):309-316.
94. Sonne-Holm S, Walter S, Jensen JS. Moore hemi-arthroplasty with and without bone cement in femoral neck fractures. A clinical controlled trial. *Acta Orthop Scand*. 1982 Dec;53(6):953-956.
95. Lausten GS, Vedel P. Cementing v. not cementing the Monk endoprosthesis. *Injury*. 1982 May;13(6):484-488.
96. Dorr LD, Glousman R, Hoy AL, Vanis R, Chandler R. Treatment of femoral neck fractures with total hip replacement versus cemented and noncemented hemiarthroplasty. *J Arthroplasty*. 1986;1(1):21-28.
97. Lausten GS, Vedel P, Nielsen PM. Fractures of the femoral neck treated with a bipolar endoprosthesis. *Clin Orthop Relat Res*. 1987 May(218):63-67.
98. Gebhard JS, Amstutz HC, Zinar DM, Dorey FJ. A comparison of total hip arthroplasty and hemiarthroplasty for treatment of acute fracture of the femoral neck. *Clin Orthop Relat Res*. 1992 Sep(282):123-131.
99. Emery RJ, Broughton NS, Desai K, Bulstrode CJ, Thomas TL. Bipolar hemiarthroplasty for subcapital fracture of the femoral neck. A prospective randomised trial of cemented Thompson and uncemented Moore stems. *J Bone Joint Surg Br*. 1991 Mar;73(2):322-324.
100. Lo WH, Chen WM, Huang CK, Chen TH, Chiu FY, Chen CM. Bateman bipolar hemiarthroplasty for displaced intracapsular femoral neck fractures. Uncemented versus cemented. *Clin Orthop Relat Res*. 1994 May(302):75-82.
101. Faraj AA, Branfoot T. Cemented versus uncemented Thompson's prostheses: a functional outcome study. *Injury*. 1999 Dec;30(10):671-675.
102. Branfoot T, Faraj AA, Porter P. Cemented versus uncemented Thompson's prostheses: a randomised prospective functional outcome study. *Injury*. 1999;31(4):280-281.
103. Khan RJ, MacDowell A, Crossman P, Datta A, Jallali N, Arch BN, et al. Cemented or uncemented hemiarthroplasty for displaced intracapsular femoral neck fractures. *Int Orthop*. 2002;26(4):229-232.
104. Foster AP, Thompson NW, Wong J, Charlwood AP. Periprosthetic femoral fractures--a comparison between cemented and uncemented hemiarthroplasties. *Injury*. 2005 Mar;36(3):424-429.
105. Santini S, Rebecato A, Bolgan I, Turi G. Hip fractures in elderly patients treated with bipolar hemiarthroplasty: Comparison between cemented and cementless implants. *J Orthop Traumatol*. 2005 Jun;6(2):80-87.
106. Singh GK, Deshmukh RG. Uncemented Austin-Moore and cemented Thompson unipolar hemiarthroplasty for displaced fracture neck of femur--comparison of complications and patient satisfaction. *Injury*. 2006 Feb;37(2):169-174.
107. Parker MI, Pryor G, Gurusamy K. Cemented versus uncemented hemiarthroplasty for intracapsular hip fractures: A randomised controlled trial in 400 patients. *J Bone Joint Surg Br*. 2010 Jan;92(1):116-122.
108. Havelin LI, Espehaug B, Vollset SE, Engesaeter LB, Langeland N. The Norwegian arthroplasty register. A survey of 17,444 hip replacements 1987-1990. *Acta Orthop Scand*. 1993 Jun;64(3):245-251.
109. Engesaeter LB, Havelin LI, Espehaug B, Vollset SE. [Artificial hip joints in Norway. A national registry of total hip arthroplasties]. *Tidsskr Nor Laegeforen*. 1992 Mar 10;112(7):872-875.



110. Arthursson AJ, Furnes O, Espehaug B, Havelin LI, Soreide JA. Validation of data in the Norwegian Arthroplasty Register and the Norwegian Patient Register: 5,134 primary total hip arthroplasties and revisions operated at a single hospital between 1987 and 2003. *Acta Orthop*. 2005 Dec;76(6):823-828.
111. Espehaug B, Furnes O, Havelin LI, Engesaeter LB, Vollset SE, Kindseth O. Registration completeness in the Norwegian Arthroplasty Register. *Acta Orthop*. 2006 Feb;77(1):49-56.
112. Harris WH. Traumatic arthritis of the hip after dislocation and acetabular fractures: treatment by mold arthroplasty. An end-result study using a new method of result evaluation. *J Bone Joint Surg Am*. 1969 Jun;51(4):737-755.
113. EuroQol\_Group. EuroQol--a new facility for the measurement of health-related quality of life. *Health Policy*. 1990 Dec;16(3):199-208.
114. Mahoney FI, Barthel DW. Functional Evaluation: The Barthel Index. *Md State Med J*. 1965 Feb;14:61-65.
115. Soderman P, Malchau H. Is the Harris hip score system useful to study the outcome of total hip replacement? *Clin Orthop Relat Res*. 2001 Mar(384):189-197.
116. Frihagen F, Grotle M, Madsen JE, Wyller TB, Mowinckel P, Nordsletten L. Outcome after femoral neck fractures: a comparison of Harris Hip Score, Eq-5d and Barthel Index. *Injury*. 2008 Oct;39(10):1147-1156.
117. Greiner W, Weijnen T, Nieuwenhuizen M, Oppe S, Badia X, Busschbach J, et al. A single European currency for EQ-5D health states. Results from a six-country study. *Eur J Health Econ*. 2003 Sep;4(3):222-231.
118. Digas G. New polymer materials in total hip arthroplasty. Evaluation with radiostereometry, bone densitometry, radiography and clinical parameters. *Acta Orthop Suppl*. 2005 Feb;76(315):3-82.
119. Freeman MA, Plante-Bordeneuve P. Early migration and late aseptic failure of proximal femoral prostheses. *J Bone Joint Surg Br*. 1994 May;76(3):432-438.
120. Karrholm J, Herberts P, Hultmark P, Malchau H, Nivbrant B, Thanner J. Radiostereometry of hip prostheses. Review of methodology and clinical results. *Clin Orthop Relat Res*. 1997 Nov(344):94-110.
121. Karrholm J. Roentgen stereophotogrammetry. Review of orthopedic applications. *Acta Orthop Scand*. 1989 Aug;60(4):491-503.
122. Field JR, Stanley R, Appleyard R, McGee M, Callary S, Nilsson K. An evaluation of prosthetic femoral head impact on acetabular articular cartilage in a hemiarthroplasty model. *Vet Comp Orthop Traumatol*. 2009;22(2):142-147.
123. Schemper M, Smith TL. A note on quantifying follow-up in studies of failure time. *Control Clin Trials*. 1996 Aug;17(4):343-346.
124. Piaggio G, Elbourne DR, Altman DG, Pocock SJ, Evans SJ. Reporting of noninferiority and equivalence randomized trials: an extension of the CONSORT statement. *JAMA*. 2006 Mar 8;295(10):1152-1160.
125. Sokal R, Rohlf F. *Biometry: The Principles and Practice of Statistics in Biological Research*. 1995(3rd edition):86.
126. Moher D, Schulz KF, Altman DG. The CONSORT statement: revised recommendations for improving the quality of reports of parallel-group randomised trials. *Lancet*. 2001 Apr 14;357(9263):1191-1194.
127. Blewitt N, Mortimore S. Outcome of dislocation after hemiarthroplasty for fractured neck of the femur. *Injury*. 1992;23(5):320-322.

128. Sierra RJ, Schleck CD, Cabanela ME. Dislocation of bipolar hemiarthroplasty: rate, contributing factors, and outcome. *Clin Orthop Relat Res.* 2006 Jan;442:230-238.
129. Ninh CC, Sethi A, Hatahet M, Les C, Morandi M, Vaidya R. Hip dislocation after modular unipolar hemiarthroplasty. *J Arthroplasty.* 2009 Aug;24(5):768-774.
130. Khatod M, Barber T, Paxton E, Namba R, Fithian D. An analysis of the risk of hip dislocation with a contemporary total joint registry. *Clin Orthop Relat Res.* 2006 Jun;447:19-23.
131. Lu-Yao GL, Keller RB, Littenberg B, Wennberg JE. Outcomes after displaced fractures of the femoral neck. A meta-analysis of one hundred and six published reports. *J Bone Joint Surg Am.* 1994 Jan;76(1):15-25.
132. Enocson A, Tidermark J, Tornkvist H, Lapidus LJ. Dislocation of hemiarthroplasty after femoral neck fracture: better outcome after the anterolateral approach in a prospective cohort study on 739 consecutive hips. *Acta Orthop.* 2008 Apr;79(2):211-217.
133. Gjertsen JE, Engesaeter LB, Furnes O, Havelin LI, Steindal K, Vinje T, et al. The Norwegian Hip Fracture Register: experiences after the first 2 years and 15,576 reported operations. *Acta Orthop.* 2008 Oct;79(5):583-593.
134. Gjertsen JE, Lie SA, Fevang JM, Havelin LI, Engesaeter LB, Vinje T, et al. Total hip replacement after femoral neck fractures in elderly patients : results of 8,577 fractures reported to the Norwegian Arthroplasty Register. *Acta Orthop.* 2007 Aug;78(4):491-497.
135. Stambough JL, Balderston RA, Booth RE, Jr., Rothman RH, Cohn JC. Conversion total hip replacement. Review of 140 hips with greater than 6-year follow-up study. *J Arthroplasty.* 1986;1(4):261-269.
136. Suominen S. Total hip replacement after failed hemiarthroplasty. *Ann Chir Gynaecol.* 1989;78(4):309-315.
137. Bilgen O, Karaeminogullari O, Kulercioglu A. Results of conversion total hip prosthesis performed following painful hemiarthroplasty. *J Int Med Res.* 2000 Nov-Dec;28(6):307-312.
138. Llinas A, Sarmiento A, Ebramzadeh E, Gogan WJ, McKellop HA. Total hip replacement after failed hemiarthroplasty or mould arthroplasty. Comparison of results with those of primary replacements. *J Bone Joint Surg Br.* 1991 Nov;73(6):902-907.
139. Sierra RJ, Cabanela ME. Conversion of failed hip hemiarthroplasties after femoral neck fractures. *Clin Orthop Relat Res.* 2002 Jun(399):129-139.
140. Champion LM, McNally SA. Dislocation after revision of hemiarthroplasty to total hip replacement. *Injury.* 2004 Feb;35(2):161-164.
141. Pankaj A, Malhotra R, Bhan S. Conversion of failed hemiarthroplasty to total hip arthroplasty: A short to mid-term follow-up study. *Indian J Orthop.* 2008 Jul;42(3):294-300.
142. Diwanji SR, Kim SK, Seon JK, Park SJ, Yoon TR. Clinical results of conversion total hip arthroplasty after failed bipolar hemiarthroplasty. *J Arthroplasty.* 2008 Oct;23(7):1009-1015.
143. Semenowicz J, Koczy B, Czuma P, Pijet B, Olszewski T, Walo R. [Avantage double mobility press--fit cup in total hip arthroplasty]. *Chir Narzadow Ruchu Ortop Pol.* 2007 Jan-Feb;72(1):33-36.
144. Hallan G, Lie SA, Furnes O, Engesaeter LB, Vollset SE, Havelin LI. Medium- and long-term performance of 11,516 uncemented primary femoral stems from the Norwegian arthroplasty register. *J Bone Joint Surg Br.* 2007 Dec;89(12):1574-1580.

145. Lindahl H, Malchau H, Herberts P, Garellick G. Periprosthetic femoral fractures classification and demographics of 1049 periprosthetic femoral fractures from the Swedish National Hip Arthroplasty Register. *J Arthroplasty*. 2005 Oct;20(7):857-865.
146. Meijerink HJ, Gardeniers JW, Buma P, Lemmens JA, Schreurs BW. Hydroxyapatite does not improve the outcome of a bipolar hemiarthroplasty. *Clin Orthop Relat Res*. 2004 Apr(421):143-150.



## **Appendix 1 – Norwegian Arthroplasty Register forms**

Registrasjon form The Norwegian Arthroplasty Register 1987-1992 (Norwegian)

**NASJONALT REGISTER FOR  
TOTALPROTESER I HOFTLEDD**

Ortopedisk avdeling  
Haukeland sykehus,  
5021 BERGEN

F. nr. (11 sifre) :

Navn:

Sykehus:

(Bruk blokkbokstaver)

**ANAMNESE:**

1. SMERTER (ett kryss):
- 1 Sterke spontane i hvile og om natten.
  - 2 Sterke som hindrer all gangaktivitet.
  - 3 Moderate, tillater begrenset gange.
  - 4 Etter noe aktivitet, forsvinner i hvile.
  - 5 Lette eller periodevise. Startsmarter.
  - 6 Ingen smerter.
2. GANGEVNE (ett kryss):
- 1 Få meter med 2 krykker/stokker/sengeliggende.
  - 2 Sterkt begrenset med eller uten stokker.
  - 3 Begrenset med stokk (under en time). Kan stå lenge.
  - 4 Kan gå lange avstander med en stokk.
  - 5 Ingen stokk, men halter.
  - 6 Normal gangevne.

3. FUNKSJONSGRUPPE (ett kryss):
- 1 Aktuelle hofte syk ellers frisk.
  - 2 Begge hofter syke ellers frisk.
  - 3 Annet som reduserer gangevnen.
4. TIDLIGERE OPERASJON(ER) I AKTUELLE HOFTE: (evt. flere kryss)
- 0 Nei
  - 1 Osteosyntese pga. fraktur i prox.femurende.
  - 2 Hemiprotese pga. fraktur
  - 3 Osteotomi.
  - 4 Artrodese.
  - 5 Totalprotese(r) Type(r): .....
  - År/stall siste protese:
  - Annet: .....
5. VARIGHET AV SYMPT. I AKT. HOFTE:   år (under 1 år = 0).

**OPERASJONSOPPLYSNINGER:**

6. OPERASJONS DATO:   dag   mnd   år

7. AKTUELLE OPERASJON ER (ett kryss).
- 1 Primær totalproteseoperasjon.
  - 2 Reoperasjon.

8. AKTUELLE SIDE (ett kryss):
- 1 Høyre
  - 2 Venstre
  - 3 Høyre - venstre allerede protese.
  - 4 Venstre - høyre allerede protese.

9. AKTUELLE HOFTEOPERASJON ER (ett kryss).

- a) Primæroperasjon pga.:
- 1 Idiopatisk coxartrose
  - 2 Rheumatoid artritt.
  - 3 Seq.fr. colli fem.
  - 4 Seq.dysplasi.
  - 5 Seq.dysplasi med luksasjon.
  - 6 Seq.Perthes/epifys.
  - 7 Bechterew.
  - 8 Annet: .....

- b) Reoperasjon pga. (evt. flere kryss):

- 1 Løsning av acetabulardel.
- 2 Løsning av femurdelen.
- 3 Luksasjon.
- 4 Dyp infeksjon.
- 5 Fraktur av femur.
- 6 Smerter.
- 7 Annet: .....

10. HVIS reoperasjon (ett kryss):

- 1 Reop. - bytte av femurdelen.
- 2 Reop. - bytte av acetabulardelen.
- 3 Reop. - bytte av hele protesen.
- 4 Reop. - annet: (f.eks. Girdlestone) .....

11. TILGANG (ett kryss):

- 1 Fremre (Smith-Petersen).
- 2 Anterolateral.
- 3 Lateral.
- 4 Posterolateral
- 5 Annen: .....

12. TROCHANTEROSTEOTOMI:

- 0 Nei
- 1 Ja

13. BENTRANSPLANTASJON:

- 0 Nei
- 1 I acetabulum.
- 2 I femur.
- 3 I acetabulum og femur.

**PROTESE. NAVN/TYPE (Spesifiser nøyaktig):**

14. Acetabulum:
- Navn/Type: .....
  - Evt. Kat. nr.: .....
  - 1 Sement med antibiotika. Navn: .....
  - 2 Sement uten antibiotika. Navn: .....
  - 3 Ikke sementert.

15. Femur:

- Navn/Type: .....
- Evt. Kat. nr.: .....
- 1 Sement med antibiotika. Navn: .....
- 2 Sement uten antibiotika. Navn: .....
- 3 Ikke sementert.

16. Caput:

- 1 Fastsittende caput.
- 2 Separat caput. Navn/Type: .....
- Evt. Kat. nr.: ..... Diam.: .....

17. SYSTEMISK ANTIBIOTIKAPROFYLAKSE:

- 0 Nei
- 1 Ja. Hvilken: .....
- Dose: .....
- Varighet: .....

18. OPERASJONSSTUE:

- 1 "Green house"
- 2 Operasjonsstue med laminær luftstrøm.
- 3 Vanlig operasjonsstue.

19. OPERASJONSTID (hud til hud):    min.

20. PEROPERATIVE KOMPLIKASJONER:

- 0 Nei.
- 1 Ja. Hvilken: .....

Lege : .....  
( Legen som har fylt ut skjemaet )

# Registrasjon form The Norwegian Arthroplasty Register 1993-2004 (Norwegian)

## NASJONALT REGISTER FOR LEDDPROTESER

● ● ● ●  
 Ortopedisk klinikk, Helse Bergen  
 Besøksadresse: Haukeland Universitetssykehus  
 Postadresse: 5021 BERGEN  
 Tlf.: 55 97 37 42 / 55 97 37 43

1. F.nr. (11 sifre) .....

Navn: .....

2. Sykehus: .....

(Skriv tydelig!)

## HOFTEPROTESER

ALLE TOTALPROTESER I HOFTELEDD REGISTRERES (ikke hemiprotetser)  
 Innsetting, skifting eller fjerning av protese eller protesedeler.

### 4. TIDLIGERE OPERASJON I AKTUELLE HOFTE (evt. flere kryss)

- 0 Nei
- 1 Osteosyntese for fraktur i prox. femurende
- 2 Hemiprotese pga fraktur
- 3 Osteotomi
- 4 Artrodese
- 5 Totalprotese(r)
- 6 Annen operasjon .....

5. Hvis protese tidligere, TYPE(R): .....

Årstall siste protese: [ ] [ ]  
 Antall proteser tidligere i aktuelle hofte: [ ] [ ]

6. OPERASJONSDATO: [ ] [ ] [ ] [ ] [ ] [ ]  
 dag mnd år

### 7. AKTUELLE OPERASJON ER (ett kryss):

- 1 Primæroperasjon (Også hvis hemiprotese tidl.)
- 2 Reoperasjon (totalprotese tidligere)

### 8. AKTUELLE SIDE (ett kryss):

(Bilateral opr. = 2 skjema)

- 1 Hø
- 2 Ve
- 3 Hø - Venstre allerede protese
- 4 Ve - Høyre allerede protese

### 9. AKTUELLE OPERASJON ER:

(Kryss av enten i 9A eller 9B)

#### A. Primæroperasjon pga. (ett kryss):

- 1 Idiopatisk coxartrose
- 2 Rheumatoid artritt
- 3 Sequele etter frakt. colli fem.
- 4 Seqv. dysplasi
- 5 Seqv. dysplasi med total luksasjon
- 6 Seqv. Perthes/Epifysiolyse
- 7 Mb. Bechterew
- 8 Annet: .....
- (f.eks. caputnekrose, tidl. artrodese o.l.)
- Akutt fraktura colli femoris

#### B. Reoperasjon pga. (evt. flere kryss):

- 1 Løs acetabular komponent
- 2 Løs femur komponent
- 3 Luksasjon
- 4 Dyp infeksjon
- 5 Fraktur (ved protesen)
- 6 Smarter
- 7 Annet .....
- (f.eks. Girdlestone etter tidl. infisert protese, protese/ fraktur, utsitt plastforing osv.)
- Osteolyse i acetab. uten løsning
- Osteolyse i femur uten løsning

### 10. REOPERASJONSTYPE (evt. flere kryss):

- 1 Bytte av femur komponent
- 2 Bytte av acetabular komponent
- 3 Bytte av hele protesen
- 4 Andre operasjoner:
- Fjernet protese (f.eks. Girdlestone).
- Angi hvilke deler som ble fjernet: .....
- Bytte av plastforing
- Bytte av caput
- Annet: .....

### 11. TILGANG

- 1 Fremre (Smith-Petersen)
- 2 Anterolateral
- 3 Lateral
- 4 Posterolateral
- 5 Annen: .....

### 12. TROCHANTEROSTEOTOMI

- 0 Nei
- 1 Ja

### 13. BENTRANSPLANTASJON

- 0 Nei
- 1 acetabulum
- 2 femur
- 3 acetabulum og femur
- 4 Benpakking i acetabulum (impaksjon)
- 5 Benpakking i femur (impaksjon a. m. Ling/Gie)

### PROTESE: NAVN/DESIGN/"COATING"

Spesifiser nøyaktig eller bruk klistrelapp på baksida

#### 14. Acetabulum

- Navn/Type: .....
- Evt. katalognummer: .....
- Med hydroksylapatitt  Uten HA
  - 1 Sement med antibiotika - Navn: .....
  - 2 Sement uten antibiotika - Navn: .....
  - 3 Usementert

#### 15. Femur

- Navn/Type: .....
- Evt. katalognummer: .....
- Med hydroksylapatitt  Uten HA
  - 1 Sement med antibiotika - Navn: .....
  - 2 Sement uten antibiotika - Navn: .....
  - 3 Usementert

#### 16. Caput

- 1 Fastsittende caput
  - 2 Separat caput - Navn/Type: .....
- Evt. katalognummer: .....
- Diameter: [ ] [ ] millimeter

### 17. SYSTEMISK ANTIBIOTIKAPROFYLAKSE:

- 0 Nei
  - 1 Ja, hvilken .....
- Dose: .....
- Varighet (antall døgn): [ ] [ ]

### 18. OPERASJONSTUE

- 1 "Green house"
- 2 Operasjonstue med laminær luftstrøm
- 3 Vanlig operasjonstue

### 19. OPERASJONSTID (HUD TIL HUD): [ ] [ ] [ ] MINUTTER

### 20. PEROPERATIV KOMPLIKASJON

- 0 Nei
- 1 Ja, hvilken: .....

Legge: .....

Legen som har fylt ut skjemaet, (navnet registreres ikke)

Registration form The Norwegian Arthroplasty Register 1993-2004 (English translation)

THE NORWEGIAN ARTHROPLASTY REGISTER (TOTAL HIP REPLACEMENTS)	
Patient:	Hospital:
<p><b>Previous operation in index hip:</b>                      0 No                      1 Osteosynthesis for prox. femur fracture                      2 Hemiprosthesis                      3 Osteotomy                      4 Arthrodesis                      5 Total hip prosthesis                      Type: .....                      Year: .....                      Number: .....                      6 Other operation: .....</p> <p><b>Date of operation:</b> .....</p> <p><b>Index operation is:</b>                      1 Primary operation                      2 Revision</p> <p><b>Hip:</b>                      1 Right                      2 Left                      3 Right, prosthesis in left hip                      4 Left, prosthesis in right hip</p> <p><b>Diagnosis (primary operation):</b>                      1 Idiopathic coxarthrosis                      2 Rheumatoid arthritis                      3 Sequelae after hip fracture                      4 Sequelae after dysplasia                      5 Sequelae after dysplasia with dislocation                      6 Sequelae after slipped capital femoral epiphysis                      or Perthes disease                      7 Ankylosing spondylitis                      8 Other: .....</p> <p><b>Reasons for revision (one or more):</b>                      1 Loosening of acetabular component                      2 Loosening of femoral component                      3 Dislocation                      4 Deep infection                      5 Fracture of femur                      6 Pain                      7 Other: .....                      8 Osteolysis of acetabular component, no loosening                      9 Osteolysis of femoral component, no loosening</p> <p><b>Revision:</b>                      1 Change of femoral component                      2 Change of acetabular component                      3 Change of all components                      4 Other:                      - Removal of component (e.g. Girdlestone)                      Which parts: .....                      - Exchange of PE liner only                      - Exchange of caput only                      - Other: .....</p>	<p><b>Approach:</b>                      1 Anterior                      2 Anterolateral                      3 Lateral                      4 Posterolateral</p> <p><b>Osteotomy of trochanter:</b>                      1 Yes                      2 No</p> <p><b>Bone transplantation:</b>                      1 No                      2 In acetabulum                      3 In femur                      4 In both</p> <p><b>Acetabulum:</b>                      Name/type: .....                      Catalogue number: .....                      Hydroxyapatite coated: 1 Yes 2 No                      1 Cement with antibiotic. Name: .....                      2 Cement without antibiotic. Name: .....                      3 Uncemented</p> <p><b>Femur:</b>                      Name/type: .....                      Catalogue number: .....                      Hydroxyapatite coated: 1 Yes 2 No                      1 Cement with antibiotic. Name: .....                      2 Cement without antibiotic. Name: .....                      3 Uncemented</p> <p><b>Caput:</b>                      1 Fixed caput                      2 Modular system.                      Name/type: .....                      Catalogue number: .....                      Diameter (mm): .....</p> <p><b>Systemic antibiotic prophylaxis:</b>                      1 No 2 Yes.                      Name: .....                      Dosage: .....                      Duration (days): .....</p> <p><b>Operating theatre:</b>                      1 'Green house'                      2 With laminar air flow                      3 Without laminar airflow</p> <p><b>Duration of operation:</b>                      Skin to skin (min.):</p> <p><b>Perioperative complication:</b>                      1 No                      2 Yes. Name: .....</p> <p><b>Surgeon (who has filled in the form):</b>                      .....                      (Surgeon name is not registered)</p>



# Registreringsskjema The Norwegian Arthroplasty Register 2005- (Norwegian)

**H** **Nasjonalt Register for Leddproteser**  
 Ortopedisk klinikk, Helse Bergen HF  
 Haukeland Universitetssykehus  
 Møllendalsbakken 11  
 5021 BERGEN  
 tlf 55973742/55973743

F.nr. (11 sifre).....  
 Navn:.....  
 (Skriv tydelig ev. pasient klistrelapp – spesifiser sykehus.)  
 Sykehus:.....

## HOFTEPROTESER

ALLE TOTALPROTESER I HOFTELEDD REGISTRERES (ved hemiprotetser etter hoftebrudd sendes hoftebruddskjema til Hoftebruddregisteret). Innsetting, skifting eller fjerning av protese eller protesedeler.

### TIDLIGERE OPERASJON I AKTUELLE HOFTE (ev. flere kryss)

- 0 Nei
- 1 Osteosyntese for fraktur i prox. femurende
- 2 Hemiprotese pga. fraktur
- 3 Osteotomi
- 4 Arthrodes
- 5 Totalprotese(r)
- 9 Annen operasjon .....

OPERASJONSDATO (dd.mm.åå)      | | | | | | | |

### AKTUELLE OPERASJON (ett kryss)

- 1 Primæroperasjon (også hvis hemiprotese tidligere)
- 2 Reoperasjon (totalprotese tidligere)

### AKTUELLE SIDE (ett kryss) (Bilateral opr.= 2 skjema)

- 1 Høyre  2 Venstre

### AKTUELLE OPERASJON (KRYSS AV ENTEN I A ELLER B)

- A . Primæroperasjon pga. (ev. flere kryss)**
- 1 Idiopatisk coxartrose
  - 2 Rheumatoid artritt
  - 3 Sekvelte etter frakt. colli. fem.
  - 4 Sekv. dysplasi
  - 5 Sekv. dysplasi med total luksasjon
  - 6 Sekv. Perthes/Epifysiolyse
  - 7 Mb. Bechterew
  - 8 Akutt fraktura colli femoris
  - 9 Annet .....
- (f.eks caputnekrose, tidl. arthrodes o.l.)

- B . Reoperasjon pga. (ev. flere kryss)**
- 1 Løs acetabularkomponent
  - 2 Løs femurkomponent
  - 3 Luksasjon
  - 4 Dyp infeksjon
  - 5 Fraktur (ved protesen)
  - 6 Smerter
  - 7 Osteolyse i acetab. uten løsning
  - 8 Osteolyse i femur uten løsning
  - 9 Annet .....
- (f.eks Girdlestone eller tidl. infisert protese)

### REOPERASJONSTYPE (ev. flere kryss)

- 1 Bytte av femurkomponent
- 2 Bytte av acetabularkomponent
- 3 Bytte av hele protesen
- 4 Fjernet protese (f.eks Girdlestone)
- Angi hvilke deler som ble fjernet .....
- 5 Bytte av plastforing
- 6 Bytte av caput
- 9 Andre operasjoner .....

### TILGANG (ett kryss)

- 1 Fremre (Smith-Petersen)       3 Lateral
- 2 Anterolateral                       4 Posterolateral
- 5 Annen .....

### LEIE

- 0 Sideleie       1 Rygg

### TROCHANTEROSTEOTOMI

- 0 Nei       1 Ja

### BENTRANSPLANTASJON (ev. flere kryss)

- Acetabulum     0 Nei     1 Ja     2 Benpakking
- Femur           0 Nei     1 Ja     2 Benpakking a.m. Ling/Gie

### BENTAP VED REVISJON (Paprosky's klassifikasjon se baksiden)

- |                                       |                                       |
|---------------------------------------|---------------------------------------|
| <b>Acetabulum</b>                     | <b>Femur</b>                          |
| <input type="checkbox"/> 1 Type I     | <input type="checkbox"/> 1 Type I     |
| <input type="checkbox"/> 2 Type II A  | <input type="checkbox"/> 2 Type II    |
| <input type="checkbox"/> 3 Type II B  | <input type="checkbox"/> 3 Type III A |
| <input type="checkbox"/> 4 Type II C  | <input type="checkbox"/> 4 Type III B |
| <input type="checkbox"/> 5 Type III A | <input type="checkbox"/> 5 Type III C |
| <input type="checkbox"/> 6 Type III B | <input type="checkbox"/> 6 Type III D |

### PROTESE NAVN / DESIGN / "COATING"

(spesifiser nøyaktig eller bruk klistrelapp på baksiden)

#### Acetabulum

- Navn/Type .....
- ev. katalognummer .....
- Med hydroksylapatitt     Uten hydroksylapatitt
- 1 Sement med antibiotika – Navn .....
- 2 Sement uten antibiotika – Navn .....
- 3 Usementert

#### Femur

- Navn/Type .....
- ev. katalognummer .....
- Med hydroksylapatitt     Uten hydroksylapatitt
- 1 Sement med antibiotika – Navn .....
- 2 Sement uten antibiotika – Navn .....
- 3 Usementert

#### Caput

- 1 Fastsittende caput
- 2 Separat caput - Navn/Type .....
- ev. katalognummer .....
- Diameter .....

MINI INVASIV KIRURGI (MIS)       0 Nei     1 Ja

COMPUTERNAVIGERING (CAOS)     0 Nei     1 Ja

Type navigering .....

### TROMBOSEPROFYLAKSE

- 0 Nei     1 Ja, hvilken type.....
- Dosering opr.dag..... Første dose gitt preopr  0 Nei     1 Ja
- Senere dosering..... Antatt varighet.....døgn
- Ev. i kombinasjon med .....
- Dosering..... Antatt varighet.....døgn
- Strømpe     0 Nei     1 Legg     2 Legg + Lår    Antatt varighet.....døgn
- Mekanisk pumpe  0 Nei     1 Fot     2 Legg    Antatt varighet.....døgn

### SYSTEMISK ANTIBIOTIKAPROFYLAKSE

- 0 Nei     1 Ja, hvilken (A).....
- Dose (A)..... Totalt antall doser..... Varighet.....timer
- Ev. i kombinasjon med (B).....
- Dose (B)..... Totalt antall doser..... Varighet.....timer

### OPERASJONSSTUE

- 1 "Green house"
- 2 Operasjonsstue med laminær luftstrøm
- 3 Vanlig operasjonsstue

OPERASJONSTID (hud til hud) .....

### PEROPERATIV KOMPLIKASJON

- 0 Nei
- 1 Ja, hvilke(n) .....

### ASA KLASSE (se baksiden for definisjon)

- 1 Frisk
- 2 Asymptomatisk tilstand som gir økt risiko
- 3 Symptomatisk sykdom
- 4 Livstruende sykdom
- 5 Moribund

Lege .....

Legen som har fylt ut skjemaet (navnet registreres ikke i databasen).



**Appendix 2 – English and Norwegian Harris Hip Score**

## Harris Hip Score

I. Pain (44 points possible)			
A. None or ignores it	44	B. Activities (14 points possible)	
B. Slight, occasional, no compromise in activities	40	1. Stairs	
C. Mild pain, no effect on average activities, rarely moderate pain with unusual activity, may take aspirin	30	a. Normally without using a railing	4
D. Moderate pain, tolerable but makes concessions to pain. Some limitation of ordinary activity or work. May require occasional pain medicine stronger than aspirin	20	b. Normally using a railing	2
E. Marked pain, serious limitation of activities	10	c. In any manner	1
F. Totally disabled, crippled, pain in bed, bedridden	0	d. Unable to do stairs	0
II. Function (47 possible)		2. Shoes and Socks	
A. Gait (33 points possible)		a. With ease	4
1. Limp		b. With difficulty	2
a. None	11	c. Unable	0
b. Slight	8	3. Sitting	
c. Moderate	5	a. Comfortably in ordinary chair for 1 h	5
d. Severe	0	b. On a high chair for 0.5 h	3
2. Support		c. Unable to sit comfortably in any chair	0
a. None	11	4. Enter public transportation	1
b. Cane for long walks	7		
c. Cane most of the time	5	III. Range of motion and absence of deformity (9 points possible)	
d. One crutch	3	A. Flexion	
e. Two canes	2	0° to >90°	3
f. Two crutches	0	0–90°	2
g. Not able to walk (specify reason)	0	0° to <90°	1
3. Distance walked		0°	0
a. Unlimited	11	B. Abduction	
b. Six blocks	8	>20°	2
c. Two or three blocks	5	<20°	1
d. Indoors only	2	0°	0
e. Bed and chair	0	C. Deformity	
		None	4
		>30° fixed flexion contracture	0
		>10° fixed adduction	0
		>10° fixed internal rotation in extension	0
		Limb-length discrepancy >3 centimetres	0

With permission – from Frihagen et al. Outcome after femoral neck fractures: a comparison of Harris Hip Score, Eq-5d and Barthel Index. Injury. 2008 Oct;39(10):1147-56.

# Harris Hip Score

<b>SMERTE</b>		Poeng	<b>GANGFUNKSJON</b>		Poeng
Ingen		44	Halting	Ingen	11
Svak	Lett verking/smerter uten innvirkning på funksjon	40		Lett	8
				Middels	5
				Svær	0
Lett	Noe vondt etter mye aktivitet, behov for reseptfri smertestillende	30	Støtte	Ingen	11
				En stokk lengre tur	7
				En stokk vanligvis	5
				En krykke	3
Moderat	Tolerabel, men pasienten plages jevnlig. Kan hemme vanlig aktivitet, kan trenge sterkere smertestillende enn paracet	20		To stokker eller rullator	2
				To krykker	0
				Umulig å gå	0
Sterk	Sterke smerter, men oppgående, hemmer aktivitet betydelig, behov for smertestillende sterkere enn paracet, noe nattsmerter	10	Gangdistanse	Ubegrenset	11
				1-1,5 km	8
				<1 km	5
				Kun inne	2
				Seng til stol	0
Invalidiserende	Betydelig nattsmerter, klarer knapt gå pga av smerte	0	<b>LEDDUTSLAG</b>		
			Fleksjon	0->90°	3
				0-90°	2
				0-<90°	1
				>0°	0
			Abduksjon	>20°	2
				<20°	1
				0	0
<b>FUNKSJON</b>			<b>DEFORMITET</b>		
Trappegang	Normal	4	Ingen		4
	Normal, støtte til rekkverk	2		Fleksjons kontraktur over 30°	0
	Ett trinn av gangen ved hjelp av rekkverk	1		Adduksjons kontraktur over 10°	0
	Umulig	0		Innrotasjon over 10°	0
Transport	Kan bruke kollektiv	1		Anisomeli over 3 cm	0
Sitting	Komfortabel i lav stol>1 time	5	<b>Total sum</b>		
	Komfortabel i høy stol halv time	3			
	Ikke komfortabel i noen stol	0			
Påklledning	Ingen problemer med sokker/sko	4			
	Problemer med sko/sokker	2			
	Umulig å ta på sko/sokker	0			



**Appendix 3 – English and Norwegian Barthel Index**

## Barthel Index of Activities of Daily Living

**Instructions:** Choose the scoring point for the statement that most closely corresponds to the patient's current level of ability for each of the following 10 items. Record actual, not potential, functioning. Information can be obtained from the patient's self-report, from a separate party who is familiar with the patient's abilities (such as a relative), or from observation. Refer to the Guidelines section on the following page for detailed information on scoring and interpretation.

### The Barthel Index

#### Bowels

- 0 = incontinent (or needs to be given enemata)
- 1 = occasional accident (once/week)
- 2 = continent

Patient's Score: \_\_\_\_\_

#### Bladder

- 0 = incontinent, or catheterized and unable to manage
- 1 = occasional accident (max. once per 24 hours)
- 2 = continent (for over 7 days)

Patient's Score: \_\_\_\_\_

#### Grooming

- 0 = needs help with personal care
- 1 = independent face/hair/teeth/shaving (implements provided)

Patient's Score: \_\_\_\_\_

#### Toilet use

- 0 = dependent
- 1 = needs some help, but can do something alone
- 2 = independent (on and off, dressing, wiping)

Patient's Score: \_\_\_\_\_

#### Feeding

- 0 = unable
- 1 = needs help cutting, spreading butter, etc.
- 2 = independent (food provided within reach)

Patient's Score: \_\_\_\_\_

#### Transfer

- 0 = unable – no sitting balance
- 1 = major help (one or two people, physical), can sit
- 2 = minor help (verbal or physical)
- 3 = independent

Patient's Score: \_\_\_\_\_

#### Mobility

- 0 = immobile
- 1 = wheelchair independent, including corners, etc.
- 2 = walks with help of one person (verbal or physical)
- 3 = independent (but may use any aid, e.g., stick)

Patient's Score: \_\_\_\_\_

#### Dressing

- 0 = dependent
- 1 = needs help, but can do about half unaided
- 2 = independent (including buttons, zips, laces, etc.)

Patient's Score: \_\_\_\_\_

#### Stairs

- 0 = unable
- 1 = needs help (verbal, physical, carrying aid)
- 2 = independent up and down

Patient's Score: \_\_\_\_\_

#### Bathing

- 0 = dependent
- 1 = independent (or in shower)

Patient's Score: \_\_\_\_\_

**Total Score:** \_\_\_\_\_



# Barthel ADL-index

(Mahony and Barthel, 1965)

Til norsk ved Knut Laake

Pasientens navn: \_\_\_\_\_  
Fødselsår/dato: \_\_\_\_\_  
Utfylt av: \_\_\_\_\_

J.nr.: \_\_\_\_\_  
Dato utfylt: \_\_\_\_\_  
Stilling: \_\_\_\_\_

## 1. Kontinens for avføring

- 2 Kontinent siste uke.
- 1 Inkontinens ukentlig eller sjeldnere.
- 0 Større grad av inkontinens/trenger klyster for å være kontinent.

## 2. Kontinens for urin

- 2 Kontinent siste uke, mestrer bruk av kateter på egen hånd.
- 1 Inkontinens ikke oftere enn en gang daglig eller bruker kateter og trenger hjelp med dette.
- 0 Større grad av inkontinens.

## 3. Fødeinntak (maten plassert innen rekkevidde)

- 2 Kan skjære opp maten, ha på smør og pålegg uten hjelp, spiser innen rimelig tid.
- 1 Trenger noe hjelp med dette.
- 0 Må mates.

## 4. Personlig hygiene

- 1 Kan vaske ansikt, kjemme håret, barbere seg, pusse tenner (forutsatt at nødvendig utstyr er tilgjengelig).
- 0 Trenger hjelp/påminning til dette.

## 5. Påkledning

- 2 Kan kle seg på egen hånd, inklusive kneppe knapper og ordne glidelåser.
- 1 Trenger noe hjelp, men klarer mer enn halvparten.
- 0 Trenger mer hjelp.

## 6. Forflytning mellom seng og stol

- 3 Klarer seg uten hjelp.
- 2 Trenger litt hjelp/tilsyn, klarer seg fint med noe hjelp av en.
- 1 Trenger mye hjelp av en eller to personer, men kan sitte uten hjelp/tilsyn.
- 0 Kan ikke sitte, må løftes.

## 7. Hjelpetbehov ved bruk av toalett/dostol

- 2 Kan bruke toalett/dostol på egen hånd, mestrer av-/påkledning, tørker seg selv.
- 1 Trenger noe hjelp, men klarer mer enn halvparten.
- 0 Trenger mye hjelp.

## 8. Mobilitet innendørs

- 3 Kan gå alene, evt. med hjelpemidler, men ikke rullestol.
- 2 Trenger hjelp/tilsyn av en person, hjelp til å reise seg.
- 1 Uavhengig i rullestol (også vedr. snuing, passere dører o.l.).
- 0 Trenger mer hjelp enn dette.

## 9. Trappegang

- 2 Selvhjulpen opp og ned trapp, kan bære nødvendige hjelpemidler (stokk, krykke).
- 1 Trenger hjelp, evt. til å bære hjelpemiddel.
- 0 Kan ikke.

## 10. Bading

- 1 Selvhjulpen ved bading/dusjing (evt. med hjelpemidler).
- 0 Trenger hjelp.



**Appendix 4 – English and Norwegian EQ-5D**

**EQ-5D (UK English version)**

By placing a tick in one box in each group below, please indicate which statements best describe your own health state today.

**Mobility**

- I have no problems in walking about
- I have some problems in walking about
- I am confined to bed

**Self-Care**

- I have no problems with self-care
- I have some problems washing or dressing myself
- I am unable to wash or dress myself

**Usual Activities** (*e.g. work, study, housework, family or leisure activities*)

- I have no problems with performing my usual activities
- I have some problems with performing my usual activities
- I am unable to perform my usual activities

**Pain/Discomfort**

- I have no pain or discomfort
- I have moderate pain or discomfort
- I have extreme pain or discomfort

**Anxiety/Depression**

- I am not anxious or depressed
- I am moderately anxious or depressed
- I am extremely anxious or depressed

To help people say how good or bad a health state is, we have drawn a scale (rather like a thermometer) on which the best state you can imagine is marked 100 and the worst state you can imagine is marked 0.

We would like you to indicate on this scale how good or bad your own health is today, in your opinion. Please do this by drawing a line from the box below to whichever point on the scale indicates how good or bad your health state is today.

**Your own  
health state  
today**

Best  
imaginable  
health state

100

90

80

70

60

50

40

30

20

10

0

Worst  
imaginable  
health state

Vis hvilke utsagn som passer best på din helsetilstand i dag ved å sette et kryss i en av rutene utenfor hver av gruppene nedenfor.

### **Gange**

Jeg har ingen problemer med å gå omkring.

Jeg har litt problemer med å gå omkring.

Jeg er sengeliggende.

### **Personlig stell**

Jeg har ingen problemer med personlig stell.

Jeg har litt problemer med å vaske meg eller kle meg.

Jeg er ute av stand til å vaske meg eller kle meg.

### **Vanlige gjøremål** (f.eks. arbeid, studier, husarbeid, familie- eller fritidsaktiviteter).

Jeg har ingen problemer med å utføre mine vanlige gjøremål

Jeg har litt problemer med å utføre mine vanlige gjøremål.

Jeg er ute av stand til å utføre mine vanlige gjøremål.

### **Smerte/ubehag**

Jeg har verken smerte eller ubehag.

Jeg har moderat smerte eller ubehag.

Jeg har sterk smerte eller ubehag.

### **Angst/depresjon**

Jeg er verken engstelig eller deprimert.

Jeg er noe engstelig eller deprimert.

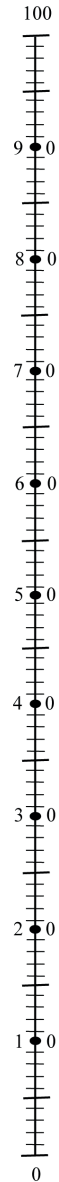
Jeg er svært engstelig eller deprimert.

Best tenkelige  
helsetilstand

For å hjelpe folk til å si hvor god eller dårlig en helsetilstand er, har vi laget en skala (omtrent som et termometer) hvor den beste tilstanden du kan tenke deg er merket 100 og den verste tilstanden du kan tenke deg er merket 0.

Vi vil gjerne at du viser på denne skalaen hvor god eller dårlig helsetilstanden din er i dag, etter din oppfatning. Vær vennlig å gjøre dette ved å trekke en linje fra boksen nedenfor til det punktet på skalaen som viser hvor god eller dårlig din helsetilstand er i dag.

**Din egen  
helsetilstand  
i dag**



Verst tenkelige  
helsetilstand





**Appendix 5 – Paper 1-4**





This article is removed.







This article is removed.









This article is removed.





This article is removed.





